

CASE AND RESEARCH LETTER

[Translated article] Rosacea Fulminans in Pregnancy



Rosácea fulminans durante el embarazo

To the Editor:

Rosacea fulminans is a severe skin disease of the face that is characterized by the sudden onset of papules, pustules, and nodules. Pregnancy is considered a potential trigger. Serious complications can develop in pregnant women if the disease is not diagnosed and treated early. We report a new case of rosacea fulminans in a pregnant woman and analyze the epidemiologic and therapeutic characteristics and severe complications reported in this group of patients.

An otherwise healthy 20-year-old woman who was 14 weeks pregnant came to the clinic with an extensive outbreak of pustules on an erythematous–edematous base, with no comedones. The lesions were located on the cheeks and forehead (Fig. 1) and accompanied by low-grade fever. No acneiform lesions were observed at other sites. The patient denied having taken new medication and recent exposure to sunlight. Bacterial culture of the pustules was negative, and no significant laboratory abnormalities were recorded.

Histology (Fig. 2) revealed reactive epidermal hyperplasia, with a collection of intracorneal neutrophils and infundibular dilatation of the hair follicle. The dermis was remarkable for the presence of vascular ectasia and a lymphohistiocytic infiltrate. An abundance of *Demodex folliculorum* was also observed. Together with the symptoms, these findings were compatible with rosacea fulminans. The patient was given erythromycin 500 mg/8 h for 3 weeks in combination with topical metronidazole and hydrocortisone. Topical metronidazole was subsequently maintained for 3 months, leading to almost complete resolution of the lesions.

To date, we have identified 21 cases of rosacea fulminans during pregnancy (Table 1).^{1–13} The median age was 31 years (range, 20–38 years), and most patients were diagnosed during the first trimester (43%) owing to the appearance of lesions a few weeks earlier. In 32% of cases,

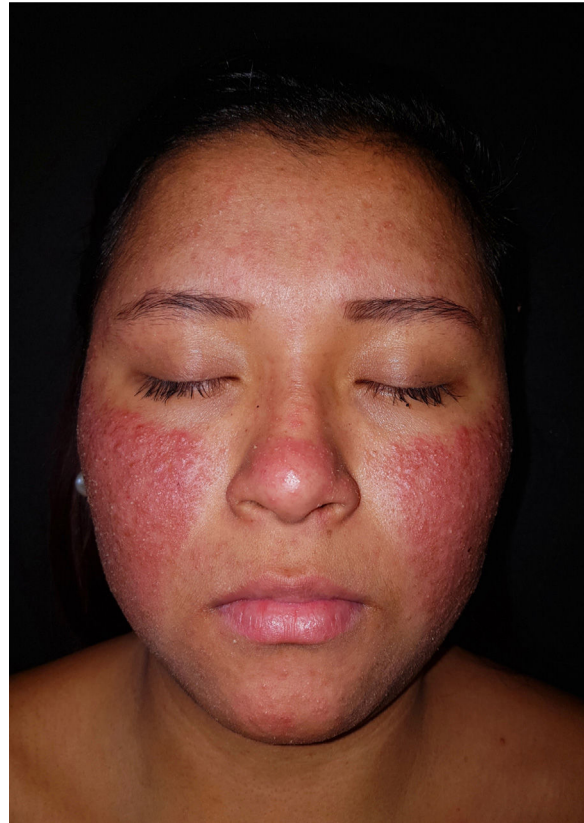

Figure 1 Extensive pustules over an erythematous base mainly affecting the cheeks and forehead.

the patient reported a history of rosacea before becoming pregnant. Oral antibiotics were the most widely prescribed option (95%), with macrolides being the first choice in 68% of patients. Almost one-third of patients (32%) also received systemic corticosteroids that were subsequently tapered, and 18% required isotretinoin after labor owing to lack of response to their previous treatment. Topical treatment was administered in 68% of cases, mainly with metronidazole, clindamycin, and erythromycin. The severe complications reported include a case of fetal demise owing to the adverse effects of corticosteroids (secondary adrenal insufficiency),⁵ induced abortion owing to major anxiety-depression syndrome,⁸ and a case of bilateral corneal

DOI of original article:

<https://doi.org/10.1016/j.ad.2020.04.014>

<https://doi.org/10.1016/j.ad.2020.04.024>

0001-7310/© 2021 AEDV. Published by Elsevier España, S.L.U. This is an open access article under the CC BY-NC-ND license (<http://creativecommons.org/licenses/by-nc-nd/4.0/>).

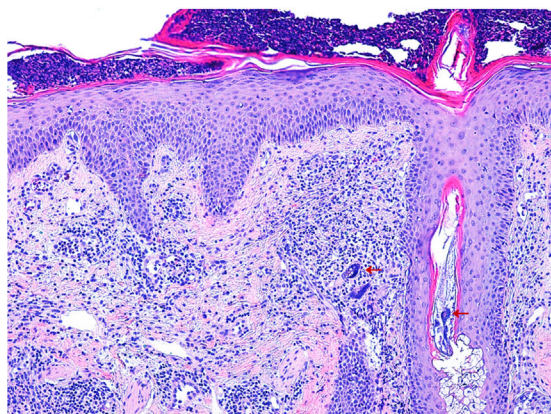


Figure 2 Reactive epidermal hyperplasia with collection of intracorneal neutrophils. The dermis is remarkable for the presence of a lymphohistiocytic infiltrate and vascular ectasia, together with figures suggestive of *Demodex folliculorum* (arrows) (hematoxylin–eosin, ×20).

perforation requiring a corneal transplant.⁹ There are no reports of recurrence in subsequent pregnancies.

Rosacea fulminans is a severe facial dermatosis of uncertain origin. Hormonal changes during pregnancy could be a trigger. Very extended lesions have been reported in pregnant women, as have profound and irreversible eye involvement⁹ and a psychiatric condition triggered by the onset of lesions.⁸ Given the degree of involvement of rosacea fulminans, systemic treatment is often necessary. However, commonly used drugs, such as retinoids and tetracyclines, are contraindicated during pregnancy. Therefore, oral macrolides such as erythromycin and azithromycin are the safest and most effective option in this situation. More evidence is available for erythromycin, although findings for the effectiveness of azithromycin in rosacea are favorable, showing a more comfortable dosing regimen and fewer adverse effects.¹⁰ Topical antibiotics should also be added owing to their anti-inflammatory effects. Systemic corticosteroids may prove to be necessary, although they can cause delayed intrauterine growth, gestational diabetes,

Table 1 Epidemiologic and Therapeutic Characteristics and Complications in Cases of Rosacea Fulminans During Pregnancy.

Case	Age	Onset	When diagnosed	Previous rosacea	Treatment	Course/complications	Reference
1–5	NA	NA	Third trimester or postpartum	NA	Oral and topical antibiotics ^a	NA	Massa and Su (1982)
6	25	Sudden	Second trimester (16 wk)	Yes	Intralesional triamcinolone, oral erythromycin 250 mg/6 h, drainage, topical hydrocortisone, followed by prednisone 60 mg/d. ^b After delivery, isotretinoin 40 mg/12 h for 20 wk	No improvement until end of pregnancy and initiation of retinoids	Marks and Briggaman (1987)
7	23	4 wk	First trimester	Yes	Topical clindamycin and erythromycin ^a	NA	Plewig et al. (1992)
8	33	2 mo	Third trimester	Yes	Topical clindamycin and erythromycin ^a	NA	Plewig et al. (1992)
9	25	2 mo	First trimester	Yes	Topical clindamycin and erythromycin ^a	NA	Plewig et al. (1992)
10	26	6 wk	Postpartum	No	Topical clindamycin and erythromycin ^a	NA	Plewig et al. (1992)
11	35	NA	NA	Yes	NA	Was taking methotrexate at onset of rosacea fulminans. Presented with an outbreak on becoming pregnant	Haugstved and Bjerke (1998)
12	28	Postpartum	First trimester (12 wk)	Yes	Erythromycin 500 mg/8 h and prednisolone 35 mg/d with subsequent maintenance at 20 mg	Gestational diabetes, probably associated with corticosteroids, placental insufficiency, and fetal demise (secondary adrenal insufficiency)	Lewis et al. (2004) and detailed in Jarrett et al. (2010)

Table 1 (Continued)

Case	Age	Onset	When diagnosed	Previous rosacea	Treatment	Course/complications	Reference
13	31	3 wk	First trimester (8 wk)	Yes	Methylprednisolone 40 mg/d, ^b fusidic acid, drainage (first trimester) and topical metronidazole 0.75% (second trimester)	Good response	Ferahbas et al. (2006)
14	32	ND	First trimester (3 wk)	No	Oral and topical macrolide, oral amoxicillin, topical metronidazole. Isotretinoin 0.5 mg/kg/d started 3 mo after delivery	Pregnancy via IVF and hormonal stimulation. No improvement until end of pregnancy and initiation of retinoids	Cisse et al. (2008)
15	35	4 wk	First trimester	No	Prednisolone 30 mg/d, erythromycin 2 g/d. After termination, isotretinoin 40 mg/d	Termination at 12 wk in the context of anxiety–depressive syndrome caused by the lesions. Lesions resolved with initiation of isotretinoin	Jarrett et al. (2010)
16	31	2 mo	First trimester (8 wk)	No	Erythromycin 2 g/d. After delivery, prednisone 20 mg/d and isotretinoin 40 mg/d	Partial improvement. Resolution after isotretinoin plus prednisone in postpartum	Jarrett et al. (2010)
17	26	5 mo	Second trimester (21 wk)	NA	Erythromycin 2 g/d and prednisolone 40 mg/d	Blepharitis and keratitis with severe bilateral corneal perforation. Need for corneal transplant	De Morais e Silva et al. (2011)
18	33	3 wk	First trimester (11 wk)	No	Azithromycin 500 mg/d on 3 d/wk for 1 mo with gradual tapering up to 12 wk (250 mg/d, 3 d/wk for 1 mo, then 500 mg/wk for 1 mo) and topical metronidazole	Rapid response	Fuentelsaz et al. (2011)
19	38	Sudden	Second trimester (14 wk)	No	Erythromycin 500 mg twice daily	Complete resolution after a few mo	Haenen et al. (2015)
20	37	NA	Third trimester (37 wk)	No	Azithromycin and prednisone ^a	Complete resolution after delivery	Markou et al. (2017)
21	22	4 wk	First trimester (6 wk)	NA	Amoxicillin-clavulanic acid 1 g/d × 10 d, moist compresses, topical fusidic acid for 1 mo	Resolution 1 mo after completing treatment	Demir et al. (2018)
Present case	20	2 wk	Second trimester (14 wk)	No	Erythromycin 500 mg/8 h for 3 wk and hydrocortisone and topical metronidazole for 3 mo	Rapid response. Complete resolution at 3 mo	

Abbreviations: IVF, in vitro fertilization; NA, not available.

^a Dosage not specified.

^b Tapering regimen.

and hypertension, as well as secondary adrenal insufficiency, which can lead to fetal demise.^{5,8}

Considering the cases reviewed, we propose the following therapeutic approach: first-line therapy with oral macrolides combined with topical clindamycin or metronidazole, and second-line therapy with addition of topical and systemic corticosteroids (doses up to 0.5 mg/kg/d).

In conclusion, rosacea fulminans is a severe skin disease that can develop during pregnancy. Affected patients should be diagnosed early to avoid progression to extended lesions. Thus, we can decrease the possibility of potentially severe complications by reducing the need for treatment with systemic corticosteroids.

Conflicts of interest

The authors declare that they have no conflicts of interest.

References

1. Massa MC, Su WPD. Pyoderma faciale: a clinical study of twenty-nine patients. *J Am Acad Dermatol.* 1982;6:84–91.
2. Marks VJ, Briggaman RA. Pyoderma faciale: successful treatment with isotretinoin. *J Am Acad Dermatol.* 1987;17:1062–3.
3. Plewig G, Jansen T, Kligman AM. Pyoderma faciale. A review and report of 20 additional cases: Is it rosacea? *Arch Dermatol.* 1992;128:1611–7.
4. Haugstvedt A, Bjerke JR. Rosacea fulminans with extrafacial lesions. *Acta Derm Venereol.* 1998;78:70–1.
5. Lewis V, Holme S, Wright A, Anstey A. Rosacea fulminans in pregnancy. *Br J Dermatol.* 2004;151:917–9.
6. Ferahbas A, Utas S, Mistik S, Uksal U, Peker D. Rosacea fulminans in pregnancy: case report and review of the literature. *Am J Clin Dermatol.* 2006;7:141–4.
7. Cisse M, Maruani A, Bré C, Domart P, Jonville-Bera A, Machet L. Rosacée fulminante au début d'une grossesse par fécondation in vitro et transfert d'embryons (FIVETE). *Ann Dermatol Venereol.* 2008;135:675–8.
8. Jarrett R, Gonsalves R, Anstey A. Differing obstetric outcomes of rosacea fulminans in pregnancy: report of three cases with review of pathogenesis and management. *Clin Exp Dermatol.* 2010;35:888–91.
9. De Morais e Silva FA, Bonassi M, Steiner D, da Cunha TV. Rosacea fulminans in pregnancy with ocular perforation. *J Dtsch Dermatol Ges.* 2011;9:542–3.
10. Fuentelsaz V, Ara M, Corredera C, Lezcano V, Juberias P, Carapeto F. Rosacea fulminans in pregnancy: successful treatment with azithromycin. *Clin Exp Dermatol.* 2011;36:674–6.
11. Haenen CCP, Kouwenhoven STP, van Doorn R. Rosacea fulminans in pregnancy. *Ned Tijdschr Geneesk.* 2015;159:A8334.
12. Markou AG, Alessandrini V, Muray JM, Begon E, Fysekidis M. Rosacea fulminans during pregnancy. *Clin Exp Obstet Gynecol.* 2017;44:157–9.
13. Demir O, Tas IS, Gunay B, Ugurlucan FG. A rare dermatologic disease in pregnancy: Rosacea fulminans – case report and review of the literature. *Open Access Maced J Med Sci.* 2018;6:1438–41.

A. Altemir-Vidal^{a,*}, M. Iglesias-Sancho^a, N. Pérez-Muñoz^b, M. Salleras-Redonnet^a

^a *Servicio de Dermatología, Hospital Univversitari Sagrat Cor- Grupo Quirónsalud, Barcelona, Spain*

^b *Servicio de Anatomía Patológica, Hospital Univversitari Sagrat Cor-Grupo Quirónsalud, Barcelona, Spain*

* Corresponding author.

E-mail address: arcadi.altemir@gmail.com (A. Altemir-Vidal).