

CASE AND RESEARCH LETTER

[Translated article] New Technologies Applied to the Study of Skin Hypopigmentation



Nuevas tecnologías aplicadas al estudio de hipopigmentaciones cutáneas

To the Editor:

Conventional Wood's lamps emit light at between 320 and 400 nm, with a peak at 365 nm.¹ When this radiation is projected on hypopigmented skin, the lack of melanin facilitates visualization of the autofluorescence of the dermal collagen, and the lesions take on a bluish-white color.² Melanin absorbs light at 365 nm more intensely, improving the contrast between the hypopigmented lesion and the healthy skin.^{1,3}

Although Wood's lamps constitute a basic additional examination technique in the study of skin hypopigmentation, their availability in the dermatology consultation is not always assured. We present 2 examples of skin hypopigmentation, in which 3 different devices were used with the objective of comparing their effectiveness in demarcating this type of dermatologic lesion.

First, we used the Wood's lamp as a control examination (Quirumed 197-B601 Wood Lamp). Second, we used a pocket torch with an LED emitting UVA light at a wavelength of 365 nm (TATTU U15), a technique that Bae and Lee¹ called narrow-band Wood's lamp. The third device used was the blue light emitted by the screen of a smartphone (iPhone 6 plus, 5.5-inch IPS LED screen; maximum brightness, 500 cd/m² and peak blue-light emission at 448 nm). To select the blue color emitted by the cellphone, following the methodology proposed by Agrawal et al.,² we downloaded a blue image from the Internet and saved it to the image gallery to reproduce it later (using the spectrometry app, Blue Light Spectrum Analyzer; for our study, the image used presented a blue-light peak at 435 nm). Finally, the screen setup was changed to increase the brightness to the maximum level. In a completely dark room, we choose the full-screen blue image from the gallery and shone the

light on the area with the abnormal pigmentation. The distance between the light source and the lesion was 50 cm for all devices. To take photographs, we used the cellphone camera of the iPhone 11 Pro, placed beside the light source, perpendicular to the lesion, using an exposure time of 3 s and an optical zoom of 1×.

Patient 1 is a 40-year-old woman who presented a hypopigmented linear macule on the back of the right foot, with poorly defined edges, which had appeared 9 months earlier following local injections of corticosteroids (Fig. 1). Patient 2 is a 28-year-old woman with progressive macular hypomelanosis that presented poorly defined nondesquamative hypopigmented macules with a tendency to coalesce in the lumbar region and on the abdomen (Fig. 2).

When the 3 techniques were compared, the LED torch emitting light at 365 nm showed greater demarcation of the lesions, without the blue tone seen with the other devices. When the blue light from the cellphone was used, a certain improvement was observed in the demarcation of the lesions, but excess brightness made demarcation difficult in both cases (Table 1).

The use of blue light from mobile devices has been previously reported as an alternative to a Wood's lamp for the examination of vitiligo.^{2,4} In recent studies, the effectiveness of 365-nm LED lamps has been compared to that of conventional Wood's lamps for the study of vitiligo, pityriasis alba, and achromic nevus.¹ In our study, we present for the first time a comparative analysis of different alternatives to Wood's light for the study of the same hypopigmented lesions and find that the 365-nm LED torch provides greater effectiveness in defining the lesions.

Given that the 2 alternatives examined in this study present emission peaks close to those emitted by conventional Wood's lamps, both are devices that may be of interest for the study of skin hypopigmentation. The 365-nm LED torches represent an effective, reproducible, and economic alternative to Wood's lamps for the study of skin hypopigmentation. The high availability of smartphones in our consulting rooms makes this second technique a potential alternative to be borne in mind in the future. To make examinations using blue light emitted by the screens of different smartphones reproducible, it will be necessary to establish the wavelength and brightness to be emitted. Joint study by software developers and dermatologists will be essential to designing applications that make it possible to standardize these parameters and

DOI of original article:

<https://doi.org/10.1016/j.ad.2020.08.020>

<https://doi.org/10.1016/j.ad.2022.05.004>

0001-7310/© 2021 AEDV. Published by Elsevier España, S.L.U. This is an open access article under the CC BY-NC-ND license (<http://creativecommons.org/licenses/by-nc-nd/4.0/>).

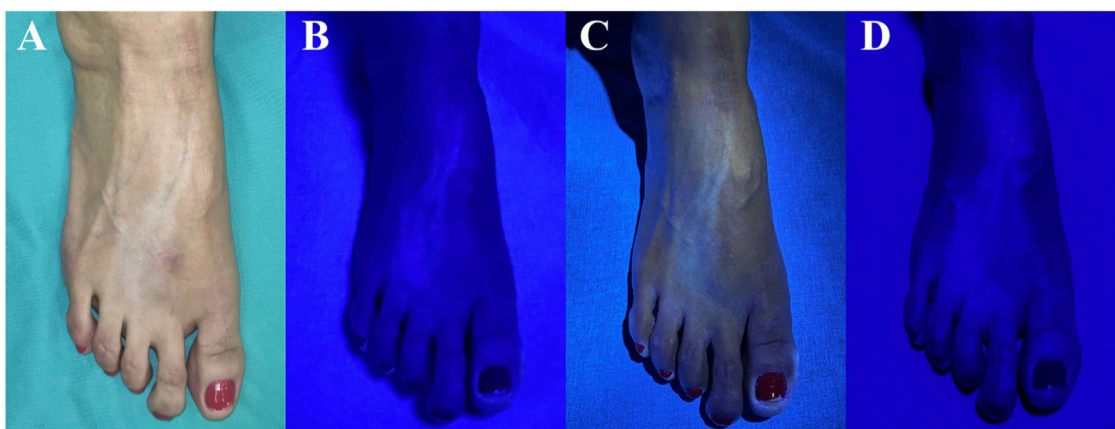


Figure 1 Linear cutaneous hypopigmentation following local injection of corticosteroids in patient 1. A) Clinical presentation of the lesions under ambient lighting. B) Blue coloring of the lesions using the conventional Wood’s lamp. C) Bluish-white coloration of the lesions using the 365-nm LED torch, with optimum demarcation of the lesions. D) Blue coloring of the lesions using the light emitted by the smartphone, with suboptimal demarcation of the lesions due to excess brightness.

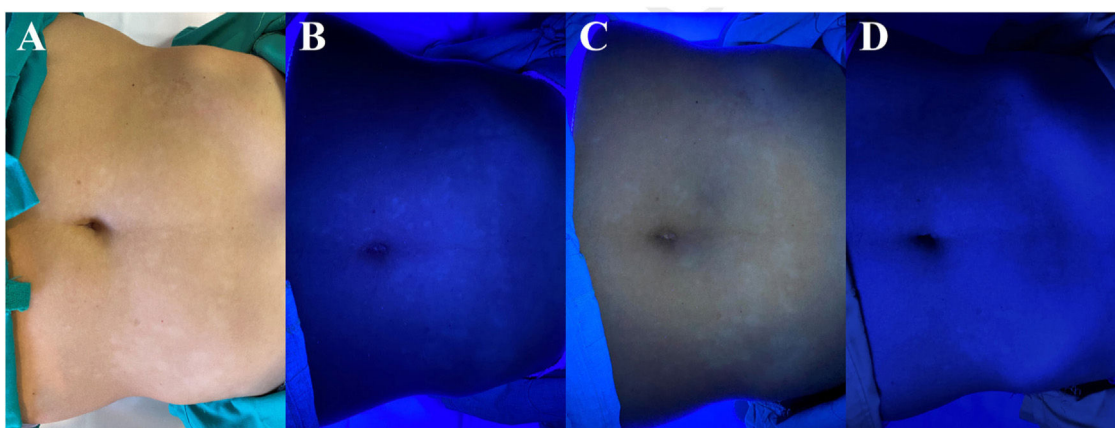


Figure 2 Progressive and coalescing macular hypomelanosis in patient 2. A) Clinical presentation of the lesions under ambient lighting. B) Blue coloring of the lesions using the conventional Wood’s lamp. C) Bluish-white coloration of the lesions using the 365-nm LED torch, with optimum demarcation of the lesions. D) Blue coloring of the lesions using the light emitted by the smartphone, with suboptimal demarcation of the lesions due to excess brightness.

Table 1 Differential Characteristics of the Additional Examinations Proposed for the Study of Skin Hypopigmentation.

	Wood’s lamp	LED torch	Blue smartphone screen
Emission spectrum	320–400 nm (peak at 365 nm)	365 nm	410–780 nm (peak at 448 nm)
Coloration of lesions	Blue	Bluish white	Blue
Demarcation of lesions	++	+++	+
Size of device	Large	Small	Medium
Availability in consulting rooms	++	+	+++
Average price of device	€50–€100	<€50	>€100
Reproducibility	High	High	Low

facilitate the reproducibility of the technique using blue light emitted by the screens of different smartphones in our consultations.

Conflicts of Interest

The authors declare that they have no conflicts of interest.

References

1. Bae JM, Lee RW. 365-nm narrowband Wood’s lamp for vitiligo and hypopigmentation disorders. *J Am Acad Dermatol.* 2019, <http://dx.doi.org/10.1016/j.jaad.2019.08.064>.
2. Agrawal S, Sharma A, Dhurat R, Chahal K. Using the blue screen of a smartphone as an alternative to Wood’s lamp

- for examination of vitiligo. *J Am Acad Dermatol*. 2019, <http://dx.doi.org/10.1016/j.jaad.2019.04.041>.
3. Klatte JL, van der Beek NK, emperman PM 100 years of Wood's lamp revised. *J Eur Acad Dermatol Venereol*. 2015;29:842–7, <http://dx.doi.org/10.1111/jdv.12860>.
4. García-Gil MF, Monte Serrano J, Ortega Lalmonda I. Exploración del vitiligo bajo pantalla de luz azul de dispositivos móviles como alternativa a la luz de Wood. *Aten Primaria*. 2020, <http://dx.doi.org/10.1016/j.aprim.2020.02.006>.

^a *Servicio de Dermatología y Venerología, Hospital Clínico Universitario Lozano Blesa, Zaragoza, Spain*

^b *Servicio de Dermatología y Venereología, Hospital Universitario Reina Sofía, Murcia, Spain*

* Corresponding author.

E-mail address: monte.serrano.juan@gmail.com
(J. Monte-Serrano).

J. Monte-Serrano^{a,*}, J. Cruaños-Monferrer^b,
M. Ramírez-Lluch^a, M.F. García-Gil^a