

## IMAGES IN DERMATOLOGY

### [Translated article] An Iatrogenic Tattoo

### Un tatuaje iatrogénico



J.P. Serrano Serra<sup>a,\*</sup>, J. Ruiz Martínez<sup>a</sup>, A. Gil Liñán<sup>b</sup>

<sup>a</sup> Servicio Dermatología MQ y Venereología, HGU Reina Sofía, Murcia, Spain

<sup>b</sup> Servicio Anatomía Patológica, HGU Reina Sofía, Murcia, Spain

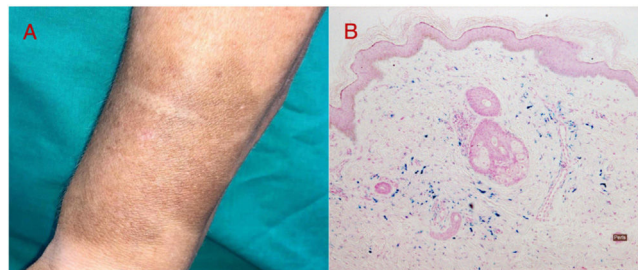


Figure 1

A 66-year-old woman hospitalized for thromboembolic disease was administered an intravenous dose of ferric carboxymaltose in the cephalic vein of the forearm to treat low hemoglobin levels. Some days later, at home, she noticed a hyperpigmented macule (Fig. 1A) near the injection site; no other symptoms were present. After several weeks, she went to the dermatology outpatient clinic for evaluation.

Histologic examination of a punch biopsy specimen obtained from the affected site showed elastosis in the papillary dermis and mild chronic inflammation with interstitial pigmented macrophages (identified as hemosiderophages using the Perls method) throughout the dermis (Fig. 1B).

Integration of clinical and pathologic findings led to a diagnosis of cutaneous siderosis due to extravasation of the intravenous iron compound.

DOI of original article:

<https://doi.org/10.1016/j.ad.2022.05.040>

\* Corresponding author.

E-mail address: [joserranoserra@gmail.com](mailto:joserranoserra@gmail.com) (J.P. Serrano Serra).

<https://doi.org/10.1016/j.ad.2022.05.048>

0001-7310/© 2023 AEDV. Published by Elsevier España, S.L.U. This is an open access article under the CC BY-NC-ND license (<http://creativecommons.org/licenses/by-nc-nd/4.0/>).