

Full English text available at  
[www.actasdermo.org](http://www.actasdermo.org)

## CASE AND RESEARCH LETTER

### Disseminated Cutaneous Lesions in an Immunocompromised Patient: A Diagnostic Challenge

### Lesiones cutáneas diseminadas en una paciente inmunocomprometida: un reto diagnóstico

To the Editor,

Patients with human immunodeficiency virus (HIV) infection and CD4<sup>+</sup> counts <200 cells/ $\mu$ L are more vulnerable to opportunistic infections that can generate challenging presentations with potential misdiagnosis. A systematic approach could prevent errors in complex cases.

A 40-year-old woman from a tropical rainforest region on inpatient care for an acute diarrheal disease was referred to us for a 2-year history of multiple skin lesions that appeared on her lower left limb with subsequent ulceration, followed by similar lesions on the face and upper limbs. She had been diagnosed with HIV 2 years before and had poor adherence to highly active antiretroviral therapy (HAART). Physical examination revealed brown erythematous nodules and plaques with hematic crusts on her face, anterior forearms, and legs (Fig. 1a–c). No mucosal lesions or lymphadenopathies were found. Laboratory tests showed an HIV viral load of 446,816 copies/mL and a CD4<sup>+</sup> count of 152 cells/ $\mu$ L. Chest and abdominal CT scans were normal. Skin biopsy revealed a dermal granulomatous nodular dermatitis suggestive of *Histoplasma* infection due to positive Gomori structures within histiocytes (Fig. 1d). Treatment with liposomal amphotericin B (total dose of 1080 mg) for 8 days followed by itraconazole 200 mg/day for 14 days was given, with clinical improvement.

One month later, the patient returned with increased infiltration of lesions and a negative urinary *Histoplasma* antigen test, thus weakening the initial diagnosis. A second skin biopsy showed granulomatous nodular dermatitis, intracellular organisms consistent with amastigotes, an intense anti-CD68 cytoplasmic positivity (Fig. 1e–g), and a negative Gomori stain. Real-time polymerase chain reaction (PCR) confirmed the presence of *Leishmania*, subgenus *Viannia*.

Further chest and abdominal CT scans were again normal. Cultures and histopathology examination from skin and transbronchial pulmonary biopsies were negative for fungi.

Diffuse cutaneous leishmaniasis (DCL) was diagnosed and liposomal amphotericin B was restarted in view of the previous good response, to complete a total dose of 2200 mg, achieving cutaneous improvement.

At the 3-month follow-up, skin lesions developed a warty appearance, which was deemed a sign of immune reconstitution inflammatory syndrome (IRIS) in view of adequate adherence to HAART, HIV viral load of 110 copies/mL, CD4<sup>+</sup> count of 500 cells/ $\mu$ L, and a skin biopsy negative for amastigotes. Consequently, systemic corticosteroids were prescribed. Subsequently, after her last hospital discharge, the patient was lost to follow-up.

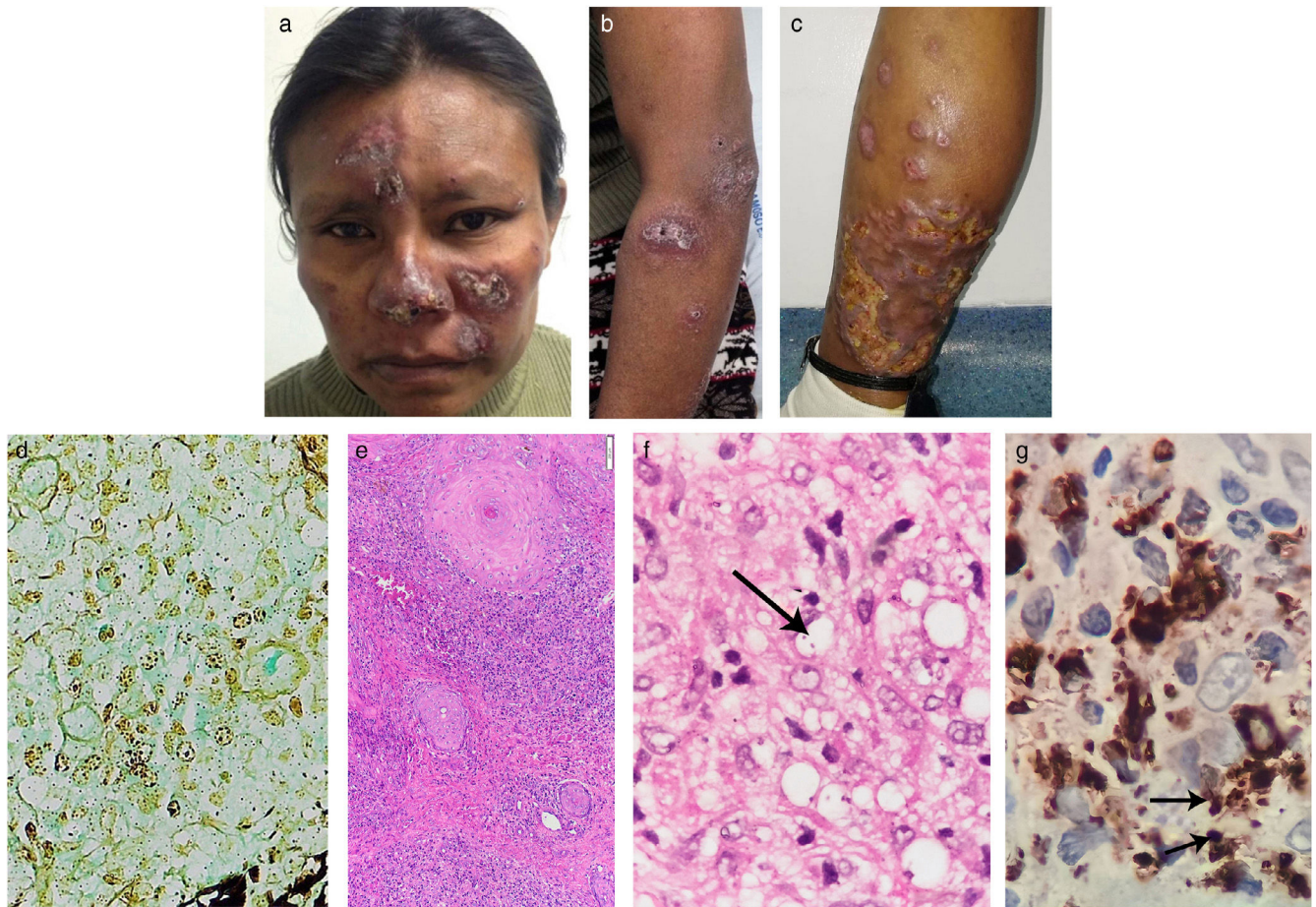
DCL is a rare chronic form of leishmaniasis in which there is a reduced response to *Leishmania* antigens and, therefore, it is observed in those cases with deficient cell-mediated immunity.<sup>1</sup> The clinical picture in HIV-coinfected patients may be severe, with more than 200 lesions, or have a progressive course.<sup>2</sup> In this context, clinical diagnostic difficulties can be seen in which the most important differentials are lepromatous leprosy and disseminated histoplasmosis, among others.<sup>3</sup> Likewise, histopathological results may be inconclusive given the similarity to other entities in which certain findings (e.g. granulomas, parasitized macrophages) could lead to misdiagnosis.<sup>4,5</sup>

In our case, cutaneous lesions were similar to those of histoplasmosis and the positive Gomori structures within histiocytes seen in the first biopsy led to this initial diagnosis. In leishmaniasis, this latter and rare finding could be due to some kind of artifact from the histologic technique where amastigotes nuclei could capture silver nitrate (AgNO<sub>3</sub>) from Gomori stain.<sup>5</sup> Beyond technical error, another possible explanation is the presence of structures resembling Michaelis-Gutmann bodies (MGB), reported in a few cases of cutaneous leishmaniasis.<sup>6,7</sup> MGB, usually found in malakoplakia, are Gomori and Von Kossa positive. In *Leishmania* infection, these structures are Gomori positive but can be Von Kossa negative and have been hypothesized to correspond to bacterial contamination or phagosomes/phagolysosomes transformed by the parasite.<sup>6,7</sup> Electron microscopy is useful to confirm MGB presence, but it was not performed in our case.

<https://doi.org/10.1016/j.ad.2024.03.036>

0001-7310/© 2024 AEDV. Published by Elsevier España, S.L.U. This is an open access article under the CC BY-NC-ND license (<http://creativecommons.org/licenses/by-nc-nd/4.0/>).

Please cite this article as: P.M. Guavita Falla, B. Rodríguez Lechtig, E. Peñaranda Contreras et al., Disseminated Cutaneous Lesions in an Immunocompromised Patient: A Diagnostic Challenge, ACTAS Dermo-Sifiliográficas, <https://doi.org/10.1016/j.ad.2024.03.036>



**Figure 1** Brownish erythematous plaques on the face (A). Violaceous plaques on left forearm and arm (B). Nodules and a large erythematous infiltrated plaque on the posterior lower left leg with areas of ulceration (C). Positive Gomori structures within histiocytes (Gomori staining, 40 $\times$ ). (D) Granulomatous nodular inflammatory process consisting of lymphocytes, histiocytes, and some plasma cells in the upper and deep dermis (H&E staining, 10 $\times$ ). (E) *Leishmania* amastigote, arrow (H&E staining, 600 $\times$ ). (F) Anti-CD68 (clone KP1) immunohistochemistry showing intense cytoplasmic positivity in macrophages. In addition, some amastigotes can be observed, arrows (IHQ, 600 $\times$ ) (G).

Although *Histoplasma* coinfection was plausible in our patient, it was ruled out considering the evidence of (1) a multidisciplinary approach (Dermatology, Internal Medicine, Infectious Diseases, Pneumology, among others) in each hospitalization with relevant complementary studies did not find any pulmonary or cutaneous fungal involvement in serial images, nor in repeated samples for cytology, cultures, biopsies, and antigen detection. (2) The expected clinical picture in our context would have been that of disseminated histoplasmosis (DH), characterized by splenomegaly, hepatomegaly, adenopathy, pancytopenia, and pulmonary disease, in addition to skin lesions.<sup>4,5</sup> None of these extracutaneous signs were seen at the follow-up. We should mention that DH-related skin signs are almost always a feature of disseminated disease in which a pulmonary focus is the initial point of dissemination to the skin.<sup>4</sup>

We propose these strategies to address the above-mentioned diagnostic difficulties: (1) consider the epidemiology since certain entities occur in specific areas; (2) clinical and histological clues specific to each disease allow to narrow down the diagnostic range (Tables 1 and 2)<sup>1-5</sup>; (3)

in situations of complex or overlapping features, in addition to repeated biopsies obtained from different lesions together with examination of multiple serial sections and specific stains, it is necessary to carry out additional diagnostic techniques such as PCR (Table 2).<sup>2,3,8</sup> We also suggest using a combination of methods since some of them could have limited sensitivity<sup>3,8</sup>; (4) remember that in HIV patients, coinfections have the potential for atypical presentations, more than two organisms may coexist, and elevated relapse rates and poor response to conventional therapy have been reported.<sup>2,8</sup>

Regarding the HIV-*Leishmania* interaction, studies from human cell cultures have shown that the upregulation of HIV replication in CD4<sup>+</sup> T cells is driven by the lipophosphoglycan, the major surface protein of *Leishmania*.<sup>9</sup> Furthermore, CD8<sup>+</sup> T cells exhibit a low cytotoxic activity against infected macrophages, with the consequent unrestrained spread of *Leishmania*.<sup>10</sup>

In conclusion, this case illustrates the diagnostic drawbacks that could be found in DCL for which several solutions are suggested to address potential mistakes.

**Table 1** Comparative epidemiological and clinical findings in diffuse cutaneous leishmaniasis (DCL) and its differential diagnoses.

	Cause	Epidemiology (main distribution)	Clinical signs
DCL	<i>L. Mexicana</i> , <i>L. amazonensis</i> , and occasionally <i>L. braziliensis</i> <i>L. aethiopica</i> , seldom by <i>L. major</i>	Central/South America Africa	Multiple erythematous-to-violaceous macules, papules, nodules, and plaques especially on the face, extensor extremities, and buttocks; lesions are painless; diffuse cutaneous infiltration; ulceration not so common; mucosal lesions are possible; nerve involvement does not occur.
Lepromatous leprosy	<i>Mycobacterium leprae</i> <i>Mycobacterium lepromatosis</i>	America, Africa, Asia America, Asia	Multiple bilateral ill-marked papules, plaques, and nodules on the face ear lobes, extremities, and trunk; symmetric distribution; sometimes diffuse thickening; sensory loss in some lesions; nodules can ulcerate.
Disseminated histoplasmosis	<i>Histoplasma capsulatum</i>	Worldwide	Variable clinical presentation: molluscum contagiosum-like papules in most cases; nodules which converge to form warty lesions; plaques, pustules, abscesses, ulcers, cellulitis, purpuric lesions and panniculitis. The lung is the most common initial focus of infection.
DCS	<i>Sporothrix schenckii</i>	Worldwide	There are $\geq 3$ lesions involving two anatomical sites; papules, pustules, plaques, ulcers, and gummata; it may progress into osteoarticular involvement.
Talaromycosis	<i>Talaromyces marneffeii</i>	Southeast, South, and East Asia*	Mucocutaneous papules with central umbilication due to necrosis; predominantly on head and upper chest; also papules, pustules, nodules, subcutaneous abscesses or ulcers; multiple organ systems compromised.
Lobomycosis (verrucous or plaque-type)	<i>Lacazia loboi</i>	Central/South America*	Plaque and verrucous type: infiltrated plaques, nodules with a wart-like surface; usually in the lower limbs, followed by the ears, upper limbs, and head; ulceration in chronic disease; hypoesthesia/anesthesia.

DCL: diffuse cutaneous leishmaniasis; DCS: disseminated cutaneous sporotrichosis.

\* Also travel-related to endemic areas.



**Table 2** Comparative histological and morphological findings in diffuse cutaneous leishmaniasis (DCL) and differential diagnoses in HIV patients.

	DCL	Disseminated histoplasmosis	DCS	Talaromycosis
Histological features	Nodular dermatitis Absent or non-necrotic granulomas Numerous macrophages (MO): heavily parasitized Few lymphocytes and plasma cells Pseudoepitheliomatous hyperplasia (PH)	Nodular dermatitis Granulomas +/- in HIV patients Yeast within cytoplasm of MO: surrounded by a clear halo Minimal inflammatory response (MIR) Generally without PH	Nodular dermatitis Suppurative or nonspecific granulomas Yeast within phagocytic cells or extracellular MIR PH: +/- in HIV patients	Diffuse dermatitis Focal necrosis, absent granulomas Yeast within cytoplasm of MO, also extracellular Scattered MO PH: absent
Morphology	Amastigote: 3–5 μm round structure with bar shaped kinetoplast inside PAS and Gomori stains: negative <sup>a</sup> Giemsa stain: intensely positive	Ovoid, encapsulated, and budding yeast, 2–4 μm PAS, Gomori: positive Giemsa: positive	Roundish spores, 4–6 μm Cigar bodies, 4–8 μm long Asteroid bodies: – in HIV PAS, Gomori: positive <sup>c</sup> Giemsa: positive <sup>c</sup>	Round/oval thin-walled yeast cell with transverse septum, 3–6 μm PAS, Gomori: positive Giemsa: positive
Additional diagnostic methods	Smear, culture PCR Dermoscopy Montenegro skin test: – in DCL <sup>b</sup> Ab testing: ↓ sensitivity in HIV	Culture, serum β-D-glucan Urine <i>H. capsulatum</i> antigen: ↑ levels in HIV patients PCR Ab testing: not good response in HIV patients	Culture: gold standard PCR <sup>d</sup> Sporotrichin skin test <sup>d</sup> : – in HIV patients	Culture: gold standard Serum galactomannan PCR MALDI-TOF

DCL: diffuse cutaneous leishmaniasis; DCS: disseminated cutaneous sporotrichosis; PCR: polymerase chain reaction; Ab: antibody; MALDI-TOF: matrix-assisted laser desorption ionization time-of-flight method.

<sup>a</sup> Sometimes, amastigotes nuclei catch silver from Gomori stain.<sup>8</sup>

<sup>b</sup> Nevertheless, case reports have shown high positivity of Montenegro skin test in HIV patients.

<sup>c</sup> Fungal elements are often scant and difficult to demonstrate in immunocompetent patients although they can be numerous and easier to find in HIV patients.

<sup>d</sup> They do not have strong standardization.

## Conflict of interests

The authors declare that they have no conflict of interests.

## Acknowledgments

The authors wish to thank Dr. Luis Fernando Palma Escobar, Dr. María Janeth Vargas, and Dr. María Isabel González for their support in guiding and taking the histopathological photographs that illustrate this case report.

## References

- Mokni M. Cutaneous leishmaniasis. *Ann Dermatol Venereol.* 2019;146:232–46, <http://dx.doi.org/10.1016/j.annder.2019.02.002>.
- Clark EH, Serpa JA. Tissue parasites in HIV infection. *Curr Infect Dis Rep.* 2019;21:49, <http://dx.doi.org/10.1007/s11908-019-0703-8>.
- Handler MZ, Patel PA, Kapila R, Al-Qubati Y, Schwartz RA. Cutaneous and mucocutaneous leishmaniasis: differential diagnosis, diagnosis, histopathology, and management. *J Am Acad Dermatol.* 2015;73:911–26, <http://dx.doi.org/10.1016/j.jaad.2014.09.014>.
- Fernandez-Flores A, Saeb-Lima M, Arenas-Guzman R. Morphological findings of deep cutaneous fungal infections. *Am J Dermatopathol.* 2014;36:531–53, <http://dx.doi.org/10.1097/DAD.0b013e31829cc6f3>.
- Pérez C, Solías Y, Rodríguez G. Diffuse cutaneous leishmaniasis in a patient with AIDS. *Biomedica.* 2006;26:485–97, <http://dx.doi.org/10.7705/biomedica.v26i4.314>.
- Sandbank M. Michaelis-Gutmann bodies in macrophages of cutaneous leishmaniasis. *J Cutan Pathol.* 1976;3:263–8, <http://dx.doi.org/10.1111/j.1600-0560.1976.tb00874.x>.

7. Alvarez P, Salinas C, Bravo F. Calcified bodies in New World cutaneous leishmaniasis. *Am J Dermatopathol*. 2011;33:827–30, <http://dx.doi.org/10.1097/DAD.0b013e3181feb7d2>.
  8. Lindoso JA, Cunha MA, Queiroz IT, Moreira CH. Leishmaniasis–HIV coinfection: current challenges. *HIV AIDS (Auckl)*. 2016;8:147–56, <http://dx.doi.org/10.2147/HIV.S93789>.
  9. Bernier R, Barbeau B, Tremblay MJ, Olivier M. The lipophosphoglycan of *Leishmania donovani* up-regulates HIV-1 transcription in T cells through the nuclear factor-kappaB elements. *J Immunol*. 1998;160:2881–8, <http://dx.doi.org/10.4049/jimmunol.160.6.2881>.
  10. Hernández-Ruiz J, Salaiza-Suazo N, Carrada G, Escoto S, Ruiz-Remigio A, Rosenstein Y, et al. CD8 cells of patients with diffuse cutaneous leishmaniasis display functional exhaustion: the latter is reversed, in vitro, by TLR2 agonists. *PLoS Negl Trop Dis*. 2010;4:e871, <http://dx.doi.org/10.1371/journal.pntd.0000871>.
- P.M. Guavita Falla<sup>a,b,\*</sup>, B. Rodríguez Lechtig<sup>b,c</sup>,  
E. Peñaranda Contreras<sup>a,b</sup>, C. Cortés Correa<sup>a,b</sup>
- <sup>a</sup> *Dermatology Program, Facultad de Medicina, Universidad Nacional de Colombia, Bogotá, Colombia*  
<sup>b</sup> *Dermatology Service, Hospital Universitario de La Samaritana, Bogotá, Colombia*  
<sup>c</sup> *Dermatology Program, School of Medicine, Universidad El Bosque, Bogotá, Colombia*
- \* Corresponding author.  
E-mail address: [pmguavitaf@unal.edu.co](mailto:pmguavitaf@unal.edu.co)  
(P.M. Guavita Falla).