

ACTAS Dermo-Sifiliográficas

Full English text available at
www.actasdermo.org

CASE AND RESEARCH LETTER

Presentation of a Rare Case of Skin Signs Consistent With Scurvy and Acrodermatitis Enteropathica in the Context of Enolism With Multiple Nutritional Deficiencies



Presentación de un caso inusual que combina manifestaciones cutáneas compatibles con escorbuto y acrodermatitis enteropática en el contexto de un enolismo con múltiples deficiencias nutricionales

To the Editor,

A 91-year-old man was referred to us for evaluation of a 6-month history pruritic eruptions on his trunk. He was healthy, except for the presence of hypertension and severe alcoholic consumption. The physical examination revealed the presence of pruritic brownish red plaques on the patient's chest and back, follicular keratotic papules on the back, and moist, painful, and erosive erythema in the inguinal region (Fig. 1A–C). There were no disseminated petechiae or hematomas on his entire body, or gingival abnormalities. Peripheral blood test showed normal leukocyte counts (6100/ μ L: normal, 3.3–8.8/ μ L) with slightly elevated neutrophils (71%: normal, 36–70%), decreased lymphocytes (13%: normal, 22–53%), and monocytes, eosinophils and basophils within normal limits (12%, 3% and 1%, respectively). Notably, levels of serum vitamin B1 (19 ng/mL: normal, 24–66 ng/mL), vitamin C (2.0 μ g/mL: normal, 5.5–16.8 μ g/mL), vitamin D (13.9 pg/mL: normal, 20–60 pg/mL), and niacin (4.1 μ g/mL: normal, 4.7–7.9 μ g/mL) were low, while vitamin B2, vitamin B12, and folic acid fell within normal limits. The serum level of zinc was slightly decreased (58.3 μ g/mL: normal, 60–130 μ g/mL).

A skin biopsy specimen obtained from the erythema on the back revealed irregular and moderate acanthosis with mild spongiosis, superficial perivascular lymphocytes and neutrophils, and extravasated erythrocytes. The most notable finding was the presence of follicular plugging in the

dilated follicular infundibulum (Fig. 1D). Another specimen from erosive erythema in the inguinal region showed epidermal hyperplasia with acidophilic degeneration of granular layers (Fig. 1E). Based on clinical and histopathological analysis, we achieved a diagnosis of an unusual clinical presentation of scurvy with multiple vitamin and zinc deficiencies. We treated the patient with a 6-month regimen of vitamin C, niacin, zinc, and multiple vitamin tablets, as well as his alcohol dependence and he gradually improved. However, he restarted drinking alcohol and went through follicular keratotic papules on his back with low vitamin C (3.9 μ g/mL) levels after 2 months. His vitamin B1, vitamin D, niacin, and zinc levels fell within normal limits. The patient stopped alcohol intake, and took vitamin C and multiple other vitamin tablets containing vitamin B1, vitamin B6, and vitamin B12. He showed clinical improvement for another 2 months.

Vitamins are necessary organic molecules for the immune system, cell survival, as well as for the metabolism and function.^{1,2} They act at low doses and come from the diet. Therefore, vitamin deficiency is almost secondary to nutritional deficiency. In the case of our patient, alcoholism could be the main cause of digestive malabsorption leading to skin signs. Among several interesting findings in our patient, the most impressive was follicular plugging and extravasated erythrocytes in the dermis on histopathology examination. Follicular hyperkeratosis is thought to be an important feature of scurvy.^{3,4} Our observations, along with those from former studies, suggest that the outbreak was associated vitamin C deficiency, although brownish erythematous patches are unusual features.

Our patient had multiple vitamin deficiencies and a mild zinc deficiency. Although the correlation between multiple vitamin deficiencies and skin symptoms remains unclear, inguinal lesions in our patient corresponded to deficiencies of both niacin and zinc deficiencies.⁵ We speculate that the unusual clinical presentation can be attributed to deficiencies of multiple vitamins, including vitamin C, as well as zinc deficiency, resulting in the appearance of unusual brownish red plaques with follicular keratotic papules. Therefore, concomitant multiple vitamin and zinc deficiencies can produce complex cutaneous symptoms, as seen in our case. Achieving the histopathological diagnosis would be the best

<https://doi.org/10.1016/j.ad.2023.07.034>

0001-7310/© 2024 AEDV. Published by Elsevier España, S.L.U. This is an open access article under the CC BY-NC-ND license (<http://creativecommons.org/licenses/by-nc-nd/4.0/>).

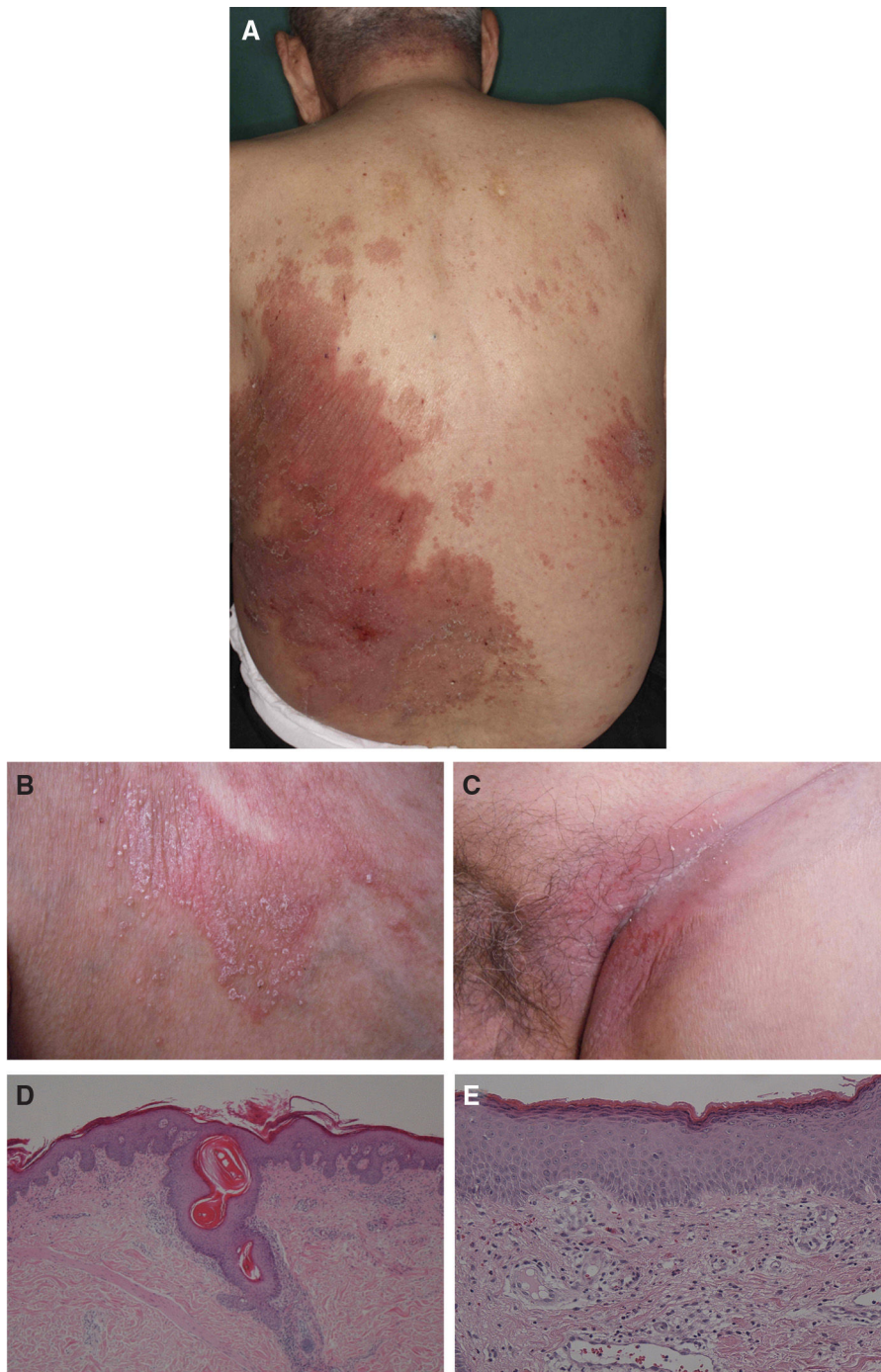


Figure 1 (A) Clinical picture of brownish red plaques on the back. (B) High-power view of follicular keratotic papules on the patient's back. (C) Clinical picture of erosive erythema in the inguinal region. (D) Histopathological examination showing dilated hair follicles and keratin plugging (hematoxylin & eosin staining 100 \times). (E) Histopathology of the inguinal region showed decreased granular cell layer and dilated blood vessels (hematoxylin & eosin staining 200 \times).

method for rare clinical signs in a patient with multiple nutritional deficiencies.

Conflict of interest

The author declares that there is no conflict of interest.

References

1. Ang A, Pullar JM, Currie MJ, Vissers MCM. Vitamin C and immune cell function in inflammation and cancer. *Biochem Soc Trans.* 2018;46:1147–59.
2. Sugita K, Ikenouchi-Sugita A, Nakayama Y, Yoshioka H, Nomura T, Sakabe J, et al. Prostaglandin E(2) is critical for the development

- of niacin-deficiency-induced photosensitivity via ROS production. *Sci Rep.* 2013;3:2973.
3. Hirschmann JV, Raugi GJ. Adult scurvy. *J Am Acad Dermatol.* 1999;41:895–906 [quiz 907-810].
 4. Lipner S. A classic case of scurvy. *Lancet.* 2018;392:431.
 5. Barthelemy H, Chouvet B, Cambazard F. Skin and mucosal manifestations in vitamin deficiency. *J Am Acad Dermatol.* 1986;15:1263–74.

K. Sugita

*Division of Dermatology, Department of Internal Medicine,
Faculty of Medicine, Saga University, Saga, Japan*
E-mail address: sugita@cc.saga-u.ac.jp