


# Journal Pre-proof

Fusariosis angioinvasiva con expresión cutánea tras trasplante de progenitores hematopoyéticos

B. Rodríguez Sánchez F. Arias Lotto M.M. Santos Sebastián M.  
Campos Domínguez



PII: S0001-7310(24)00908-6  
DOI: <https://doi.org/doi:10.1016/j.ad.2024.11.018>  
Reference: AD 4186

To appear in: *Actas dermosifiliograficas*

Received Date: 21 April 2023  
Accepted Date: 12 July 2023

Please cite this article as: Rodríguez Sánchez B, Arias Lotto F, Santos Sebastián MM, Campos Domínguez M, Fusariosis angioinvasiva con expresión cutánea tras trasplante de progenitores hematopoyéticos, *Actas dermosifiliograficas* (2024), doi: <https://doi.org/10.1016/j.ad.2024.11.018>

This is a PDF file of an article that has undergone enhancements after acceptance, such as the addition of a cover page and metadata, and formatting for readability, but it is not yet the definitive version of record. This version will undergo additional copyediting, typesetting and review before it is published in its final form, but we are providing this version to give early visibility of the article. Please note that, during the production process, errors may be discovered which could affect the content, and all legal disclaimers that apply to the journal pertain.

© 2024 AEDV. Published by Elsevier España, S.L.U.

Refers to AD\_4101

CARTA CIENTÍFICO-CLÍNICA

## Fusariosis angioinvasiva con expresión cutánea tras trasplante de progenitores hematopoyéticos

[[Translated article]]Angioinvasive Fusariosis with Cutaneous Manifestations After Hematopoietic Stem Cell Transplantation

B. Rodríguez Sánchez<sup>a</sup>

F. Arias Lotto<sup>b</sup>

M. M. Santos Sebastián<sup>c</sup>

M. Campos Domínguez<sup>a</sup>

<sup>a</sup>Servicio de Dermatología, Hospital General Universitario Gregorio Marañón, Madrid, España.

<sup>b</sup>Servicio de Anatomía Patológica, Hospital General Universitario Gregorio Marañón, Madrid, España.

<sup>c</sup>Servicio de Pediatría, Hospital General Universitario Gregorio Marañón, Madrid, España.

Autora para correspondencia: Belén Rodríguez Sánchez. Belrs222@gmail.com

To the Editor,

Invasive fungal infections are an increasingly important problem in immunocompromised hosts, with a high mortality rate<sup>1</sup>.

A 16-year-old hospitalized adolescent diagnosed with sickle cell anemia with a 1-day history of 4 purpuric nodules, 5 mm in diameter, located on the neck, right upper limb, and abdomen (Fig. 1). The patient had undergone two consecutive hematopoietic progenitor transplants, the last one 9 days prior, and had neutrophil counts of 0 per microliter, so he was on prophylactic therapy with liposomal amphotericin B at 3 mg/kg/day. He remained afebrile. The patient had experienced consolidative pneumonia a few days before, with a bronchoalveolar lavage PCR negative for fungi, although the fungal marker galactomannan had increased from 0.17 up to 5.71. Due to suspicion of invasive fungal infection, biopsies were performed for calcofluor staining, histological examination and fungal culture. Blood cultures were also taken. The calcofluor staining revealed fungal structures, so the dose of amphotericin B was increased to 5 mg/kg/day, and isavuconazole was added. The hematoxylin-eosin staining showed, in the middle dermis, a group of hyaline and septate hyphae located intravascularly and immediately adjacent to the vessel (Figs. 2 and 3). The fungal culture grew *Fusarium verticillioides* sensitive to amphotericin B, posaconazole, and voriconazole. Blood cultures all tested negative. Isavuconazole was switched for voriconazole, and filgrastim was administered, resulting in a partial recovery of neutropenia, an excellent clinical response, resolution of the condition, and a reduction in galactomannan levels down to 0.18.

Invasive fungal infections are a serious problem in immunocompromised patients, particularly in those with severe and prolonged neutropenia. Antifungal resistance associated with prophylactic use has exacerbated this problem<sup>2</sup>.

Opportunistic fungi responsible for these infections include yeasts (such as *Candida* spp.) and filamentous fungi. The latter include *Aspergillus* spp., agents of mucormycosis (such as *Rhizopus*, *Mucor*, or *Rhizomucor*), hyalohyphomycosis (such as *Fusarium*), and pheohyphomycosis (such as *Alternaria*). These fungi are ubiquitous in the environment and rarely cause infections in immunocompetent individuals. However, in neutropenic patients, they can invade blood vessels, causing ischemia, infarction, and tissue necrosis, including skin necrosis<sup>3</sup>.

In disseminated *Fusarium* infections, skin lesions are present in more than 70% of patients<sup>4</sup>. These lesions are typically multiple and widespread. They include red or gray macules or papules, some with central necrosis or eschar resembling ecthyma, purpuric papules, pustules, or subcutaneous nodules. This clinical presentation results from thrombosis of dermal vessels by *Fusarium* hyphae, subsequent extravasation of erythrocytes, and further focal dermal necrosis and epidermal ulceration<sup>1</sup>. Patients

often present with myalgias and persistent fever unresponsive to empirical antibiotic and antifungal treatment<sup>5</sup>.

Once the infection has been suspected, the diagnostic process should begin immediately, including biopsy with an immediate fungal stain (such as calcofluor or KOH), histological examination, fungal culture, blood cultures, and radiological tests to assess pulmonary and sinus involvement<sup>1</sup>. Blood cultures are only positive in 40% of patients with disseminated fusariosis<sup>6</sup>, possibly due to the use of prophylactic antifungals or sample collection conditions. Definitive diagnosis requires histology demonstrating fungal structures inside the vessels, which explains the need for urgent microscopic examination, either with rapid stains or frozen histological sections. Nevertheless, culture is key to identifying the type of fungus (as *Aspergillus* and *Fusarium* appear identical under the microscope) and determining its sensitivity.

Regarding the treatment of invasive fusariosis, there are no studies comparing the efficacy of monotherapy vs combined therapy. However, poor responses to monotherapy have favored the use of combination treatments<sup>7</sup>. *Fusarium* is intrinsically resistant to echinocandins and flucytosine, and in our setting, it shows greater sensitivity to amphotericin B and voriconazole than to isavuconazole<sup>7,8</sup>. The combination proposed by the guidelines is amphotericin B along with voriconazole<sup>9</sup>. However, what truly impacts prognosis is the recovery of neutropenia, so leukocyte transfusions and growth factors should also be considered<sup>1</sup>. The mortality rate of patients with disseminated infection is 80%<sup>1</sup>.

For prevention, it is necessary to control potential entry points for the fungus. The primary route is airborne, followed by injured skin and mucous membranes. Environmental sources of *Fusarium*, such as tap water, should be avoided, and surface cleaning should be thorough, using detergent followed by disinfectant<sup>10</sup>. Injured skin is responsible for 33% of cases, typically paronychia or traumatic ulcers. *Fusarium*-related onychomycosis is estimated to be underdiagnosed and represents 6% of onychomycosis cases in immunocompetent patients<sup>1</sup>. Careful examination of the nails and skin lesions is important, with culture collection and appropriate antifungal therapy. Antifungal prophylaxis in neutropenic patients is important but often insufficient. In one series, 50% of patients with disseminated fusariosis were on prophylactic or empirical antifungal treatment, at least, 1 week before diagnosis<sup>1</sup>, as occurred in our case.

In conclusion, in a neutropenic patient with skin lesions consistent with angioinvasive mycosis, it is important to perform rapid diagnostic evaluation and initiate treatment immediately, which should include high-dose antifungal therapy and measures to recover neutropenia.

## Conflicts of interest

None declared.

## References

<BIBL>

<BIB>

1

S Bodey F G.P.

S Boktour F M.

S Mays F S.

S Duvic F M.

S Kontoyiannis F D.

S Hachem F R.<ET-AL>

AT Skin lesions associated with Fusarium infection

JT J Am Acad Dermatol.

V 47

D 2002

P 659-L 666

DOI 10.1067/mjd.2002.123489

<original\_ref>[1] G.P. Bodey, M. Boktour, S. Mays, et al. Skin lesions associated with Fusarium infection. J Am Acad Dermatol. 47 (2002), pp. 659-666.

<DOI>10.1067/mjd.2002.123489</DOI>.</original\_ref>

</BIB>

<BIB>

2

S Jenks F J.D.

S Cornely F O.A.

S Chen F S.C.

S Thompson F G.R.JIII

S Hoenigl F M.

AT Breakthrough invasive fungal infections: Who is at risk?

JT Mycoses

V 63

D 2020

P 1021-L 1032

DOI 10.1111/myc.13148

<original\_ref>[2] J.D. Jenks, O.A. Cornely, S.C. Chen, G.R. 3<sup>rd</sup> Thompson, M. Hoenigl. Breakthrough invasive fungal infections: Who is at risk? *Mycoses* 63 (2020), 1021-1032.

<DOI>10.1111/myc.13148</DOI>.</original\_ref>

</BIB>

<BIB>

3

S Shields F B.E.

S Rosenbach F M.

S Brown-Joel F Z.

S Berger F A.P.

S Ford F B.A.

S Wanat F K.A.

AT Angioinvasive fungal infections impacting the skin: Background, epidemiology and clinical presentation

JT J Am Acad Dermatol.

V 80

D 2019

P 869-L 880

DOI 10.1016/j.jaad.2018.04.059

<original\_ref>[3] B. E. Shields, M Rosenbach, Z. Brown-Joel et al. Angioinvasive fungal infections impacting the skin: Background, epidemiology and clinical presentation. *J Am Acad Dermatol.* 80 (2019), 869-880. <DOI>10.1016/j.jaad.2018.04.059</DOI>.</original\_ref>

</BIB>

<BIB>

4

S Nucci F M.

S Anaissie F E.

AT Fusarium infections in immunocompromised patients

JT Clin Microbiol Rev.

V 20

D 2007

P 695-L 704

DOI 10.1128/CMR.00014-07

<original\_ref>[4] M. Nucci, E. Anaissie. Fusarium infections in immunocompromised patients. Clin Microbiol Rev. 20 (2007), 695-704. <DOI>10.1128/CMR.00014-07</DOI>.</original\_ref>

</BIB>

<BIB>

5

S Álvarez F F.

S Figueras F C.

S Roselló F E.

AT Infecciones fúngicas invasivas emergentes

JT An Pediatr (Barc).

V 73

D 2010

P 52

DOI 10.1016/j.anpedi.2010.04.009

C e1-52.e6.

<original\_ref>[5] F. Álvarez, C. Figueras, E. Roselló. Infecciones fúngicas invasivas emergentes. An Pediatr (Barc). 73 (2010), 52.e1-52.e6. <DOI>10.1016/j.anpedi.2010.04.009</DOI>.</original\_ref>

</BIB>

<BIB>

6

S Hoenigl F M.

S Salmanton-García F J.

S Walsh F T.J.

S Nucci F M.

S Neoh F C.F.

S Jenks F J.D.<ET-AL>

AT Global guideline for the diagnosis and management of rare mould infections: an initiative of the European Confederation of Medical Mycology in cooperation with the International Society for Human and Animal Mycology and the American Society for Microbiology

JT Lancet Infect Dis.

V 21

D 2021

P e246-L e257

DOI 10.1016/S1473-3099(20)30784-2

<original\_ref>[6] M. Hoenigl, J. Salmanton-García, T.J. Walsh et al. Global guideline for the diagnosis and management of rare mould infections: an initiative of the European Confederation of Medical Mycology in cooperation with the International Society for Human and Animal Mycology and the American Society for Microbiology. Lancet Infect Dis. 21 (2021), e246-e257. <DOI>10.1016/S1473-3099(20)30784-2</DOI>.</original\_ref>

</BIB>

<BIB>

7

S Guarro F J.

AT Fusariosis, a complex infection caused by a high diversity of fungal species refractory to treatment

JT Eur J Clin Microbiol Infect Dis.

V 32

D 2013

P 1491-L 1500

DOI 10.1007/s10096-013-1924-7

<original\_ref>[7] J. Guarro. Fusariosis, a complex infection caused by a high diversity of fungal species refractory to treatment. Eur J Clin Microbiol Infect Dis. 32 (2013), 1491–1500.

<DOI>10.1007/s10096-013-1924-7</DOI>.</original\_ref>

</BIB>

<BIB>

8



S Broutin F A.

S Bigot F J.

S Senghor F Y.

S Moreno-Sabater F A.

S Guitard F J.

S Hennequin F C.

AT In vitro susceptibility of Fusarium to Isavuconazole

JT Antimicrob Agents Chemother.

V 64

DOI 10.1128/AAC.01621-19

D 2020

C pp. e01621-19.

<original\_ref>[8] A. Broutin, J. Bigot, Y. Senghor et al. In vitro susceptibility of Fusarium to Isavuconazole. Antimicrob Agents Chemother. 64, <I>2</I> (2020), pp. e01621-19.

<DOI>10.1128/AAC.01621-19</DOI>.</original\_ref>

</BIB>

<BIB>

9

S Berger F A.P.

S Ford F B.A.

S Brown-Joel F Z.

S Shields F B.E.

S Rosenbach F M.

S Wanat F K.A.<ET-AL>

AT Angioinvasive fungal infections impacting the skin: Diagnosis, management, and complications

JT J Am Acad Dermatol.

V 80

D 2019

P 883-L 898

DOI 10.1016/j.jaad.2018.04.058

<original\_ref>[9] A. P. Berger, B.A. Ford, Z. Brown-Joel et al. Angioinvasive fungal infections impacting the skin: Diagnosis, management, and complications. J Am Acad Dermatol. 80 (2019), 883-898. <DOI>10.1016/j.jaad.2018.04.058</DOI>.</original\_ref>

</BIB>

<BIB>

10

S Uriburu F C.

S Rovira F M.

AT Profilaxis de las infecciones en el paciente neutropénico

JT Enferm Infecc Microbiol Clin.

V 23

D 2005

P 14-L 18

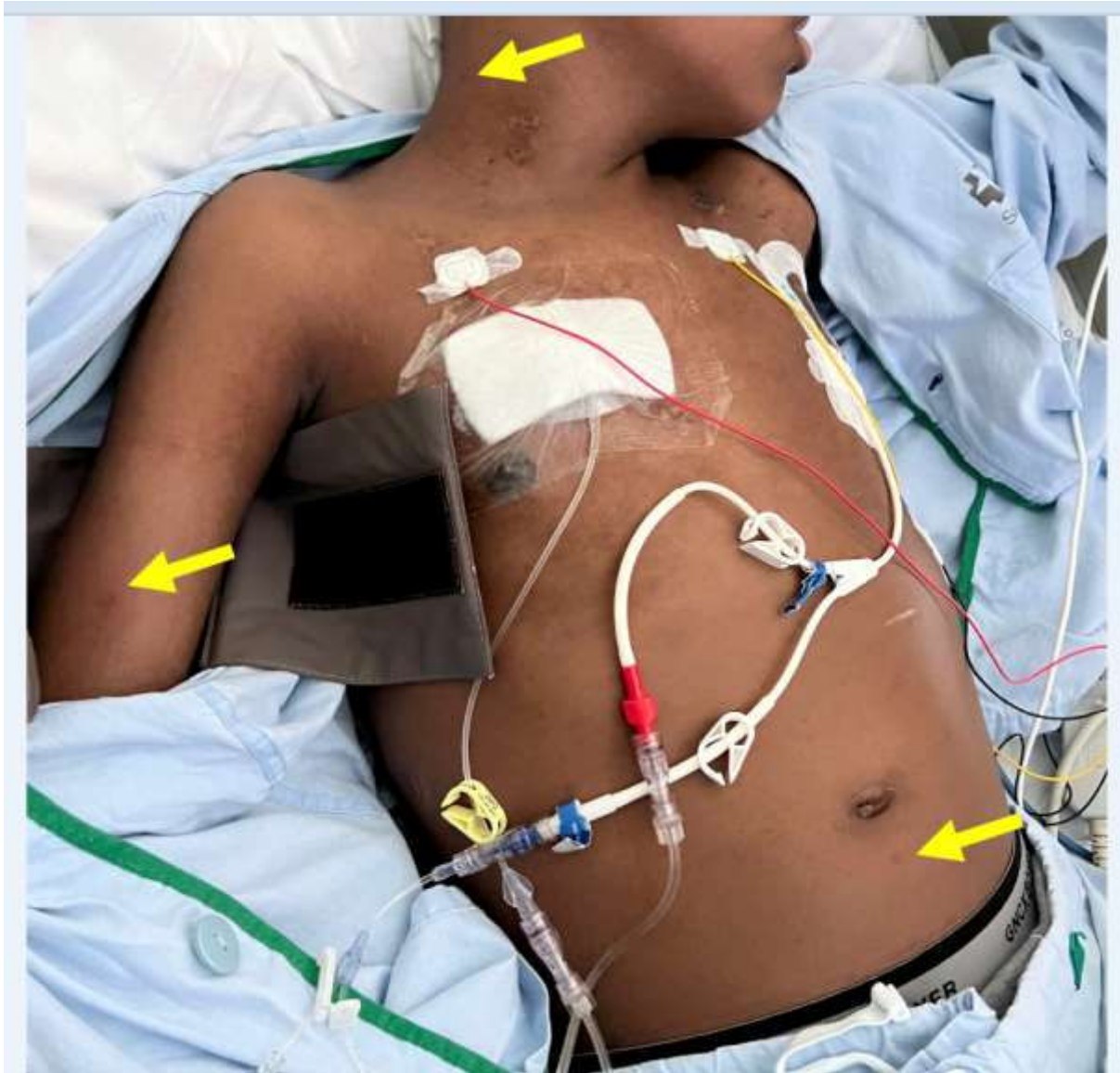
DOI 10.1157/13091241

<original\_ref>[10] C. Uriburu, M. Rovira. Profilaxis de las infecciones en el paciente neutropénico. Enferm Infecc Microbiol Clin. 23,<I>5</I> (2005), 14-18. <DOI>10.1157/13091241</DOI>.</original\_ref>

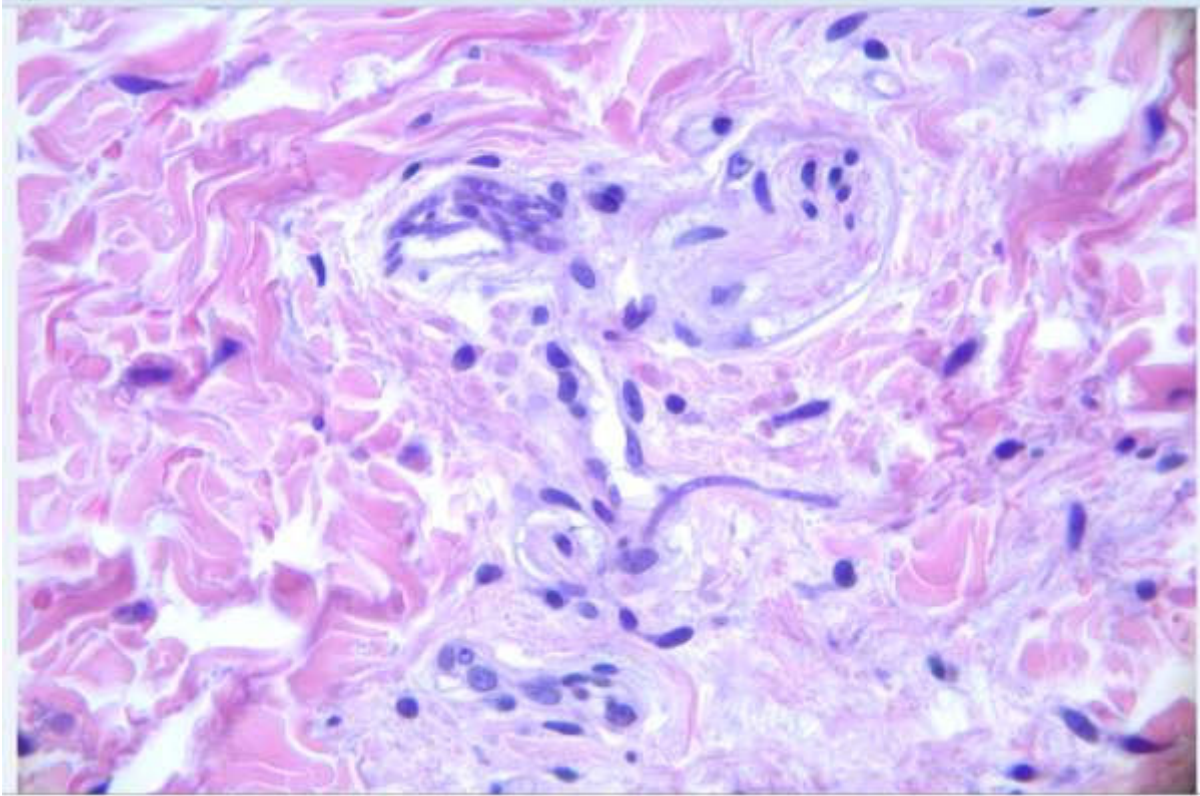
</BIB>

</BIBL>

**Figure 1.** Purpuric nodules, 5 mm in diameter, located on the neck, right upper limb, and abdomen (arrows).



**Figure 2.** A group of hyaline and septate hyphae located intravascularly, and in the dermis immediately adjacent to the vessel. Hematoxylin-eosin stain.



Journal

**Figure 3.** A group of hyaline and septate hyphae located intravascularly, and in the dermis immediately adjacent to the vessel. A) PAS stain. B) Grocott stain.

