




ACTAS Dermo-Sifiliográficas

Full English text available at www.actasdermo.org



CASE AND RESEARCH LETTER

[Translated article] Compression Therapy in Leg Ulcers Due to Increased Diffusion Space

Terapia compresiva en las heridas de pierna por aumento del espacio de difusión

To the Editor,

In Spain, heart failure is the most common reason for hospitalization in elderly patients. Its key clinical signs include dyspnea, fatigue, and peripheral edema. The rapid onset of lower extremity edema often leads to the development or worsening of wounds of varying complexity. This occurs due to an increased diffusion distance between the capillary network and the dermoepidermal tissue caused by the edema, impairing tissue perfusion. Additionally, compensatory mechanisms due to tissue hypoperfusion activate the renin-angiotensin-aldosterone system, resulting in greater sodium and water retention¹ and further clinical worsening of the edema.

In patients with pre-existing conditions that reduce tissue perfusion—atherosclerosis or phlebolymphe-
dema—peripheral edema in decompensated heart failure can trigger Martorell ulcers (an atherosclerosis-related ulcer spectrum) or worsen previous predominantly venous ulcers.² Furthermore, the skin stretching increases, weakening the dermoepidermal junction. In the context of old age-related dermatoporosis, there is an increased tendency for the formation and complication of skin tears. Fig. 1 illustrates the pathophysiology and comorbidities associated with wounds due to increased diffusion distance.

Current clinical practice guidelines from the American College of Cardiology (ACC) and the American Heart Association (AHA) recommend focusing heart failure decompensation treatment on peripheral decongestion, as it is one of the most common and debilitating symptoms in these patients.³

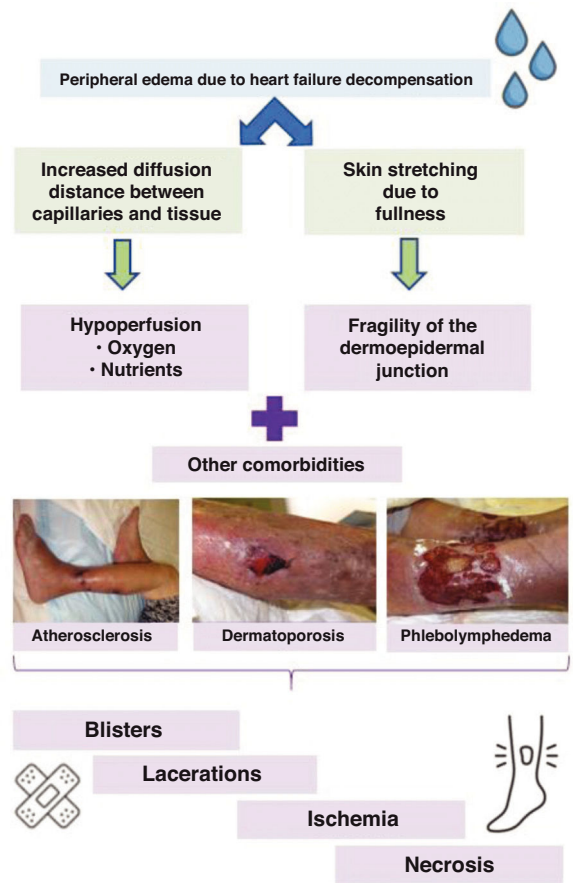


Figure 1 Pathophysiology and comorbidities in wounds due to increased diffusion distance.

Historically, compression therapy was contraindicated in heart failure. However, the only absolute contraindications now are severe peripheral artery disease and advanced heart failure classified as NYHA (New York Heart Association) IV—characterized by an inability to perform physical activity without discomfort, with symptoms present even at rest.⁴ In less severe cases, gradual increases in compression pressure have shown only brief phases of increased cardiac load and can significantly reduce peripheral edema, although the available scientific literature on compression therapy in heart failure is fairly limited.¹

DOI of original article:
<https://doi.org/10.1016/j.ad.2024.05.030>

<https://doi.org/10.1016/j.ad.2025.02.011>

0001-7310/© 2024 AEDV. Published by Elsevier España, S.L.U. This is an open access article under the CC BY-NC-ND license (<http://creativecommons.org/licenses/by-nc-nd/4.0/>).

Please cite this article as: B. Gonzalez Rodriguez, L. Calderon Lozano, J. Fulgencio Barbarin et al., [Translated article] Compression Therapy in Leg Ulcers Due to Increased Diffusion Space, ACTAS Dermo-Sifiliográficas, <https://doi.org/10.1016/j.ad.2025.02.011>

51 In daily dermatological practice, wounds triggered or
52 worsened by a cardiac decompensation episode are a com-
53 mon reason for consultation. Compression therapy has
54 proven beneficial, reducing the length of stay, diuretic drug
55 needs, and improving quality of life when using devices with
56 Velcro closures.^{3,4} In our opinion, this therapy is underused,
57 likely due to fear or lack of knowledge.

58 Compression therapy must always be tailored to the
59 patient's functional status, ideally using high-rigidity
60 devices (e.g., Velcro-closure devices, short-stretch ban-
61 dages, or multi-component systems) alongside anti-edema
62 measures such as elevating the legs above heart level while
63 at rest.⁵

64 In this context, considering the increased diffusion dis-
65 tance due to heart failure decompensation—a common yet
66 sometimes neglected condition—is essential as a factor that
67 exacerbates poor wound healing in the legs. Dermatologists
68 should advocate for and support the use of compression
69 therapy as an adjuvant therapy to diuretics in reducing the
70 peripheral edema characteristic of this disease. In fact,
71 compression therapy has proven useful in reducing edema
72 resistant to classical diuretics.⁶

73 Conflicts of interest

74 None declared.

75 Acknowledgments

76 We wish to thank **Dr. Elena Conde** for her warmth and ded-
77 ication to numerous trainees, her exemplary patient care,
78 and her inspiration to a generation of dermatologists in the
management of geriatric dermatological patients.

References

1. Urbanek T, Juško M, Kuczmik W. Compression therapy for leg oedema in patients with heart failure. *ESC Heart Fail.* 2020;7:2012–20. 80
2. Augéy F, Pinet A, Renaudier P. Insuffisance cardiaque et ulcère de stase: une association significative (étude prospective de 100 cas) [Heart failure and stasis ulcer: a significant association (prospective study of 100 cases)]. *Ann Dermatol Venerol.* 2010;137:353–8. 81
3. Fadel RA, Cerna Viacava R, Makki T, Dagher Fadel C, Malette K, Demertzis ZD, et al. Compression wraps as adjuvant therapy in the management of acute systolic heart failure. *Heliyon.* 2023;9:e19008. 82
4. Rabe E, Partsch H, Morrison N, Meissner MH, Mosti G, Lattimer CR, et al. Risks and contraindications of medical compression treatment—a critical reappraisal. An international consensus statement. *Phlebology.* 2020;35:447–60. 83
5. Conde Montero E, Dissemond J, Protz K. Terapia compresiva en dermatología. *Actas Dermosifiliogr.* 2024;115:693–701. 84
6. Collado Macián C, Pujol Pocull D, Dominguez F, López-Azor JC, Garcia-Pavia P, Nuñez J, et al. Case report: alternative approach for management of refractory volume overload in heart failure: usefulness of venous leg compression. *Front Cardiovasc Med.* 2023;10:1230980. 85

B. Gonzalez Rodriguez^{a,*}, L. Calderon Lozano^a,
J. Fulgencio Barbarin^a, E. Conde Montero^b **Q1**

^a Servicio de Dermatología, Hospital Universitario 12 de Octubre, Madrid, Spain

^b Servicio de Dermatología, Hospital Virgen de la Torre (Hospital Infanta Leonor), Madrid, Spain

* Corresponding author.

E-mail address: borjasturias@hotmail.com
(B. Gonzalez Rodriguez). 103