

## CASES FOR DIAGNOSIS

### Bluish Nodule in the Hand

S Vildósola,<sup>a</sup> P Manrique,<sup>a</sup> JL Artola,<sup>a</sup> I Bilbao,<sup>a</sup> V Morillo,<sup>a</sup> and I Zabalza<sup>b</sup>

<sup>a</sup>Servicio de Dermatología and <sup>b</sup>Servicio de Anatomía Patológica, Hospital de Galdakao, Vizcaya, Spain

#### Patient History

A 58-year-old woman with no history of interest except for 3 abortions and 2 term pregnancies with healthy newborns consulted for a hard, bluish-black gray nodule of 3 mm diameter located on the distal phalanx of the fourth finger of the left hand. The nodule was painful on palpation and had appeared about 3 months earlier. The patient did not usually engage in heavy manual labor and had not done so prior to onset of the lesions.

#### Physical Examination

A bluish-black nodular lesion with a diameter of 3 mm was observed on the palmar side of the distal phalanx of the

fourth finger of the left (nondominant) hand (Figure 1); the lesion did not disappear with pressure. Other bluish macular areas were also seen on various fingers of both hands.

#### Additional Examinations

The laboratory workup included complete blood count, biochemistry, analysis of anticardiolipin antibodies and lupus anticoagulant, and a coagulation test, but showed no relevant data.

No compression was observed in the neck, mediastinum, or limbs.

The nodule was excised (Figure 2), and a biopsy was also taken of one of the bluish maculae.

In the nodule, a severely dilated venous vascular structure with no wall abnormalities and an organized thrombus in its interior was observed in the dermis.

The macule also contained a venous vascular structure in the dermis with severe congestion of the lumen.

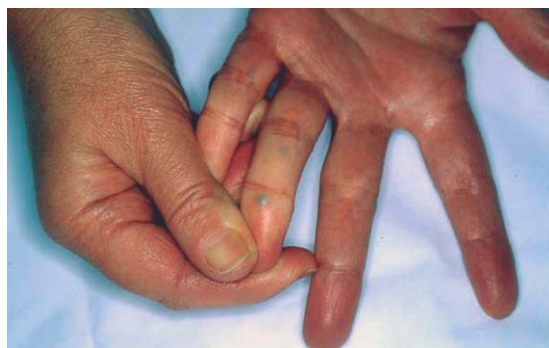

Figure 1.

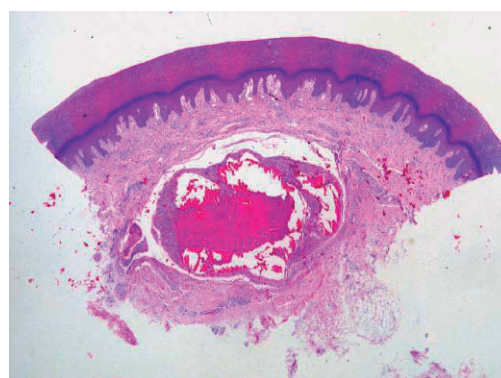


Figure 2. Hematoxylin-eosin, x4.

Correspondence:  
Susana Vildósola Esturo  
Servicio de Dermatología  
Hospital de Galdakao  
Barrio Labeaga, s/n  
48960 Galdakao, Bizkaia  
E-mail: sve@aedv.es

Manuscript accepted for publication January 23, 2007

What is your diagnosis?

## Diagnosis

Thrombosis of palmar digital veins

## Course and Treatment

At the time of writing, the patient is stable and no new nodules have appeared. Therefore, no additional treatment has been prescribed.

## Comment

Thrombosis of the palmar digital veins was described in 1936 by Jadassohn<sup>1</sup> and, although deep vein thrombosis is common and well known, thrombosis of the superficial veins is rare, occurring mainly in the lower limbs because of trauma, usually in previous varices, and in the upper limbs due to intravenous infusion of chemicals or medications.

Thrombosis of the palmar digital veins is observed most often in women between 35 and 65 years of age. It usually presents as one or more nodules of lesser or greater sensitivity on the palmar or lateral side of the fingers, with a bluish-black, erythematous, or flesh-colored surface. The most common site is the fourth finger on either the dominant or nondominant side, but not always in relation to wearing a ring. It presents most frequently around the proximal interphalangeal joint or near the distal interphalangeal joint, and it has rarely been described on the first and fifth fingers. The oblique and superficial axial veins are affected most often, with no reports of dorsal vein involvement.

The diagnosis is based mainly on clinical symptoms and is confirmed by evidence of a more or less organized intraluminal thrombus,<sup>2,3</sup> with noninvasive assessments by ultrasound imaging also possible.

The predisposing factors are the unique anatomical characteristics of the veins, which are surrounded by a layer of fine connective tissue and fat, with multiple valves to ensure one-way flow, in particular, palmar-dorsal and radial-cubital, and are smaller in diameter than the dorsal veins.<sup>4,5</sup> In addition, the veins undergo local, repeated, imperceptible traumas with increased intraluminal pressure. Hypercoagulable states have been observed in only a few cases: in 2002, Hofer<sup>6</sup> described a patient with increased antiphospholipid antibodies. In the case of our patient, tests done after the third abortion and before the

last term pregnancy, as well as those done at the present time showed no coagulation abnormalities.

The clinical presentation may be similar to thrombosis in other veins, but without clinical or histological signs of inflammation, persisting for months and being related to imperceptible traumas; it may be similar to thrombophlebitis of the legs, with inflammation, flushing, pain, and heat, lasting a few weeks, and related to a hypercoagulable state; or it may be similar to Mondor disease, lasting hours or days, and related to strenuous manual labor.<sup>6</sup>

The differential diagnosis should include varices with no thrombosis, in which the lesions disappear with pressure (using the side of a glass) and the size increases when a tourniquet is applied at the base of the finger. The differential diagnosis should also include hemangiomas, which increase in size with the same maneuver, Achenbach syndrome, which consists of spontaneous, coin-sized hematomas on the palmar sides of the hands, also described mainly in women, and with a variety of other lesions, such as epidermal inclusion cysts, giant-cell tumors, ganglions, lipomas, blue nevi, and melanoma metastasis.

In terms of disease course, the lesion may progress toward complete obliteration of the vein or, more commonly, toward vein recanalization.

The treatment may be conservative,<sup>2</sup> with the application of massages, compression, hot compresses, acetylsalicylic acid for pain, or surgical in case of persistent pain, progressive increase in size, or doubts about the diagnosis.

### Conflicts of Interest

The authors declare no conflicts of interest.

## References

1. Jadassohn W. Ein fall von thrombosen in den fingervenvenen. *Schweiz Med Wochenschr.* 1936;66:549.
2. van Rossum M, van der Lei B, van Wingerden J. Thrombosis of the palmar digital veins: a report of 6 cases and a review of the literature. *Ann Plast Surg.* 2005;55:629-32.
3. Gargan TJ, Slavin SA. Varix of the digit. *Plast Reconstr Surg.* 1988;81:590-3.
4. Lucas GL. The pattern of venous drainage of the digits. *J Hand Surg.* 1984;9:448-50.
5. Moss SH, Schwartz KS, von Drasek-Ascher G, Ogden LL 2nd, Wheeler CS, Lister GD. Digital venous anatomy. *J Hand Surg [Am].* 1985;10:473-82.
6. Hofer T. Palmar digital vein thromboses: their different expressions. *Dermatology.* 2002;204:240-3.