

PRACTICAL DERMATOLOGY

Practical Management of Hidradenitis Suppurativa

J Pedraz and E Daudén

Servicio de Dermatología, Hospital Universitario de la Princesa, Madrid, Spain

Abstract. Hidradenitis suppurativa is a chronic inflammatory disease that usually affects areas of the skin with a high density of apocrine glands (axillae, groin, perianal and perineal regions, submammary area, etc). It usually appears in women during puberty. The etiology of the disease is unknown, although it is thought to be a primary defect of the hair follicle. When diagnosing hidradenitis suppurativa, a number of genetic and hormonal predisposing factors should be considered alongside other putative triggers, such as obesity, smoking, and tight clothing. Diagnosis is essentially clinical and it is important to bear in mind the possible complications associated with the disease, such as the development of tumors. Management of the disease includes general measures (antiseptic soaps, warm baths, etc), pharmacological therapy (topical, intralesional, and systemic), surgery (direct closure, second-intention healing, grafts, flaps, etc), and other measures (carbon dioxide laser, radiation therapy, etc). It is important that the disease be diagnosed and treated as soon as possible given the potential physical and psychological problems that it can generate.

Key words: surgery, hidradenitis suppurativa, infliximab, treatment.

MANEJO PRÁCTICO DE LA HIDROSADENITIS SUPURATIVA

Resumen. La hidrosadenitis suppurativa (HS) es una enfermedad inflamatoria crónica que suele manifestarse en zonas cutáneas con gran densidad de glándulas apocrinas (axilas, ingles, región perianal, perineal, submamaria, etc.). Suele iniciarse en mujeres durante la pubertad. La etiología de esta enfermedad es desconocida, aunque se considera un defecto primario del folículo piloso. Debemos considerar una serie de factores predisponentes (genéticos y hormonales) y otros desencadenantes controvertidos (obesidad, tabaco, ropa ajustada, etc.) en el diagnóstico de la HS. El diagnóstico es básicamente clínico y es importante tener en cuenta las posibles complicaciones derivadas del padecimiento de esta enfermedad, como la posibilidad de desarrollar lesiones tumorales. El manejo de esta patología comprende diversas pautas: medidas generales (jabones antisépticos, baños templados, etc.), farmacológicas (tópicas, intralesionales y sistémicas), quirúrgicas (cierre directo, cierre por segunda intención, injertos, colgajos, etc.) y otras medidas (láser CO₂, radioterapia, etc.). Es importante identificar y tratar cuanto antes esta patología debido a los potenciales problemas físicos y psicológicos en los que puede derivar.

Palabras clave: cirugía, hidrosadenitis suppurativa, infliximab, tratamiento.

Introduction

Hidradenitis suppurativa is a chronic inflammatory disease that usually begins during puberty and is more common in women.¹ It presents clinically with recurrent abscesses, sinus

tracts, and scarring, mainly affecting areas with apocrine glands: axillae, groin, perianal and perineal regions, breast and submammary regions, buttocks, and pubic region. Its prevalence is unknown but is estimated to be approximately 4%.² Coexistence with Crohn disease has occasionally been observed in perianal hidradenitis suppurativa; specifically, this disease was found in 24 of 61 patients in a study at the Cleveland Clinic.¹ This circumstance can dictate the treatment regimen.

The etiology of the disease is unknown, although a genetic component is believed to exist, with a probable hormonal influence. It has come to be considered as a disorder of the terminal follicular epithelium that produces follicular occlusion in areas with apocrine glands.

Correspondence:
Javier Pedraz Muñoz
Servicio de Dermatología
Hospital Universitario de la Princesa
C/ Diego de León, 62
28006 Madrid, Spain
javierpedraz@aedv.es

Table 1. Predisposing Factors, Triggering Factors, Associated Diseases, and Complications of Hidradenitis Suppurativa

<i>Predisposing Factors</i>	<i>Triggering Factors</i>	<i>Associated Diseases</i>	<i>Complications</i>
Genetic	Obesity	Acne conglobata	Contractures
			Infections
	Tight clothing	Dissecting cellulitis of the scalp	Interstitial keratitis
Endocrine	Deodorants, depilation products, shaving	Pilonidal sinus	Fistulas
			Anemia
	Drugs	Crohn disease	Skin and other tumors
			Congenital α 1-antitrypsin deficiency
		Arthropathy	

Colonization by bacteria such as coagulase-negative staphylococci or *Staphylococcus aureus* is thought to be a secondary event.

It is a physically and psychologically debilitating disease and should therefore be treated. The foul odor that the lesions of hidradenitis suppurativa can produce can lead to social isolation and depression, and hidradenitis suppurativa is considered to be one of the dermatological diseases with greatest impact on a patient's quality of life.³

The diagnosis of this disorder is basically clinical and its management is very often complicated as there is frequently a poor response to the available treatments, which can be divided into 4 groups: general measures, pharmacological treatment, surgical treatment, and other treatment regimens.

Triggering and Predisposing Factors and Associations

There is a series of predisposing factors that must be taken into consideration and triggering factors that it is advisable to avoid. A summary of the associated factors and diseases is shown in Table 1.

Predisposing Factors

1. Genetic factors⁴: an autosomal dominant inheritance has been postulated.⁵
2. Endocrine factors: sex hormones, principally an excess of androgens, are thought to be involved, although the apocrine glands are not sensitive to these hormones.⁶ Women often have outbreaks before menstruation and

after pregnancy, and the disease usually remits during pregnancy and after the menopause.

Triggering Factors

1. Obesity¹ is considered to be an exacerbating rather than a triggering factor,⁴ through mechanical irritation, occlusion, and maceration.
2. Tight clothing¹
3. Smoking⁷
4. Deodorants, depilation products, shaving of the affected area: their association with the condition is currently under discussion.⁸
5. Drugs: oral contraceptives⁹ and lithium¹⁰

Associations

1. Acne conglobata: severe acne that affects the pectoral region, back, and buttocks, consisting principally of comedones and small purulent nodules.
2. Dissecting cellulitis of the scalp (perifolliculitis capitis abscedens et suffodiens): this condition, which is similar to acne conglobata, affects the scalp and can cause alopecia.
3. Pilonidal sinus

The association of acne conglobata, dissecting cellulitis of the scalp, and hidradenitis suppurativa is what has come to be called the follicular occlusion triad, and the combination of these 3 disorders with pilonidal sinus has been called the follicular occlusion tetrad.¹¹

The association of hidradenitis suppurativa with Crohn disease is well known and occasionally leads to difficulty in differentiating the lesions corresponding to each disease.

Hidradenitis suppurativa has also been associated with congenital α 1-antitrypsin deficiency.

Diagnosis

Clinical Diagnosis

The diagnosis of hidradenitis suppurativa is primarily clinical. There is no specific diagnostic test¹² or pathognomonic lesion, making it difficult to establish a definition for the disease. The diagnostic criteria are broad and typically include scarring, the recurrent nature of the disease, and the multifocal presentation affecting the axillae, submammary region, and groin.¹³ However, hidradenitis suppurativa can present on practically any part of the body surface. Hurley¹⁴ proposed a classification in which he described the clinical course of the disease from localized inflammatory forms to fulminant disease (Table 2). This classification is not widely used in clinical practice, though the majority of cases usually correspond to category II.

The initial symptoms are generally nonspecific, such as pruritus, erythema, and local hyperhidrosis. Pain and induration can then develop, together with the appearance of subcutaneous nodules, which subsequently become organized into abscesses that may spontaneously drain a foul-smelling material. With each recurrence, the initial cavity usually increases in size. Finally, a network forms in which fibrotic, subcutaneous cavities are interconnected by fistulous tracts.

The main differential diagnosis must be made with Crohn disease. Perianal lesions are the form of presentation of this disease in 5% of cases. At this early stage, the 2 diseases can be clinically indistinguishable. The simultaneous presence of both diseases has sometimes been detected,¹⁵ and there are even some authors who consider that hidradenitis suppurativa is a cutaneous manifestation of Crohn disease.¹⁶

Pathologic Diagnosis

Pathologic study is not required to make the diagnosis of hidradenitis suppurativa. In early stages of the disease, spongiform inflammatory changes can be observed below the infundibulum.¹⁷ The inflammatory infiltrate is usually formed by neutrophils, lymphocytes, and histiocytes. Occlusion of the hair follicles by keratin plugs is often observed, leading to their dilatation.

In chronic disease, there is a marked inflammatory cell component in the dermis, with giant cells, sinus tracts, subcutaneous abscesses, and, ultimately, fibrosis. Fistulous tracts appear to be one of the most typical lesions in

Table 2. Hurley Stages of Hidradenitis Suppurativa

Stage	Abscesses	Fistulous Tracts/Scarring
I	1 or more	No
II	Widely separated and recurrent	Limited disease
III	Multiple	Multiple

Adapted from Hurley¹⁴.

hidradenitis suppurativa. Granulomatous lesions, more typical of Crohn disease, may also occasionally be found in hidradenitis suppurativa, making the differential diagnosis between the 2 conditions difficult.

Complications

1. Contractures and reduced mobility of the lower limbs and axillae due to fibrosis and scarring. Severe lymphedema may develop in the lower limbs.
2. Local and systemic infections (meningitis, bronchitis, pneumonia, etc), which may even progress to sepsis.
3. Interstitial keratitis
4. Anal, rectal, or urethral fistulas in anogenital hidradenitis suppurativa¹⁸
5. Normochromic or hypochromic anemia¹⁹
6. Squamous cell carcinoma: this has been found on rare occasions in chronic hidradenitis suppurativa of the anogenital region.²⁰ The mean time to the onset of this type of lesion is 10 years or more, and the tumors are usually highly aggressive.
7. Tumors of the lung and oral cavity, probably related to the high level of smoking among these patients, and liver cancer.²¹
8. Hypoproteinemia and amyloidosis, which can lead to renal failure and death.²²
9. Seronegative and usually asymmetric arthropathy: pauciarticular arthritis, polyarthritis/polyarthralgia syndrome.²³

Therapeutic Management

The therapeutic management of hidradenitis suppurativa must be adapted to the severity and distribution of the disease. One of the fundamental aims is to improve the patient's quality of life. There is little evidence for the efficacy of the different treatments in randomized clinical trials or after long-term follow-up.¹ Complete resolution of the condition is impossible in severe disease, and spontaneous resolution is rare.

Table 3. Levels of Evidence Referred to in this Article

Level 1	Randomized clinical trial
Level 2	Nonrandomized clinical trial or case series
Level 3	Case reports
Level 4	Expert opinion
Level 5	No evidence level

The different evidence levels are shown in Table 3. In this respect, an evidence level of 3 (case reports) is inferred unless otherwise specified. The treatment algorithm for hidradenitis suppurativa is presented in the figure and the different therapeutic approaches are listed in Table 4.

General Measures

These are principally aimed at maintaining cleanliness of the area and reducing the bacterial load. Their benefit is limited, although regular use of these measures is recommended in order to reduce associated symptoms as far as possible.

Pharmacological Treatments

Topical Treatments

One important clinical trial of the few that have been performed on the treatment of hidradenitis suppurativa was a double-blind study involving 46 patients, comparing

topical clindamycin with systemic tetracyclines, finding no significant differences between them.²⁴ Another double-blind clinical trial with 30 patients is also notable.²⁵ Those patients were treated with topical clindamycin or placebo, with positive results in favor of the active medication for effectiveness and efficacy profile.

Intralesional Treatments

The most widely used treatments are intralesional corticosteroids, which can achieve a benefit, although this is usually transitory.

Systemic Treatments

Retinoids. Treatment with isotretinoin can be administered for weeks or months before performing surgical intervention. There are no standardized treatment regimens with isotretinoin for hidradenitis suppurativa but, in general, the same regimens can be used as in acne vulgaris, although this agent is less effective in hidradenitis suppurativa. Etretinate and acitretin are generally considered to be more effective treatments than isotretinoin.

Antibiotics. Treatment with antibiotics is one of the most widely used. However, long-term suppressive treatment with antibiotics has not been shown to modify the underlying process of hidradenitis suppurativa.⁵⁰ An outbreak is practically inevitable when the antibiotic is withdrawn. Although antibiotics are not curative, they can reduce the secretions, odor, and pain. Treatment with clindamycin has been used extensively as it reduces the surgical risk if administered before the operation.

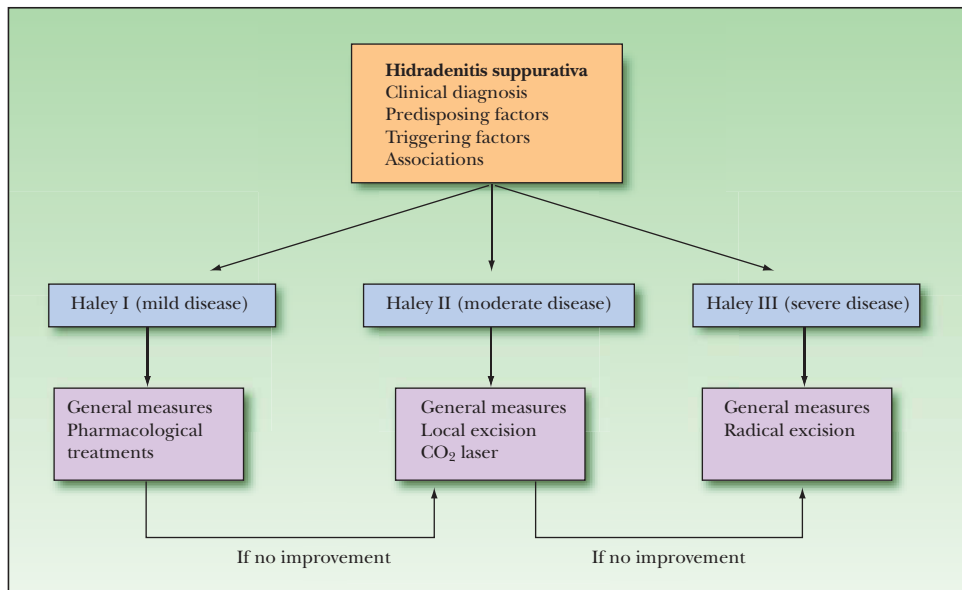


Figure. Therapeutic management of hidradenitis suppurativa.

Hormone therapy. Another treatment option is the use of cyproterone acetate associated with ethinyl estradiol, which has led to remissions of 2 months but with early recurrence on reducing the dose of the medication.⁵¹ Treatment with

finasteride is only effective in a small percentage of patients, while it is totally ineffective in others. The combination of antiandrogens and antibiotics has occasionally been found to be beneficial in the management of this disease.⁵²

Table 4. Treatment Regimens for Hidradenitis Suppurativa^a

Intervention	Treatment	Regimen	Comments		
General measures	Avoid triggering factors: lose weight, stop smoking, and avoid tight clothing, deodorants, and depilation products	Regular use	Regular use		
	Antiseptic soaps, aluminum chloride				
	Compresses, nonspecific creams				
	Warm baths, hydrotherapy				
Pharmacological	Topical	Clindamycin (evidence level 1) ^{24,25}	1% Clindamycin phosphate every 12 h	Variable results	
		Corticosteroids (evidence level 4)		Mild improvement	
		Retinoids (evidence level 4)		Mild improvement	
	Intralesional	Corticosteroids (triamcinolone acetonide suspension, prednisolone) (evidence level 4)		Mild improvement	
		Retinoids	Isotretinoin ²⁶	1 mg/kg/d	Variable results
	Acitretin/etretinate ²⁷		0.5 mg/kg/d	Effective	
	Antibiotics Tetracyclines (evidence level 1) ²⁴			500 mg/12 h	No improvement
			Clindamycin	300 mg/12 h	Recurrence on stopping treatment ²⁸
	Other antibiotics (minocycline, metronidazole, erythromycin, ciprofloxacin)		Usual doses	Depending on the microorganism cultured	
	Systemic	Hormone therapy	Cyproterone acetate + ethinyl estradiol (women) (evidence level 1) ²⁹	50 µg ethinyl estradiol (days 5-25) + 100 mg cyproterone acetate (days 5-14)	Effective
			Finasteride ³⁰	5 mg/d	Effective
		Immunosuppressants	Corticosteroids	Prednisolone 60 mg/d	Improvement in acute attack
			Cyclosporine ³¹	3-6 mg/kg/d	Effective
Azathioprine			2.5 mg/kg/d	Mild improvement	
Methotrexate ³²			12.5-15 mg/wk	Poor results	
Infliximab ^{33,34}			5 mg/kg by IV infusion	Variable results	
Etanercept ³⁵			25 mg 2 times/wk SC	Good results	
Others	Dapsone ³⁶	50-150 mg/d	Good results		
Cimetidine (evidence level 4) ¹²		No published studies			

(Continued)

Table 4. Treatment Regimens for Hidradenitis Suppurativa (Continued)^a

Intervention	Treatment	Regimen	Comments
Surgical	Incision and drainage ³⁷		Low morbidity. High recurrence
	Local excision + primary closure ³⁸		Low morbidity. High recurrence
	Incision of the sinus tracts by tissue planes, curettage, and electrocoagulation + second-intention healing ³⁹		Recurrence common ³⁸
	Radical excision + second-intention healing with Silastic foam dressings (evidence level 1) ⁴⁰		Good results, esthetic
	Radical excision + second-intention healing with negative pressure dressings ⁴¹		Better results in axillae and after graft placement
	Radical excision + flap ⁴²		Local, fasciocutaneous, musculocutaneous, pediculated, or free flap
	Radical excision + skin graft		Immediate or delayed grafting
Other forms of treatment	CO ₂ laser + second-intention healing ⁴³		Little scarring and relatively painless
	Smoothbeam laser (1450 nm diode laser) ⁴⁴		Improves sweating
	Radiation therapy ⁴⁵	Dose/session: 4-5 Gy Total dose: 1.5-18 Gy	Effective
	Cryotherapy ⁴⁶		Single case
	Leuprolide (gonadotropin releasing hormone agonist) + hysterosalpingo-oophorectomy ⁴⁷	0.21 mg/8 h	Single case
	Dexamethasone + leuprolide ⁴⁸	Dexamethasone 2.5 mg/6 h Leuprolide 1 mg/d SC	Isolated cases
	Corticotropin (evidence level 4) ⁴⁹		Single case

Abbreviations: IV, intravenous; SC, subcutaneous.

^aWhen the evidence level is not indicated, evidence level 3 (case reports) is assumed.

Immunosuppressants. Systemic corticosteroid treatment is usually very effective, though the benefits tend to be transitory. Articles published to date on the treatment of this disease with cyclosporine show good results with doses between 3 and 6 mg/kg/d.⁵³ The problem with cyclosporine is that it has potential long-term adverse effects. The results published with azathioprine are not so good.

There is an ever greater number of case reports of hidradenitis suppurativa that has been treated with anti-tumor necrosis factor α agents, such as infliximab^{33,54,55} and etanercept.³⁵ The results with infliximab have been variable.³⁴ Cases have been published in which there have been spectacular improvements that could have been due to the association of hidradenitis suppurativa with Crohn disease (this disease does

respond very well to infliximab) or to the combination of infliximab with other drugs. However, cases have been reported recently in which this improvement has not been as pronounced as was initially thought.^{54,55} All published cases of hidradenitis suppurativa treated with etanercept have shown a greater or lesser degree of improvement.³⁵

Other treatments. There are no studies published on the use of cimetidine, only occasional comments in some articles, but it is thought that it may be effective due to its antiandrogenic effects. In our experience, we have found that the combination of corticosteroids and tetracyclines in the acute outbreak can improve the symptoms in patients with hidradenitis suppurativa.

Surgical Treatment

There are practically no randomized clinical trials on the surgical treatment of hidradenitis suppurativa. Nor is there evidence that any other treatment apart from surgery can modify the underlying process in severe hidradenitis suppurativa. A number of factors must be considered before undertaking surgical treatment, such as the areas affected, the extension of the disease, and whether the patient is in an acute or chronic phase of the disease. Appropriate antibiotic cover must always be given, and this will depend on the operation to be performed. In order to avoid subsequent infection, some authors propose performing a colostomy when the perianal region is to be operated.

Surgical treatment must be carefully planned in order to prevent recurrence. It is very important to take into account the resection margins, as these will determine the rate of recurrence. Despite this, recurrence can occur at a site distant to the apocrine areas operated. Recurrence rates after surgery are usually lower in the perianal and axillary regions than in the inguinal and perineal or submammary regions.⁵⁶ Surgery with radical excision may constitute the only therapeutic option for severe disease.³⁸ In the largest study on the surgical management of hidradenitis suppurativa, 118 radical excisions were performed on 82 patients, with the following recurrence rates: axillary, 3%; perianal, 0%; inguinal and perineal, 37%; and submammary, 50%.⁵⁶ In that study, recurrence occurred between 3 and 72 months after the operation. Surgical excision is therefore not recommended in the submammary region due to the high rate of recurrence. Factors that can increase the rate of recurrence after surgery are obesity, inadequate resection, and severe maceration and chronic infection of the skin.

Comparison between the different surgical treatments is complicated due to the many techniques used in the different surgical procedures.

Local Excision and Drainage

Local excision and drainage was one of the most widely used operations in the past, but it has now been seen that although it controls the acute symptoms and causes little morbidity, there is a high recurrence rate.

Limited Local Excision

Limited local excision has similar advantages and disadvantages to local excision and drainage.

Radical Excision

When performing radical excision, it must be realized that it is important to evaluate not only the area of skin excised

but also the depth. Resection of approximately 1 to 2 cm around the affected area is recommended. Excision of the subcutaneous cellular tissue down to the muscle fascia is also recommended, or to a depth of at least 5 mm of fat, in order to ensure excision of the deep ducts of the apocrine glands.⁵⁷

In a study by Ritz et al,⁵⁸ with a mean follow-up of 72 months, different recurrence rates were observed depending on the operation performed: 100% after incision and drainage, with a mean time to recurrence of 3 months after the operation; 42.8% after local excision, with a mean of 11 months to recurrence; and 27% after radical excision, with a mean of 20 months to recurrence.

Radical excision of the tissue is usually easier and achieves better results if the fistulous tracts are marked (for example, with 3 to 5 mL of 1% methylene violet solution).

Grafts

It is preferable to delay graft placement until after a period of healing by second intention, as it has been shown that immediate grafting has a higher probability of partial loss of the graft. Immediate grafting of the perineal region is not recommended as there is a high probability of infection and loss of the graft.⁵⁹ Grafts are also not recommended in the anal canal as they can lead to stenosis.

Flaps

The use of flaps permits a rapid recovery of the wounds, with an early return to daily activities. However, this involves a longer hospital stay, greater blood loss, pain, potential loss of the flap due to infection, and recurrence of the disease beneath the flap. Better functional results are usually achieved if healing occurs by second intention. Rotation flaps have usually been used in the inguinal and genital region.

If the affected area cannot be completely excised, the use of musculocutaneous flaps rather than grafts is recommended due to their easier handling in the case of recurrence.⁶⁰ It is advisable to use flaps and grafts for chronic cases with multiple recurrences and to refer such cases to units specialized in these procedures.

Second-Intention Healing

This is considered to be the treatment of choice on many occasions, and may be followed by free skin grafting. Second-intention healing favors a shorter hospital admission, avoids pain in a donor area (in the case of grafts or flaps), and reduces morbidity. However, complete recovery can occasionally take months. Second-intention healing is favored in treatment of the perineal region.⁶¹ Very good esthetic results have been observed

after second-intention healing with silastic foam dressings.⁴⁰

Other Forms of Treatment

Carbon Dioxide Laser and Smoothbeam Laser

Improvements can be observed within 4 to 8 weeks after carbon dioxide laser treatment, and this usually only requires a maximum hospital stay of 1 night. The advantage of this treatment with respect to surgery is that it achieves better hemostasis, better visualization, and, thus, better excision of the affected tissue. After laser therapy, healing is usually allowed to occur by second intention.⁴³ It has also been seen that the Smoothbeam laser (a 1450 nm diode laser) may be partially effective in reducing symptoms when used in the axillae, and principally in reducing sweating associated with the condition.⁴⁴

Radiation Therapy

In the study by Frohlich et al,⁴⁵ complete symptomatic improvement was observed in 38% of patients and a clear improvement in a further 40%. Radiation therapy can cause the additional problem of poor tissue healing.

Cryotherapy

Treatment with cryotherapy often causes pain during the procedure and is usually associated with a long healing period; however, it may be considered an option in localized disease.⁴⁶

Conclusions

Hidradenitis suppurativa is a debilitating disease and is poorly understood. When diagnosing this disease, we must always consider the predisposing factors, triggering factors, and possible associations.

It is important to treat this disease, as it can present serious complications in the long term. There is no standardized treatment regimen, meaning that there is no truly effective treatment. The management of chronic, abscessed lesions constitutes the key to the treatment of this condition. Once established, this type of lesion can only be eliminated by surgery.

The principal recommendations for successful management of hidradenitis suppurativa are an early diagnosis, medical control of the disease prior to considering surgery, and, if surgery is considered as a final resort, appropriate surgical planning. As hidradenitis suppurativa is a chronic, recurrent disease, the patient's satisfaction with any therapeutic modality is important. There are no data

on patient satisfaction after medical treatment but, in general, it has been found that surgery does improve patient satisfaction.

Conflicts of Interest

The authors declare no conflicts of interest.

References

1. Slade DEM, Powell BW, Mortimer PS. Hidradenitis suppurativa: pathogenesis and management. *Br J Plast Surg*. 2003;56:451-61.
2. Jemec GBE, Heidenheim M, Nielsen NH. The prevalence of hidradenitis suppurativa and its potential precursor lesions. *J Am Acad Dermatol*. 1996;35:191-4.
3. Wolkenstein P, Loundon A, Barrau K, Auquier P, Revuz J. Quality of Life Group of the French Society of Dermatology. *J Am Acad Dermatol*. 2007;56:621-3.
4. Jemec GBE. Body weight in hidradenitis suppurativa. In: Marks R, Plewig G, editors. *Acne and Related disorders*. London: Martin Dunitz; 1989. p. 375-6.
5. Der Werth JM, Williams HC, Raeburn JA. The clinical genetics of hidradenitis suppurativa revisited. *Br J Dermatol*. 2000;142:947-53.
6. Barth JH, Kealey T. Androgen metabolism by isolated human axillary apocrine glands in hidradenitis suppurativa. *Br J Dermatol*. 1991;125:304-8.
7. Koning A, Lehmann C, Rompel R, Happle R. Cigarette smoking as a triggering factor of hidradenitis suppurativa. *Dermatology*. 1999;198:261-4.
8. Morgan WP, Leicester G. The role of depilation and deodorants in hidradenitis suppurativa. *Br J Surg*. 1979;66:853-6.
9. Stellan AJ, Wakeling M. Hidradenitis suppurativa associated with use of oral contraceptives. *Br Med J*. 1989;298:28-9.
10. Gupta AK, Knowles SR, Gupta MA, Jaunkalns R, Shear NH. Lithium therapy associated with hidradenitis suppurativa: case report and a review of the dermatologic side effects of lithium. *J Am Acad Dermatol*. 1995;32:382-6.
11. Plewig G, Kligman A. *Acne, morphogenesis and treatment*. Berlin: Springer; 1975. p. 192.
12. Mortimer PS, Lunniss PJ. Hidradenitis suppurativa. *J R Soc Med*. 2000;93:420-2.
13. Highet AS, Hay RJ, Roberts SOB. Bacterial infections. In: Champion RH, Burton JL, Ebling FJG, editors. *Textbook of dermatology*. 5th ed. Oxford: Blackwell Scientific Publications; 1990. p. 953-1031.
14. Hurley HJ. Axillary hyperhidrosis, apocrine bromhidrosis, hidradenitis suppurativa, and familial benign pemphigus: Surgical approach. In: Roenigk RK, Roenigk HHJ, editors. *Dermatologic surgery. Principles and practice*. New York: Marcel Dekker; 1989. p. 717-43.
15. Church JM, Fazio VW, Lavery IC, Oakley JR, Milsom JW. The differential diagnosis and comorbidity of hidradenitis suppurativa and perianal Crohn's disease. *Int J Colorectal Dis*. 1993;8:117-9.
16. Tsianos EV, Dalekos GN, Tzermias C, Merkouropoulos M, Hatzis J. Hidradenitis suppurativa in Crohn's disease. *A*

- further support to this association. *J Clin Gastroenterol.* 1995;20:151-3.
17. Boer J, Weltevreden EF. Hidradenitis suppurativa or acne inversa. A clinicopathological study of early lesions. *Br J Dermatol.* 1996;135:721-5.
 18. Hurley HJJ. Apocrine glands. New York: McGraw Hill; 1979.
 19. Tennant F Jr, Bergeron JR, Stone OJ, Mullins JF. Anemia associated with hidradenitis suppurativa. *Arch Dermatol.* 1968;98:138-40.
 20. Williams ST, Busby RC, DeMuth RJ, Nelson H. Perineal hidradenitis suppurativa: presentation of two unusual complications and a review. *Ann Plast Surg.* 1991;26:456-62.
 21. Lapins J, Ye W, Nyren O, Emtestam L. Incidence of cancer among patients with hidradenitis suppurativa. *Arch Dermatol.* 2001;137:730-4.
 22. Moschella SL. Hidradenitis suppurativa. Complications resulting in death. *JAMA.* 1966;198:201-3.
 23. Vasey FB, Fenske NA, Clement GB, Bridgeford PH, Germain BF, Espinoza LR. Immunological studies of the arthritis of acne conglobata and hidradenitis suppurativa. *Clin Exp Rheumatol.* 1984;2:309-11.
 24. Jemec GBE, Wenelboe P. Topical clindamycin versus systemic tetracycline in the treatment of hidradenitis suppurativa. *J Am Acad Dermatol.* 1998;39:971-4.
 25. Clemmensen OJ. Topical treatment of hidradenitis suppurativa with clindamycin. *Int J Dermatol.* 1983;22:325-8.
 26. Boer J, Mirjan JP, Gemert V. Long-term results of isotretinoin in the treatment of 68 patients with hidradenitis suppurativa. *J Am Acad Dermatol.* 1999;40:73-6.
 27. Chow ETY, Mortimer PS. Successful treatment of hidradenitis suppurativa and retroauricular acne with tretinoin. *Br J Dermatol.* 1992;126:415.
 28. Banerjee AK. Surgical treatment of hidradenitis suppurativa. *Br J Surg.* 1992;79:863-6.
 29. Mortimer PS, Dawber RPR, Gales MA, Moore RA. A double-blind cross-over trial of cyproterone acetate in females with hidradenitis suppurativa. *Br J Dermatol.* 1986;115:263-8.
 30. Farrell AM, Randall VA, Vafae T, Dawber RP. Finasteride as a therapy for hidradenitis suppurativa. *Br J Dermatol.* 1999;141:1138-9.
 31. Buckley DA, Rogers S. Cyclosporin-responsive hidradenitis suppurativa. *J R Soc Med.* 1995;88:289-90.
 32. Jemec GBE. Methotrexate is of limited value in the treatment of hidradenitis suppurativa. *Clin Exp Dermatol.* 2002;27:528-9.
 33. Sullivan TP, Welsh E, Kerdel FA, Burdick AE, Kirsner RS. Infliximab for hidradenitis suppurativa. *Br J Dermatol.* 2003;149:1046-9.
 34. Pedraz J, Daudén E, Pérez-Gala S, Goiriz-Valdés R, Fernández-Peñas P, García-Díez A. Hidrosadenitis suppurativa tratada con infliximab. *Actas Dermosifiliogr.* 2007;98: 325-31.
 35. Cusack C, Buckley C. Etanercept: effective in the management of hidradenitis suppurativa. *Br J Dermatol.* 2006;154:726-9.
 36. Kaur MR, Lewis HM. Hidradenitis suppurativa treated with dapsone: A case series of five patients. *J Dermatolog Treat.* 2006;17:211-3.
 37. Vickers MA. Operative management of hidradenitis suppurativa of the scrotum and perineum. *J Urol.* 1975; 114:414-6.
 38. Jemec GBE. Effect of localized surgical excisions in hidradenitis suppurativa. *J Am Acad Dermatol.* 1988;18:1103-7.
 39. Brown SC, Kazzazi N, Lord PH. Surgical treatment of perineal hidradenitis suppurativa: with special reference to recognition of the perianal form. *Br J Surg.* 1986;73:978-80.
 40. Morgan WP, Harding KG, Hughes LE. A comparison of skin grafting and healing by granulation, following axillary excision for hidradenitis suppurativa. *Ann R Coll Surg Engl.* 1983;65:235-6.
 41. Elwood ET, Bolitho DG. Negative-pressure dressings in the treatment of hidradenitis suppurativa. *Ann Plast Surg.* 2001; 46:49-51.
 42. Soldin MG, Tulley P, Kaplan H, Hudson DA, Grobelaar AO. Chronic axillary hidradenitis – the efficacy of wide excision and flap coverage. *Br J Plast Surg.* 2000;53:434-6.
 43. Finley EM, Ratz JL. Treatment of hidradenitis suppurativa with carbon dioxide laser excision and second intention healing. *J Am Acad Dermatol.* 1996;34:465-9.
 44. Downs A. Smoothbeam laser treatment may help improve hidradenitis suppurativa but not Hailey-Hailey disease. *J Cosmet Laser Ther.* 2004;6:163-4.
 45. Frohlich D, Baaske D, Glatzel M. Radiotherapy of hidradenitis suppurativa – still valid today? *Strahlenther Onkol.* 2000;176:286-9.
 46. Bong JL, Shalders K, Saihan E. Treatment of persistent painful nodules of hidradenitis suppurativa with cryotherapy. *Clin Exp Dermatol.* 2003;28:241-4.
 47. Bogers JW, Minderhoud Bassie W, Hiukeshoven FJ. A case of hidradenitis suppurativa treated with gonadotropin-releasing hormone agonist and by total abdominal hysterectomy with bilateral salpingo-oophorectomy. *Am J Obstet Gynecol.* 1992;167:517-8.
 48. Camisa C, Sexton C, Friedman C. Treatment of hidradenitis suppurativa with combination hypothalamic-pituitary-ovarian and adrenal suppression. A case report. *J Reprod Med.* 1989; 34:543-6.
 49. Kipping HF. How I treat hidradenitis suppurativa. *Postgrad Med.* 1970;48:291-2.
 50. Harrison BJ, Kumar S, Read GF, Edwards CA, Scanlon MF, Hughes LE. Hidradenitis suppurativa: evidence for an endocrine abnormality. *Br J Surg.* 1985;72:1002-4.
 51. Sawers RS, Randall VA, Ebling FJ. Control of hidradenitis suppurativa in women using combined antiandrogen and oestrogen therapy. *Br J Dermatol.* 1986;115:269-74.
 52. Goldsmith PC, Dowd PM. Successful therapy of the follicular occlusion triad in a young woman with high dose oral antiandrogens and minocycline. *J R Soc Med.* 1993;86:729-30.
 53. Rose RF, Goodfield MJ, Clark SM. Treatment of recalcitrant hidradenitis suppurativa with oral cyclosporin. *Clin Exp Dermatol.* 2006;31:154-5.
 54. Usmani N, Clayton TH, Everett S, Goodfield MD. Variable response of hidradenitis suppurativa to infliximab in four patients. *Clin Exp Dermatol.* 2007;32:204-5.
 55. Fardet L, Dupuy A, Kerob D, Levy A, Allez M, Begon E, et al. Infliximab for severe hidradenitis suppurativa: transient clinical efficacy in 7 consecutive patients. *J Am Acad Dermatol.* 2007;56:624-8.

56. Harrison BJ, Mudge M, Hughes LE. Recurrence after surgical treatment of hidradenitis suppurativa. *Br Med J (Clin Res Ed)*. 1987;294:487-9.
57. Parks RW, Parks TG. Pathogenesis, clinical features and management of hidradenitis suppurativa. *Ann R Coll Surg Engl*. 1997;79:83-9.
58. Ritz JP, Runkel N, Haier J, Buhr HJ. Extent of surgery and recurrence rate of hidradenitis suppurativa. *Int J Colorectal Dis*. 1998;13:164-8. 59.
59. Knaysi GA Jr, Cosman B, Crikelair GF. Hidradenitis suppurativa. *JAMA*. 1968;203:19-22.
60. Tanaka A, Hatoko M, Tada H, Kuwahara M, Mashiba K, Yurugi S. Experience with surgical treatment of hidradenitis suppurativa. *Ann Plast Surg*. 2001;47:636-42.
61. Bailey HR, Snyder MJ. Operative management of hidradenitis suppurativa. *Op Tech Gen Surg*. 2001;3:117-23.