

CASE REPORT

Perifollicular Xanthomatosis as a Key Histological Finding in Fox–Fordyce Disease

J Mataix,^a JF Silvestre,^a M Niveiro,^b A Lucas,^a and M Pérez-Crespo^a

^aServicio de Dermatología and ^bAnatomía Patológica, Hospital General Universitario de Alicante, Alicante, Spain

Abstract. Fox–Fordyce disease is a rare skin condition characterized by the presence of multiple pruritic follicular papules in areas rich in apocrine glands, such as the axillae, mammary areolae, or genital regions. There is a high degree of variability in the histological findings seen in Fox–Fordyce disease. In addition to those described as typical of this entity, such as dilation of the infundibulum and hyperkeratosis and spongiosis of the infundibular epithelium, many other histological changes can be observed. We report the case of a 21-year-old woman with Fox–Fordyce disease and highlight the importance of perifollicular xanthomatosis as a key histological finding in the diagnosis of the disease.

Key words: Fox–Fordyce disease, apocrine miliaria, perifollicular xanthomatosis.

XANTOMATOSIS PERIFOLICULAR: HALLAZGO HISTOLÓGICO CLAVE EN LA ENFERMEDAD DE FOX-FORDYCE

Resumen. La enfermedad de Fox–Fordyce es una rara dermatosis caracterizada por la presencia de múltiples pápulas foliculares pruriginosas en áreas corporales con riqueza de glándulas apocrinas como axilas, areolas mamarias o región genital. Los hallazgos histopatológicos que definen la enfermedad de Fox–Fordyce son muy variados. Además de los hallazgos descritos como típicos de esta entidad, como la dilatación del infundíbulo y la hiperqueratosis y espongiosis del epitelio infundibular, se pueden observar otros muchos hallazgos histológicos. Presentamos el caso de una mujer de 21 años de edad afectada por esta enfermedad y recalcamos la importancia de la xantomatosis perinfundibular como hallazgo histológico clave en el diagnóstico de esta entidad.

Palabras clave: enfermedad de Fox–Fordyce, miliaria apocrina, xantomatosis perifollicular.

Introduction

Fox–Fordyce disease was first described by Dr George Henry Fox and Dr John Addison Fordyce in 1902.¹ In 1956 Shelley and Levy² proposed the term *apocrine miliaria* to describe this entity.

Fox–Fordyce disease is a rare skin condition, with 90% of cases involving women between age 13 and 35. The symptoms are highly suggestive and characterized by the presence of numerous whitish–yellow follicular papules distributed symmetrically over both axillae and, on occasions, in other areas rich in sebaceous glands, such as the periareolar

skin or the genital area. The lesions tend to be pruriginous, a symptom that worsens during the summer months or during times of emotional stress.³

We describe the case of a woman with this rare disease and discuss the variety of histological observations reported in the literature. We also highlight the importance of perifollicular xanthomatosis as a key histological finding in the diagnosis of this entity.

Case Description

A 21-year-old woman consulted for the presence of cutaneous lesions in both axillae that had appeared 5 years earlier. The patient reported that at the time of the consultation, the lesions were asymptomatic, but that they had been extremely and continuously itchy during the hottest months of the year. The patient had no relevant personal or family history and was not using any medications on a regular basis.

Correspondence:
Javier Mataix
Servicio de Dermatología
Hospital General Universitario
Avda. Pintor Baeza s/n
03010 Alicante, Spain
mataixdiaz@hotmail.com

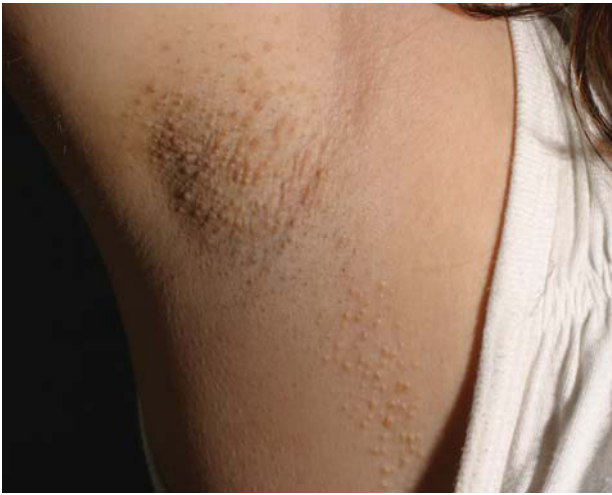

Figure 1. Multiple whitish-yellow follicular papules in the axillary region.

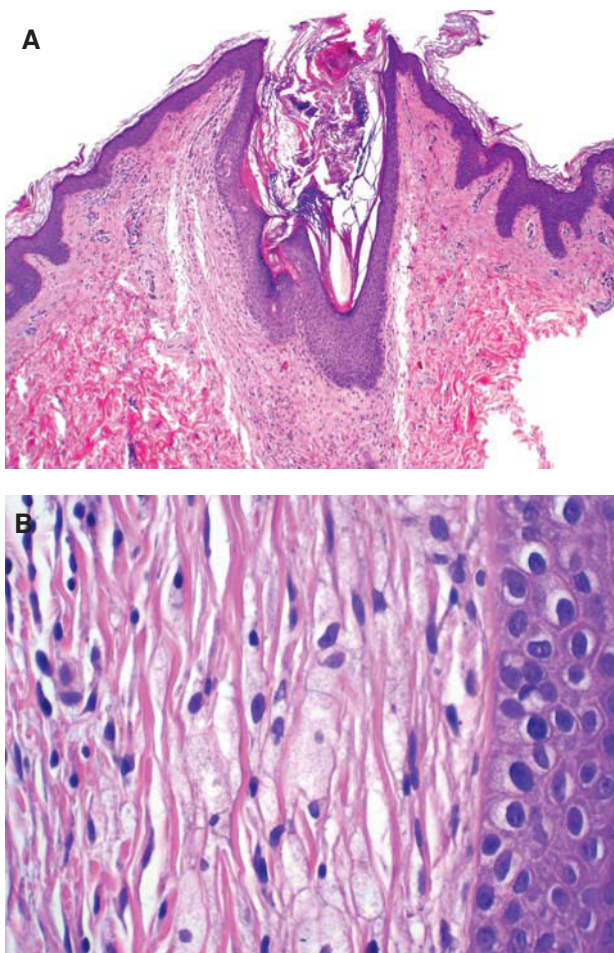


Figure 2. (A) Dilatation and hyperkeratosis in the follicular infundibulum along with perifollicular infiltrate of xanthomatous macrophages. (Hematoxylin-eosin, $\times 40$.) (B) Detailed view of the perifollicular infiltrate. (Hematoxylin-eosin, $\times 200$.)

The physical examination showed whitish-yellow follicular papules that were distributed symmetrically over both axillae (Figure 1). Histological study of one of these papules revealed the presence of dilatation and hyperkeratosis of the follicular infundibulum along with a periadnexal lymphocytic inflammatory infiltrate (Figure 2A). Moreover, abundant xanthomatous macrophages were found in the dermis around the follicular infundibulum (Figure 2B). Other tests revealed no hormonal or metabolic abnormalities of interest.

A decision was made to start topical treatment with pimecrolimus (2 applications per day). No response was obtained after 3 months of continuous treatment, and therefore, it was discontinued. Because the patient refused any other more aggressive intervention, a wait-and-see approach was taken and oral antihistamines were prescribed in case of pruritus.

Discussion

The histopathological findings that define Fox–Fordyce disease are extremely varied. Despite this wide variety, however, the clinical presentation is always similar. The most common microscopic findings are dilatation and hyperkeratosis of the follicular infundibulum. There are additional histological findings that appear less often; for instance, spongiosis and dyskeratosis of the infundibular epithelium, vacuolar degeneration of the dermoepidermal junction, or periadnexal lymphocytic inflammatory infiltrate. The presence of parakeratosis in the infundibular epithelium in the form of cornoid lamellae has also been described as characteristic of Fox–Fordyce disease, although this is observed less consistently. In 2004 Kossard and Dwyer⁴ reported a patient with lesions indistinguishable from Fox–Fordyce disease for which they proposed the term *axillary perifollicular xanthomatosis*. The authors excluded the diagnosis of Fox–Fordyce disease in their patient based on the following: (1) absence of intense pruritus, (2) confinement of the lesions to the axillae, (3) absence of other histological findings typical of Fox–Fordyce disease, and (4) presence of a noticeable infiltrate of xanthomatous macrophages around the follicular infundibulum. In an excellent review published later, Böer⁵ considered the presence of this xanthomatous infiltrate in the perifollicular dermis as a typical finding of Fox–Fordyce disease. Additionally, Bormate et al⁶ studied the histological findings of 6 patients with Fox–Fordyce disease and considered this histological criterion to be of crucial importance in the diagnosis of this entity. This histological finding is accompanied by clinical symptoms in which the presence of these foamy macrophages in the perifollicular dermis contributes to elevation of the

lesions and gives them a characteristic yellowish tone.⁵ Thus, axillary perifollicular xanthomatosis should not be considered an isolated entity, but an important diagnostic clue within the broad spectrum of histological findings of Fox–Fordyce disease.

Although the term apocrine miliaria has been widely used in most scientific texts, certain authors such as Ackerman^{7,8} or Boer⁵ have criticized its use as inappropriate. In those authors' opinion, there are enough clinical and histological differences for Fox–Fordyce disease not to be considered analogous to miliaria crystallina with acrosyringium involvement. In eccrine miliaria, the key histological finding is the presence of a sweat-retention vesicle immediately below the obstruction level for each subtype: the stratum corneum in miliaria crystallina, the stratum spinosum in miliaria rubra, and the dermoepidermal junction in miliaria profunda. Nevertheless, the presence of spongiform dermatitis or a genuine sweat-retention vesicle in the intraepidermal follicular infundibulum is not always a histological finding in Fox–Fordyce disease. Therefore, its absence does not preclude diagnosis since the spectrum of histological findings in this disease is much broader.

The exact pathophysiological mechanism is unknown. The theory most widely accepted at present proposes that the underlying cause of the disease is mechanical obstruction by a hyperkeratotic plug in the portion of the follicular infundibulum close to where the apocrine duct opens.^{2,3,9,10} It has been postulated that this obstruction would lead to the retention and subsequent extravasation of a lipid-rich material in the intraepidermal follicular infundibulum and the perifollicular dermis. This apocrine material would be subsequently phagocytosed by macrophages, which would then acquire the xanthomatous appearance characteristic of the condition.⁵ However, it does not seem appropriate to consider Fox–Fordyce disease a merely mechanical problem. It has been suggested that certain hormonal factors influence its onset, because cases have been reported of total or partial remission during pregnancy, menopause, or after the use of hormonal contraceptives¹¹ and also because it rarely appears before puberty. Nevertheless, no hormone abnormality has been demonstrated in patients affected by Fox–Fordyce disease^{12,13} or in rare cases of patients who develop the disease before puberty.¹⁴ Lastly, the existence of family cases supports the theory of an underlying genetic predisposition.¹⁵

In general, the treatment of Fox–Fordyce disease is rather unsatisfactory. Because the condition is rare, there are no controlled studies and most recommendations are based on isolated cases or small case series. Therapeutic measures include topical and intralesional corticosteroids,¹⁶ topical or systemic retinoids,^{17,18} topical antibiotics such as clindamycin,¹⁹ or oral contraceptives.¹¹

Recently, Pock et al²⁰ reported their personal experience with 3 patients with Fox–Fordyce disease who were treated with topical pimecrolimus, obtaining excellent responses in all patients within a relatively short period. Those authors proposed that the drug would act as an anti-inflammatory on the periadnexal lymphocytic infiltrate typical of Fox–Fordyce disease. In addition, Chae et al²¹ recommended the use of a modified liposuction technique for recalcitrant cases.

Conflicts of Interest

The authors declare no conflicts of interest.

References

1. Fox GH, Fordyce JA. Two cases of a rare papular disease affecting the axillary region. *J Cut Genito-Urinary Dis.* 1902;20:1-5.
2. Shelley WB, Levy EJ. Apocrine sweat retention in men. II. Fox–Fordyce disease (apocrine miliaria). *Arch Dermatol.* 1956;73:38-49.
3. Ozcan A, Senol M, Aydin NE, Karaca S, Sener S. Fox–Fordyce disease. *J Eur Acad Dermatol Venereol.* 2003;17:244-5.
4. Kossard S, Dwyer P. Axillary perifollicular xanthomatosis resembling Fox–Fordyce disease. *Australas J Dermatol.* 2004; 45:146-8.
5. Böer A. Patterns histopathologic of Fox–Fordyce disease. *Am J Dermatopathol.* 2004;26:482-92.
6. Bormate AB Jr, McCalmont TH, LeBoit PE. Perifollicular xanthomatosis is the hallmark of axillary Fox–Fordyce disease. *Am J Dermatopathol.* 2006;28:232.
7. Ackerman AB. *Resolving Quandaries in Dermatology, Pathology, and Dermatopathology.* Philadelphia: Promethean Medical Press; 1995.
8. Ackerman AB, Chongchitnant N, Sanchez J, Guo Y, Bennin B, Reichel M, et al. Histologic diagnosis of inflammatory skin diseases. An algorithmic method based on pattern analysis. 2nd ed. Baltimore: Williams & Wilkins; 1997.
9. Macmillan DC, Vickers HR. Fox–Fordyce disease. *Br J Dermatol.* 1971;84:181.
10. Kamada A, Saga K, Jimbow K. Apoeccrine sweat duct obstruction as a cause for Fox–Fordyce disease. *J Am Acad Dermatol.* 2003;48:453-5.
11. Kronthal HI, Pomeranz JR, Sitomer G. Fox–Fordyce disease. Treatment with an oral contraceptive. *Arch Dermatol.* 1965;91:243-5.
12. Turner TW. Hormonal levels in Fox–Fordyce disease. *Br J Dermatol.* 1976;94:317-8.
13. Rubio C, Mayor M, Martín MA, González-Beato MJ. Enfermedad de Fox–Fordyce. *Actas Dermosifiliogr.* 2004;95: 314-6.
14. Sandhu K, Gupta S, Kanwar AJ. Fox–Fordyce disease in a prepubertal girl. *Pediatr Dermatol.* 2005;22:89-90.
15. Graham JH, Shafer JC, Helwig EB. Fox–Fordyce disease in male identical twins. *Arch Dermatol.* 1960;82:212-21.
16. Helfman RJ. A new treatment of Fox–Fordyce disease. *South Med J.* 1962;55:681-4.

17. Giacobetti R, Caro WA, Roenigk HH Jr. Fox–Fordyce disease. Control with tretinoin cream. *Arch Dermatol.* 1979;115:1365-6.
18. Effendy I, Ossowski B, Happle R. Fox–Fordyce disease in a male patient- response to oral retinoid treatment. *Clin Exp Dermatol.* 1994;19:67-9.
19. Feldmann R, Masouye I, Chavaz P, Saurat JH. Fox–Fordyce disease: successful treatment with topical clindamycin in alcoholic propylene glycol solution. *Dermatology.* 1992;184:310-3.
20. Pock L, Svrckova M, Machackova R, Hercogova J. Pimecrolimus is effective in Fox–Fordyce disease. *Int J Dermatol.* 2006;45:1134-5.
21. Chae KM, Marschall MA, Marschall SF. Axillary Fox–Fordyce disease treated with liposuction-assisted curettage. *Arch Dermatol.* 2002;138:452-4.