

CASE REPORTS

Lichenoid Drug Eruption Induced by Olanzapine

R. Fernández-Torres,^a M. Almagro,^a J. del Pozo,^a O. Robles,^b C. Martínez-González,^a M. Mazaira,^a and E. Fonseca^a

^aServicio de Dermatología and ^bServicio de Anatomía Patológica, Hospital Juan Canalejo, La Coruña, Spain

Abstract. Lichenoid drug eruptions can mimic idiopathic lichen planus and other dermatoses. The list of drugs that can cause them is long and growing steadily. Although cutaneous side effects of antipsychotics are rare, various cutaneous manifestations have been reported in association with olanzapine. We present the case of a patient who developed an atypical lichenoid eruption due to olanzapine. A review of the literature in Medline from 1951 to 2007 and in the Índice Médico Español (Spanish Medical Index) revealed no previous cases of lichenoid eruptions associated with the use of this drug.

Key words: olanzapine, lichenoid drug eruption, lichen planus.

ERUPCIÓN LIQUENOIDE INDUCIDA POR OLANZAPINA

Resumen. Las erupciones liquenoides inducidas por fármacos pueden simular un liquen plano idiopático y otras dermatosis. La lista de fármacos que pueden inducirlos es amplia y se incrementa constantemente.

Aunque los efectos secundarios cutáneos en relación con antipsicóticos son raros, se han descrito diversas manifestaciones cutáneas en relación con la olanzapina.

Presentamos el caso de una paciente que desarrolló una erupción liquenoide atípica debida a olanzapina. En la revisión de la literatura que hemos realizado (Medline desde 1951 hasta 2007 e Índice Médico Español) no hemos encontrado ningún caso descrito de erupción liquenoide relacionado con este fármaco.

Palabras clave: olanzapina, erupción liquenoide por fármacos, liquen plano.

Introduction

Lichen planus (LP) is a common inflammatory disease that can affect the skin, mucosa, nails, and hair. In addition to classic or idiopathic LP, lichenoid eruptions (LE) have been reported in association with systemic diseases such as graft-versus-host disease, infections such as chronic hepatitis, and exposure to exogenous compounds or drugs.

The term LE is used to designate these eruptions when they occur due to exposure to exogenous compounds, drugs, or industrial byproducts such as inhaled particles. The list of drugs that can cause LE is long and growing steadily.¹

Although adverse cutaneous reactions to antipsychotic agents are rare, several cutaneous effects of olanzapine treatment have been reported, such as pustular eruptions,²

purpuric skin rash,³ hypersensitivity syndrome,⁴ vasculitis,⁵ eruptive xanthomas,⁶ or skin hyperpigmentation.⁷

We present the case of a patient who developed atypical LE due to olanzapine. To our knowledge, this is the first case of LE induced by this drug.^{1,8}

Case Description

A 73-year-old woman consulted the dermatology department for extensive skin lesions with a sclerotic appearance that had developed 1 month earlier. She had a history of depression and psychotic disorder for which she was being treated with olanzapine (15 mg/d), biperiden (1 mg/d), escitalopram (20 mg/d), and dihydroergocristine-piracetam (8 mL twice daily). The patient was a nonsmoker and had begun to take olanzapine 4 months previously with no change in treatment during the intervening period.

Examination of the skin showed erythematous edematous indurated plaques with poorly defined borders on the anterior surface of the thighs and arms, with no local changes in temperature (Figure 1). The skin on the dorsal surface of the hands and feet was edematous and indurated, without

Correspondence:
Rosa Fernández-Torres
Hospital Juan Canalejo
Xubias de Arriba, 84
15006 La Coruña, Spain
rosaftorres@gmail.com

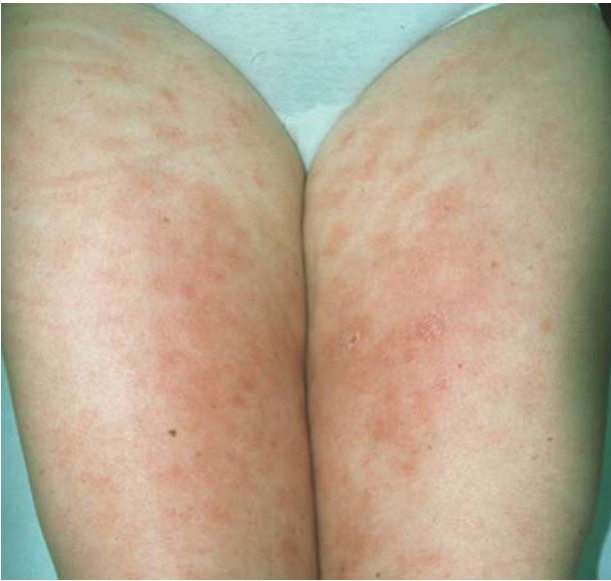

Figure 1. Erythematous edematous sclerotic areas on both legs.

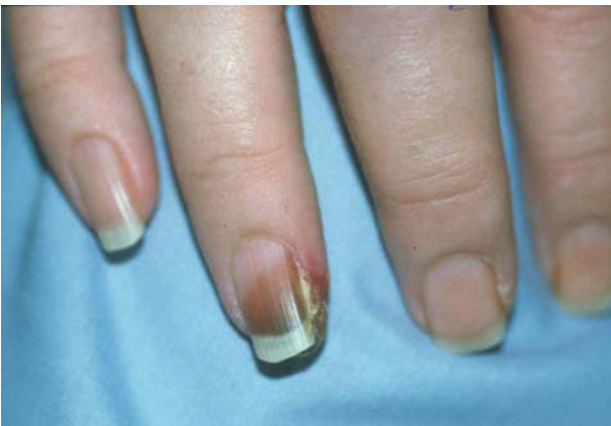

Figure 2. Necrotic lesions affecting the nailbed of the fingers.

dimpling, and had isolated erythematous or violaceous maculopapular lesions. During admission she developed focal acral necrosis with lesions suggestive of vasculitis or occlusive disease below the fingernail of the fourth finger of the right hand (Figure 2) and the first and second toe of the left foot.

Laboratory tests included analysis of muscle enzymes, cryoglobulin, antinuclear antibodies, antiphospholipid antibodies, and antiplatelet antibodies, as well as serologic tests for hepatitis B, hepatitis C, and human immunodeficiency virus, and in all cases the results were negative or within the normal range. Chest X-ray showed no pleural or pulmonary abnormalities and X-ray of the legs showed no soft-tissue calcifications.

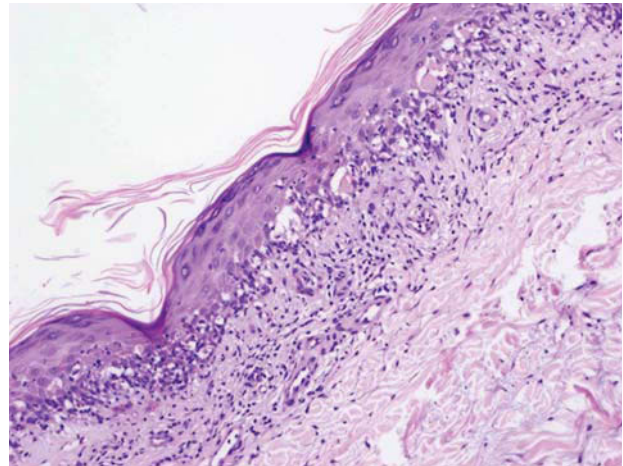


Figure 3. Hyperkeratosis with focal parakeratosis in the corneal layer, acanthosis, papillomatosis, and exocytosis of mononuclear cells. Civatte bodies are visible in the medial and lower layers of the epidermis and hydropic degeneration is seen in the basal layer. A band-like inflammatory infiltrate of mainly mononuclear cells is visible in the upper dermis. (Hematoxylin-eosin, $\times 10$.)

Skin biopsies were taken from various sites, including indurated and edematous plaques on the forearm and hand, 1 of the necrotic lesions on the fleshy part of the toe, and the residual hyperpigmented lesions on the thigh. All biopsies displayed similar histologic changes consisting of hyperkeratosis of the stratum corneum with focal parakeratosis, acanthosis, papillomatosis, and exocytosis of mononuclear cells. There were also Civatte bodies in the medial and lower layers of the epidermis and hydropic degeneration of the basal layer. No hypergranulosis was observed. A band-like inflammatory infiltrate of mainly mononuclear cells was observed in the upper dermis as well as a perivascular mononuclear infiltrate in the deep dermis, without eosinophils. The endothelium was prominent and there were no marked vasculitic changes or fibrin thrombi (Figure 3).

A week later the patient developed slightly indurated white reticular lesions on the lateral and dorsal side of the tongue that were similar in appearance to LP, and psoriasiform lesions on the palms.

On the basis of the clinical, histologic, and laboratory findings, a diagnosis of drug-induced LE was made. Residual hyperpigmented lesions were observed, mainly on the legs, after the necrotic lesions had resolved. There was modest improvement after treatment was begun with topical and systemic corticosteroids. Since olanzapine treatment had a strong temporal correlation with the onset of the cutaneous lesions it was replaced with risperidone, once the possibility of other diseases had been eliminated. The lichenoid lesions then completely disappeared in 3 weeks, although residual hyperpigmentation similar to LP remained. There were no recurrences during a 9-month follow-up period.

Discussion

Olanzapine is an atypical antipsychotic used to treat psychotic disorders, chiefly schizophrenia and bipolar disorder. It is frequently employed as it significantly improves the negative symptoms of schizophrenia and has few extrapyramidal effects compared to typical antipsychotics. Its use has also been reported in the treatment of subacute prurigo resistant to conventional therapy, especially in patients with underlying psychological disorders.⁹

Although relatively safe, the most frequent adverse effects include sedation, weight gain, and increased creatine phosphokinase and transaminase concentrations. Several cutaneous effects have been described in the literature, such as pustular eruptions, vasculitis, eruptive xanthomas, and cutaneous hyperpigmentation; however, we have not found any reports of olanzapine-induced LE. The use of gold compounds, penicillamine, antimalarial drugs, such as quinine and chloroquine, thiazide diuretics, and β -blockers have been frequently associated with LE. Other drugs that have been relatively frequently associated with LE include nonsteroidal anti-inflammatory drugs, hypolipidemic agents, phenothiazine, and several antibiotics.^{8,10,11}

It can be difficult to differentiate between LE and idiopathic LP as they have similar clinical and histologic characteristics. In our case, the condition initially had an atypical appearance suggestive of collagenosis or vasculitis, later changing to a more lichenoid appearance. Although isolated cases of vasculitis⁵ and venous thromboembolism¹² have been reported in association with olanzapine use, especially in elderly patients and patients receiving multiple drugs, in our case vasculitis or fibrin thrombi were ruled out by histology. Furthermore, the patient had bilateral edema in the arms and thighs, making a diagnosis of venous thromboembolism unlikely.

Some features can help differentiate drug-induced LE from LP. LP is characterized by violaceous polygonal papules that can coalesce into plaques, mainly on the flexor surfaces of the arms and legs, whereas in drug-induced LE the lesions are more psoriasiform and extensive, with eczema-like changes and a normally symmetrical distribution on the trunk and limbs, as observed in our patient.

Idiopathic LP normally affects the mucosa and genitals, along with the frequent observation of Wickham striae, which tend not to occur in drug-induced LE. The latter have a greater tendency to follow a photodistribution pattern and leave residual hyperpigmentation.^{8,13,14} Some histologic findings are indicative of drug-induced LE, such as the presence of eosinophils and plasma cells in the cellular infiltrate, focal parakeratosis, and perivascular dermal infiltrates.¹⁵

Most adverse drug reactions involve a latency period ranging from days to weeks from beginning treatment to symptom onset. This period tends to be longer (ranging

from months to more than a year) in LE, making it more difficult to establish a temporal association. In the present case, olanzapine had the greatest temporal association with the onset of LE (several months after beginning treatment). As the clinical and histologic findings were consistent with drug-induced LE, and given that the lichenoid lesions only resolved after replacing olanzapine with risperidone, we believe that the most probable diagnosis is olanzapine-induced LE. Using the Naranjo probability scale,¹⁶ we found a probable association between treatment with olanzapine and LE.

The patient's history, physical examination, and histologic findings can help us to differentiate drug-induced LE from other dermatoses such as idiopathic LP. The present case initially had an atypical appearance, progressing to a lichenoid pattern, and finally to postinflammatory hyperpigmentation. Although olanzapine has also been associated with anomalous cutaneous pigmentation, the risk is far less than with standard antipsychotic agents.⁷

In cases with an atypical onset and histologic findings indicative of LE, the drugs being administered should be taken into account. We believe that olanzapine should be added to the list of drugs responsible for lichenoid reactions.

Conflicts of Interest

The authors declare no conflicts of interest.

References

1. Litt JZ. Drug eruption reference manual including drug interactions. 11th ed. UK: Taylor & Francis Group; 2005. p. 378-9.
2. Adams BB, Mustasim DF. Pustular eruption induced by olanzapine, a novel antipsychotic agent. *J Am Acad Dermatol.* 1999;41:851-3.
3. Varghese ST, Balhara YP, Shyamsunder S, Mondal A. Dermatological side effects of olanzapine. *Indian J Med Sci.* 2005;59:320-1.
4. Raz A, Bergman R, Eilam O, Yungerman T, Hayek T. A case report of olanzapine-induced hypersensitivity syndrome. *Am J Med Sci.* 2001;321:156-8.
5. Duggal MK, Singh A, Arunabh, Lolis JD, Guzik HJ. Olanzapine-induced vasculitis. *Am J Geriatr Pharmacother.* 2005;3:21-4.
6. Chang HY, Ridky TW, Kimball AB, Hughes E, Oro AE. Eruptive xanthomas associated with olanzapine use. *Arch Dermatol.* 2003;139:1045-8.
7. Jhirwal OP, Parsad D, Basu D. Skin hyperpigmentation induced by olanzapine, a novel antipsychotic agent. *Int J Dermatol.* 2004;43:778-9.
8. Halevy S, Shai A. Lichenoid drug eruptions. *J Am Acad Dermatol.* 1993;29:249-55.
9. Hyun J, Gambichler T, Bader A, Altmeyer P, Kreuter A. Olanzapine therapy for subacute prurigo. *Clin Exp Dermatol.* 2006;31:464-5.

10. Fox GN, Harrell CC, Mehregan DR. Extensive lichenoid drug eruption due to glyburide: a case report and review of the literature. *Cutis*. 2005;76:41-5.
11. Pua VS, Scolyer RA, Barnetson RS. Pravastatin-induced lichenoid drug eruption. *Australas J Dermatol*. 2006;47:57-9.
12. López Jiménez L, Gallo Marín M, Cano Osuna MT, Pérez Camacho I. Enfermedad tromboembólica venosa y olanzapina. *Med Clin (Barc)*. 2006;127:599.
13. Garnis-Jones. Dermatological side effects of psychopharmacologic agents. *Dermatol Clin*. 1996;14:503-7.
14. Keough GC, Richardson TT, Grabski WJ. Pravastatin-induced lichenoid drug eruption. *Cutis*. 1998;61:98-100.
15. Oliver GF, Winkelmann RK, Muller SA. Lichenoid dermatitis: A clinicopathologic and immunopathologic review of sixty-two cases. *J Am Acad Dermatol*. 1989;21:284-92.
16. Naranjo CA, Busto U, Sellers EM, Sandor P, Ruiz I, Roberts EA. A method for estimating the probability of adverse drug reactions. *Clin Pharmacol Ther*. 1981;30:239-45.