

References

- Huang YH, Chuang YH, Kuo TT, Yang LC, Hong HS. Vulvar syringoma: a clinicopathologic and immunohistologic study of 18 patients and results of treatment. *J Am Acad Dermatol*. 2003;48:735-9.
- Tay YK, Tham SN, Teo R. Localized vulvar syringomas—an unusual cause of pruritus vulvae. *Dermatology*. 1996;192:62-3.
- Mahiques L, Martínez-Menchón T, Martínez-Aparicio A, Fortea JM. Siringomas vulvares. *Actas Dermosifiliogr*. 2004;95:397-8.
- Belardi MG, Maglione MA, Vighi S, di Paola GR. Syringoma of the vulva. A case report. *J Reprod Med*. 1994;39:957-9.
- Agrawal S, Kulshrestha R, Rijal A, Sidhu S. Localized vulvar syringoma causing vulvar pruritus and venerophobia. *Australas J Dermatol*. 2004;45:236-7.
- Iwao F, Onozuka T, Kawashima T. Vulvar syringoma successfully treated with tranilast. *Br J Dermatol*. 2005;153:1228-30.
- Garman M, Metry D. Vulvar syringomas in a 9-year-old child with review of the literature. *Pediatr Dermatol*. 2006;23:369-72.
- Kopera D, Soyer HP, Cerroni L. Vulvar syringoma causing pruritus and carcinophobia: treatment by argon laser. *J Cutan Laser Ther*. 1999;1:181-3.
- García-Arpa M, Sánchez-Caminero P, Vera-Iglesias E, Martín-Dávila F. Múltiples pápulas vulvares. *Actas Dermosifiliogr*. 2007;98:499-500.
- Wang JI, Roenigk HH. Treatment of multiple facial syringomas with the carbon dioxide (CO₂) laser. *Dermatol Surg*. 1999;25:136-9.

Oncocytoma of the Lacrimal Caruncle

C. A. García,^a M. A. Melo-Uribe,^b and J. A. Díaz^b

^aPathologist, Universidad Industrial de Santander, Bucaramanga, Colombia

^bPathology Resident, Universidad Industrial de Santander, Member of the Grupo Patología Estructural Funcional y Clínica at the Universidad Industrial de Santander PATUIS, Bucaramanga, Colombia

To the Editor:

Oncocytomas are neoplasms that originate in the glandular and secretory epithelia.¹ Histologically, the masses are composed of polyhedral cells of granular eosinophilic cytoplasm, which presents abundant mitochondria when examined ultrastructurally.¹ In cutaneous presentations, the most common sites are the ocular caruncle and medial eyelid canthus.²

The incidence of neoplasm in the caruncle is around 3% of all tumor biopsies from ocular adnexa. Ostergaard³ published a Danish series spanning 25 years that included 574 biopsies of caruncular lesions, reporting an incidence of 2.8%. In another series of 466 biopsies of the caruncle reported by Pecorella,⁴ the incidence of oncocytoma was 2.7%. This tumor is more common among older adults and women: the average age at presentation is 73 years and 5 times more women

than men are affected.⁴ Biologically, the tumor is benign, although malignant oncocytomas have been described.⁵

We describe an 82-year-old man who attended an ophthalmology clinic in Colombia for a cystic lesion that had been growing on the inner area of the left eye for 1 year and presented occasional bleeding. The physical examination revealed a rounded polypoid lesion measuring 7 mm across in the caruncle of the left eye. The lesion was highly vascularized, but there was no involvement of the skin of the palpebral fold. The mass was surgically removed.

The anatomical pathology department received a fragment of tissue partially lined with epidermis that measured 1.2 × 1.1 cm at the largest diameter. The fragment contained a strongly vascularized reddish-brown polypoid lesion of 0.7 × 0.6 cm at the cross diameter. Tissue sections with

hematoxylin eosin stain showed an area of palpebral and bulbar conjunctiva corresponding to the area of the caruncle. The lamina propria contained a benign tumor of epithelial origin composed of polyhedral cells with a slightly hyperchromatic central nucleus and eosinophilic granular cytoplasm, with well-circumscribed cell borders. The cells were arranged in solid nests associated with vascular congestion and foci of microhemorrhaging (Figure 1). Periodic acid-Schiff staining revealed an intense granular acidophilic content in the cytoplasm, corresponding to the high number of mitochondria (Figure 2).

The lesion was diagnosed as an oncocytoma of the lacrimal caruncle.

Oncocytoma, also known as an oncocytic tumor or oxyphilic cell adenoma, is a tumor that originates in the cells of glandular and secretory epithelia. Oncocytomas have been

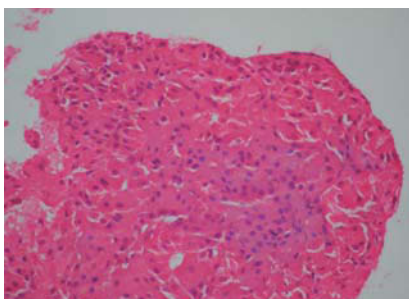


Figure 1. Benign tumor lesion of epithelial origin composed of polyhedral cells of granular eosinophilic cytoplasm and central nucleus, arranged in a solid pattern. (Hematoxylin-eosin, $\times 10$).

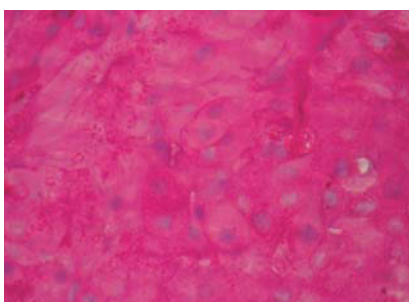


Figure 2. Numerous intracytoplasmic granules positive to periodic acid-Schiff staining with the high number of mitochondria characteristic of oncocytic lesions can be seen. (Periodic acid-Schiff, $\times 100$).

described at different sites, mainly the salivary, parathyroid, adrenal, and thyroid glands, kidneys, gastrointestinal system, and ocular adnexa.^{1,2} The most common site in the eyes is the caruncle and the inner canthus of the eyelids, although the condition has also been reported in the lacrimal gland and conjunctiva.⁶

Oncocytomas of the caruncle are slow-growing lesions that reach an average size of 2 to 5 mm and may be

solid or cystic.² The lesions are asymptomatic, but may occasionally be accompanied by an inflammatory response and become reddish. They are usually removed to establish diagnosis and for cosmetic reasons.⁷

Histologically, oncocytomas are characterized by the presence of polyhedral cells, with abundant granular and eosinophilic cytoplasm⁸ (Figure 1). The cytoplasm stains with periodic acid-Schiff reagent and phosphotungstic acid (Figure 2). The cells show positive antibody reactions to low-molecular-weight cytokeratins; some of the tumor cells are diffusely positive for carcinoembryonic antigen. The cells are not immunoreactive to vimentin, CD68, S100 protein, or HMB-45 monoclonal antibodies.^{1,2} Electron microscopy has shown that the cytoplasm of these cells is occupied by large quantities of mitochondria filled with crystals.¹

The differential diagnosis should be established with benign masses of inflammatory origin, papilloma, dermoid and epidermoid cyst, basal cell carcinoma, angioma, and pyogenic granuloma.²

Oncocytomas of the caruncle rarely recur and are classified as biologically benign, although cases of malignant oncocytoma of the eyelid, known as oncocytic carcinomas, have been reported.⁵ These oncocytomas differ from benign oncocytomas in their cellular atypia, invasive nature, and development of recurrences and metastasis. In our patient, lesions had not recurred after 6 months of clinical follow-up.

In conclusion, our literature review did not reveal any reports of this disease

in Colombia and, therefore, we present the first case of this lesion in our country. This tumor should be considered when performing the differential diagnosis of slow-growing lesions in the caruncle of elderly patients. The tumor is benign and complete resection is the definitive treatment.

References

1. Filho JP, Vianna RN, Coutinho AB, Arthurs B, Burnier MN Jr. Oncocytoma of the caruncle: a clinicopathologic case report. *Int Ophthalmol.* 2004; 25: 321-3.
2. Mohan ER, Biswas J, Krishnakumar S. Oncocytoma of the caruncle. *Indian J Ophthalmol.* 2002;50:60-1.
3. Ostergaard J, Prause JU, Heegaard S. Caruncular lesions in Denmark 1978-2002: a histopathological study with correlation to clinical referral diagnosis. *Acta Ophthalmol Scand.* 2006;84:130-6.
4. Pecorella I, Garner A. Ostensible oncocytoma of accessory lacrimal glands. *Histopathology.* 1997;30: 264-70.
5. Shintaku M, Tsuta K, Yoshida H, Tsubura A, Nakashima Y, Noda K. Apocrine adenocarcinoma of the eyelid with aggressive biological behavior: Report of a case. *Pathol Int.* 2002;52: 169-73.
6. Evans M, Chang E, Rao NA. Granular cell tumor: a rare caruncle lesion. *Br J Ophthalmol.* 2006;90:246-7.
7. Toledano Fernández N, García Sáenz S, Arteaga Sánchez A, Jareno Dorrego ME, Román Guindo JM. Oncocitoma de la carúncula. Caso clínico. *Arch Soc Esp Oftalmol.* 2000;75:709-12.
8. Morgan MB, Truitt CA, Romer C, Somach S, Pitha JV. Ocular adnexal oncocytoma: a case series and clinicopathologic review of the literature. *Am J Dermatopathol.* 1998;20:487-90.