

CASES FOR DIAGNOSIS

Papules on the Dorsum of the Hands

I. Cervigón-González,^a L.M. Torres-Iglesias,^a A. Palomo-Arellano,^a and E. Sánchez-Díaz^b

^aServicio de Dermatología and ^bServicio de Anatomía Patológica, Hospital Nuestra Señora del Prado, Talavera de la Reina Toledo, Spain

Clinical History

The patient was a 52-year-old woman with a past history of infiltrating ductal carcinoma of the breast treated surgically 6 years earlier and on treatment with tamoxifen. She was seen in our outpatient clinic for asymptomatic lesions that had appeared progressively on the dorsum of the hands over a period of 5 years.

Physical Examination

Multiple, rubbery, whitish papules of 2 to 5 mm diameter were observed (Figure 1). There were no similar lesions on other areas of the skin.

Histopathology

Microscopy revealed the presence of focal deposits of mucin between the collagen bundles of the dermis (Figure 2); these deposits stained with colloidal iron (Figure 3) and alcian blue.

Complementary Tests

The complete blood count, biochemistry profile including liver function studies, protein electrophoresis, and basic radiology studies were all normal.

What Was the Diagnosis?

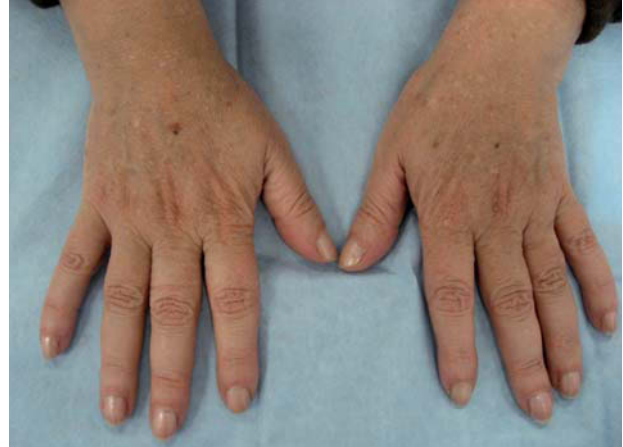

Figure 1.

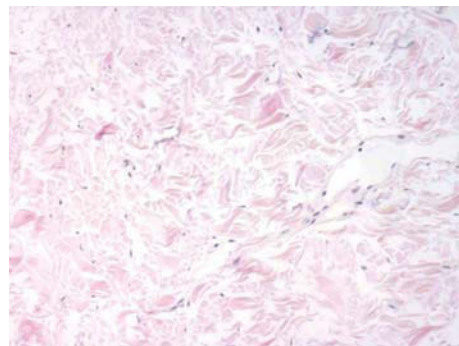


Figure 2.
Hematoxylin-eosin, $\times 200$.

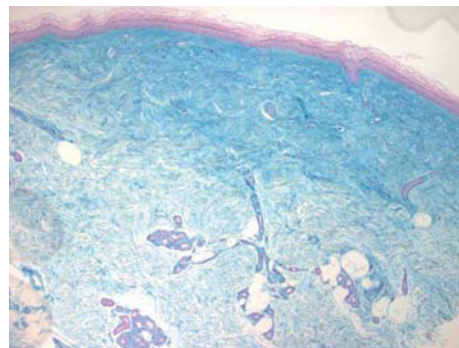


Figure 3.
Colloidal iron, $\times 4$.

Correspondence:
Iván Cervigón González
Servicio de Dermatología
Hospital Nuestra Señora del Prado
Carretera de Madrid, km 114
45600 Talavera de la Reina, Toledo, Spain
icervigon@sescam.jccm.es

Diagnosis

Acral persistent papular mucinosis.

Clinical Course and Treatment

No treatment was performed. The lesions are currently stable.

Discussion

The cutaneous mucinoses are a heterogeneous group of diseases in which there is an abnormal accumulation of mucin. They are divided into primary, in which mucin deposition is the principal histopathologic characteristic, and secondary, in which this is an additional finding. The primary mucinoses are subdivided in turn into dermal, follicular, and neoplastic-hamartomatous.

The dermal primary cutaneous mucinoses are characterized by deposits of mucin in the dermis. There are localized forms with no systemic involvement (papular mucinosis or lichen myxedematosus), generalized forms associated with systemic diseases such as immunoglobulin G monoclonal gammopathy (scleromyxedema), and intermediate or atypical forms with characteristics of both the above groups.^{1,2}

Acral persistent papular mucinosis was described as a separate condition by Rongioletti et al³ in 1986, and is considered to be one of the 5 clinicopathologic variants of lichen myxedematosus.¹ It is a rare disorder and only around 20

cases have been published.⁴ It usually affects women and is characterized by the appearance of persistent, asymptomatic papules that have a symmetrical distribution on the dorsum of the hands and on the wrists.^{4,5} The lesions can remain stable or worsen over the years.^{4,5} Histologically, focal deposits of mucin are observed in the papillary and mid-dermis, and there is a variable proliferation of fibroblasts.⁶ Although our patient was diagnosed with breast cancer, we do not believe that this tumor had any etiologic relationship with the skin condition, as acral persistent papular mucinosis is not associated with systemic diseases.

Conflicts of Interest

The authors declare no conflicts of interest.

REFERENCES

1. Rongioletti F, Rebora A. Updated classification of papular mucinosis, lichen myxedematosus, and scleromyxedema. *J Am Acad Dermatol.* 2001;44:273-81.
2. Gómez-Díez S, Del Brío-León MA, Coto P, Pérez-Oliva N, Riera-Rovira P. Scleromyxedema: ultrastructural study. *Actas Dermosifiliogr.* 2005;96:619-22.
3. Rongioletti F, Rebora A, Crovato F. Acral persistent papular mucinosis: a new entity? *Arch Dermatol.* 1986;122:1237-9.
4. Harris JE, Purcell SM, Griffin TD. Acral persistent papular mucinosis. *J Am Acad Dermatol.* 2004;51:982-8.
5. Pérez Mies B, Hernández Martín A, Barahona Cordero E, Echevarría Iturbe C. Mucinosis papular acral persistente. *Actas Dermosifiliogr.* 2006;97:522-4.
6. Rongioletti F, Rebora A. Cutaneous mucinosis: microscopic criteria for diagnosis. *Am J Dermatopathol.* 2001;23:257-67.