

## References

1. Barrera M, Bosch R, Mendiola M, Frieyro M, Castillo R, Fernández A, et al. Reactivación de la sífilis en Málaga. *Actas Dermosifiliogr*. 2006;97:323-6.
2. Dourmishev LA, Dourmishev AL. Syphilis: uncommon presentations in adults. *Clin Dermatol*. 2005;23:555-64.
3. Baniandrés Rodríguez O, Nieto Perea O, Moya Alonso L, Carrillo Gijón R, Harto Castaño A. Nodular secondary syphilis in a HIV patient mimicking cutaneous lymphoma. *An Med Interna*. 2004;21:241-3.
4. Erfurt C, Lueftl M, Simon M Jr, Schuler G, Schultz ES. Late syphilis mimicking a pseudolymphoma of the skin. *Eur J Dermatol*. 2006;16:431-4.
5. Silber TJ, Kastrinakis M, Taube O. Painful red leg nodules and syphilis: a consideration in patients with erythema nodosum-like illness. *Sex Transm Dis*. 1987;14:52-3.
6. Vibhagool C, Raimer SS, Sánchez RL. A nodule on the lip. Nodular secondary syphilis. *Arch Dermatol*. 1996;132:822-6.
7. Boneschi V, Brambilla L, Bruognolo L. Late secondary syphilis. *G Ital Dermatol Venereol*. 1989;124:211-4.
8. Dave S, Gopinath DV, Thappa DM. Nodular secondary syphilis. *Dermatol Online J*. 2003;9:9.
9. Šapra S, Weatherhead L. Extensive nodular secondary syphilis. *Arch Dermatol*. 1989;125:1666-9.
10. Lantis LR, Petrozzi JW, Hurley HJ. Sarcoid granuloma in secondary syphilis. *Arch Dermatol*. 1969;99:748-52.
11. Sánchez M. Sífilis. In: Fitzpatrick T, editor. *Dermatology in General Medicine*. 5th ed. Madrid: Panamericana; 2001:2707.

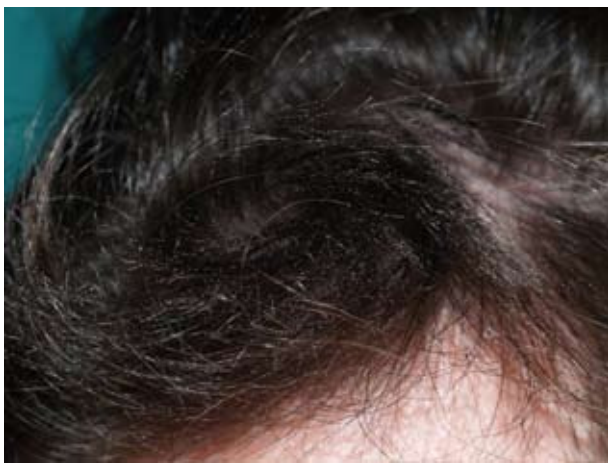## Localized Trichorrhhexis Nodosa

Z. Martínez de Lagrán, M.R. González-Hermosa, and J.L. Díaz-Pérez

Servicio de Dermatología, Hospital de Cruces, Vizcaya, Spain.

### To the Editor:

Trichorrhhexis nodosa (TN), also known as trichonodosis, was first described by Wilks in 1852.<sup>1</sup> It is the most common of hair dysplasias associated with increased hair fragility. It is considered an anomalous response of the hair shaft to external trauma and is clinically characterized by dry, dull, and brittle hairs of different lengths with varying numbers of small grayish-white or yellowish nodules distributed irregularly along the shaft.<sup>2</sup> These nodular formations are transverse



**Figure 1.** Lock of abnormal hair, with shafts of different lengths, a dry appearance, and the presence of multiple whitish-gray nodules.

fissures through which the hair can break off completely. If the nodules are located on the proximal portions of the hair, fracture of the shafts near the scalp will result in bald spots. If, on the other hand, they are located on the distal portion, the hairs will be fragile and of different lengths, and will show distal speckling and trichoptilosis, but no bald patches.<sup>2</sup>

TN can be a congenital disorder, presenting as an isolated autosomal dominant defect, or it may be associated with ectodermal dysplasias, ichthyosis, or other syndromes. Acquired TN, however, is much more frequent and is classified into 3 major groups<sup>3</sup>: proximal (predominantly among blacks) or distal (the most common in Spain) according to the area of the hair shaft in which the nodules appear, and localized. Very few cases of localized TN have been reported in the literature.<sup>4-10</sup> Its main clinical characteristic is that it is limited to well defined hairy areas—generally the scalp, but also the beard, moustache, pubic hair, etc. We present the case of a 24-year-old man, with no relevant history, who said that for about the last 3 years he had had a lock of hair on the frontotemporal hairline that was different from the rest. The hairs were dry, brittle, and of varying lengths, with small nodules along the shafts (Figure 1). On examination, except for Hamilton class I male pattern baldness, no underlying cutaneous abnormality was found. The patient denied using topical hair products, but did mention that when studying he used a reading light that shone directly on the lock of anomalous hair and that he had a certain tendency

to rest that area on his hand. A complete laboratory workup yielded no significant findings. A sample of the hair was taken for light microscopic and polarized light examination, and images characteristic of TN were observed (Figure 2). Six months later, with no treatment other than insistence on the importance of avoiding further traumas to the area, the patient showed a clear improvement (Figure 3). The pathogenic mechanism underlying TN seems to be the loss of or decrease in cuticle cells in 1 or more areas of the hair shaft. As a result, the cortical fibers lose their protection, separate, swell, and are exposed to external trauma. This leads to complete or partial fractures and the characteristic TN nodules.<sup>3</sup> Certain abnormalities in the amino acid composition (namely, a cystine deficiency) and in the synthesis of cortical keratins in the affected hair shafts have been described.<sup>11</sup>

While TN usually appears in healthy hair repeatedly subjected to prolonged external trauma, it can also appear in hair shafts with underlying abnormalities associated with fragile hair, such as argininosuccinic aciduria, Menkes syndrome, Netherton syndrome,<sup>12</sup> trichothiodystrophy,<sup>13</sup> monilethrix, or hypothyroidism.<sup>14</sup>


External trauma may be either chemical or physical: aggressive shampoos, frequent washing, salt water, excessive brushing, dyes, perming, tight hairstyles, application of heat, ultraviolet radiation, nervous tics, continual scratching, etc. Localized TN is usually associated with pruritic dermatoses (seborrheic dermatitis, pediculosis capitis, psoriasis, etc), trichotillomania, and other disorders that lead to the persistent manipulation of the area, scratching, and lichenification.<sup>10</sup>

While diagnosis is primarily clinical, light or electron microscopic examination or polarized light examination can be useful, as it can show the typical image resembling 2 paint brushes facing each other with their bristles pushed together in the nodules and an image resembling a single paint brush at the site of the complete transverse fracture.<sup>3</sup>

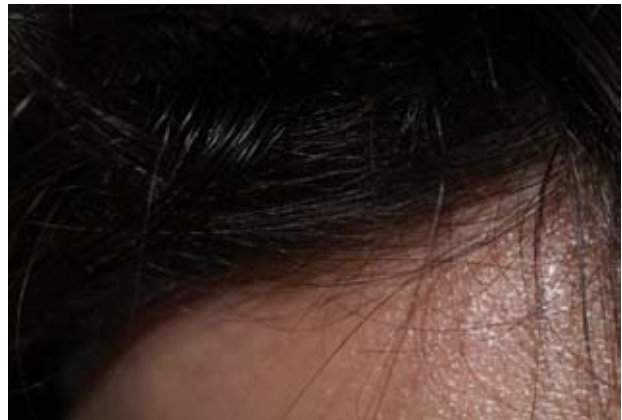The differential diagnosis is usually not especially complicated and should include pediculosis capitis, peripilar keratin casts, the presence of exogenous material, white piedra, various mycoses, bubble hair, etc.<sup>3</sup>

There is no specific treatment for TN. The only possible effective measure is to identify the predisposing factors and to avoid repeated traumas.<sup>2</sup> Certain coadjuvant treatments (such as hair repairers or vitamin complexes) can also be helpful.

In our patient, it is likely that a combination of artificial light and the patient's persistent manipulation of the area was involved in the appearance of TN, as the simple avoidance of these behavioral habits led to a clear improvement in the appearance of his hair.



**Figure 2.** Light microscopic and polarized light images of the hairs. Characteristic image resembling a paint brush at sites of complete fracture and 2 paint brushes facing each other with their bristles pushed together in the nodules.



**Figure 3.** Clear improvement after 6 months. .

Correspondence:  
Zuriñe Martínez de Lagrán.  
Servicio de Dermatología.  
Hospital de Cruces.  
Plaza de Cruces, s/n.  
48390 Cruces, Vizcaya, Spain  
zurivitoria@yahoo.es

#### Conflicts of Interest

The authors declare no conflicts of interest.

#### References

1. Jackson GT, MacMurtry CW. A treatise on the diseases of the hair. London: Kimpton; 1913. p. 131-7.
2. Dawber RPR, Ebling FJG, Wojnarowska PT. Trichorrhexis nodosa. In: Champion RH, Burton JL, Ebling FJG, editors. Textbook of Dermatology. 5th ed. Oxford: Blackwell Scientific Publications; 1992. p. 2612-3.

3. Whiting DA. Structural abnormalities of the hair shaft. *J Am Acad Dermatol.* 1987;16:1-25.
4. Itin PH, Mattarelli G, Bircher AJ, Zuberbühler E, Guggenheim R. Localized trichorrhexis nodosa. *Br J Dermatol.* 1992;127:656-7.
5. Smith RA, Ross JS, Bunker CB. Localized trichorrhexis nodosa. *Clin Exp Dermatol.* 1994;19:441-2.
6. Ghorpade A. Moustache twirler's trichorrhexis nodosa. *J Eur Acad Dermatol.* 2002;16:296-7.
7. Serrano-Ortega S, Fernández-Ángel I, Martín-Sánchez MC, Serrano-Falcón MC, Cañizares-García FJ. Trichorrhexis nodosa localizada por aplicación compulsiva de minoxidil. *Actas Dermosifiliogr.* 2002;93:469-70.
8. Kim MH, Cho SY, Whang KK, Hahm JH. A case of trichorrhexis nodosa localized to the parietal area. *Korean J Dermatol.* 2000;38:387-90.
9. Camacho-Martínez F. Localized trichorrhexis nodosa. *J Am Acad Dermatol.* 1989;4:696-7.
10. Whiting DA. Localized trichorrhexis nodosa. *J Am Acad Dermatol.* 1989;20:854.
11. Rushton DH, Norris MJ, James KC. Amino-acid composition in trichorrhexis nodosa. *Clin Exp Dermatol.* 1990;15:24-8.
12. Serra-Guillén C, Torreló A, Drake M, Armesto S, Fernández-Llaca H, Zambrano A. Síndrome de Netherton. *Actas Dermosifiliogr.* 2006;97:348-50.
13. Jiménez-Puya R, Moreno-Giménez JC, Camacho-Martínez F, Ferrando-Barberá J, Grimalt R. Tricotiodistrofia: síndrome PIBIDS. *Actas Dermosifiliograf.* 2007;98:183-7.
14. Lurie R, Hodak E, Ginzburg A, David M. Trichorrhexis nodosa: a manifestation of hypothyroidism. *Cutis.* 1996;57:358-9.

## Problems With Phototesting for the Diagnosis of Solar Urticaria

I. Allende, J. Gardeazábal, M. Lázaro, and J.L. Díaz-Pérez

Servicio de Dermatología, Hospital de Cruces, Baracaldo, Vizcaya, Spain

### To the Editor:

Solar urticaria is an uncommon idiopathic photodermatosis that presents as transient erythema and wheals in sun-exposed areas immediately following exposure to ultraviolet (UV) B (280–320 nm) or UV-A radiation (320–400 nm), or to visible light (400–600 nm).<sup>1</sup>

The diagnosis of solar urticaria is seemingly simple and is based on the patient's clinical history and the results of phototesting. In daily clinical practice, however, there are some circumstances that can make diagnosis more difficult.

We present the case of a 43-year-old woman with no drug allergies or relevant medical or surgical history.

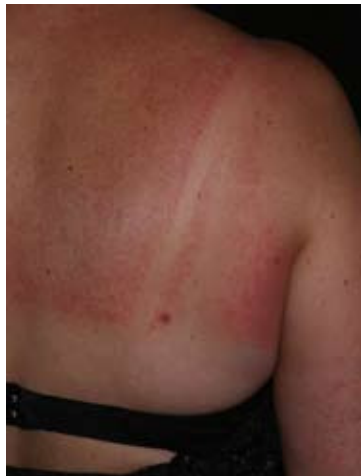

Figure 1.

She reported dermatological symptoms that had begun 14 months earlier. Her laboratory tests, which included biochemistry, blood count, C3-C4, immunoglobulin E, and antinuclear antibodies, were normal.

In her history taking she described episodes of transient pruritic rash that appeared when she was exposed to sunlight, either directly or through windows or curtains. She said that these episodes subsided in a matter of hours after she returned home and that the rash affected sun-exposed areas. As the symptoms were consistent with a diagnosis of solar urticaria, we told the patient to expose herself to natural sunlight for approximately 30 minutes. She subsequently returned to our clinic with pruritic wheals on areas that are not usually exposed to light—nape of the neck, retroauricular region, upper back, and area under her watch strap—and a very mild rash on the upper limbs. The face, back of the hands, and areas covered by clothing were not affected (Figure).

One week later we performed a phototest to confirm the diagnosis and to determine the spectrum of light responsible for the rash and the minimum urticarial dose. Various areas of the back were irradiated with the following light sources and doses:

1. UV-B source: UV-B 180 (Waldmann): 0.01 J/cm<sup>2</sup>, 0.05 J/cm<sup>2</sup>, 0.1 J/cm<sup>2</sup>, and 0.15 J/cm<sup>2</sup>.
2. UV-A source: PUVA 800 (Waldmann): 1 J/cm<sup>2</sup>, 3 J/cm<sup>2</sup>, 6 J/cm<sup>2</sup>, and 10 J/cm<sup>2</sup>.
3. Visible light source: slide projector: 10 and 15 minutes.