

Squamous Cell Carcinoma on Seborrheic Keratosis

L. Carnero,^a R. Soloeta,^a N. Arbideb,^b and R. González-Pérez^a

^aServicio de Dermatología and ^bServicio de Anatomía Patológica, Hospital Santiago Apóstol, Vitoria, Álava, Spain

To the Editor:

Seborrheic keratosis is one of the most common benign epidermal tumors in dermatologic clinical practice. Although the association between seborrheic keratosis and other skin tumors was first reported in 1932, its malignant transformation is very rare, with less than 20 published cases. We present the case of a patient with seborrheic keratosis that underwent transformation into an invasive squamous cell carcinoma.

The patient was a 94-year-old woman who was seen in our outpatient clinic for a tumor on the abdomen that had been present for 30 years and that had increased in size over a period of months, causing pain and bleeding. On physical examination, a seborrheic keratosis with a maximum diameter of 12 cm was observed. On this lesion there were several hemorrhagic, lobulated tumors (Figure 1). Complete excision of the lesion was performed, with closure by tissue planes and primary suture under local anesthesia. Microscopic examination revealed different histological patterns within the same lesion (Figures 2 and 3), with images characteristic of ulcerated seborrheic keratosis, areas of transition between seborrheic keratosis and Bowen disease, and zones where Bowen disease infiltrated the dermis (invasive squamous cell carcinoma). The histological diagnosis was of invasive squamous cell carcinoma on seborrheic keratosis. Genotyping for human papillomavirus (HPV) was positive for type 59 in 1 of the 4 blocks sent. The patient remains disease-free after 1 year of follow-up in our clinic.

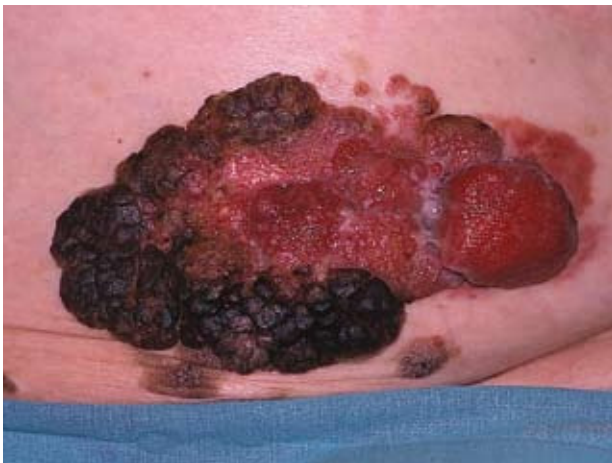

Figure 1. Squamous cell carcinoma on seborrheic keratosis.

Seborrheic keratosis is rarely associated with other skin neoplasms such as basal cell or squamous cell carcinoma, Bowen disease, keratoacanthoma, or melanomas; in these cases it is most common to find that the lesion is adjacent to or contiguous with the other tumor.^{2,3} Malignant degeneration of seborrheic keratosis is very rare⁴ and, when this occurs, it usually develops as Bowen disease and

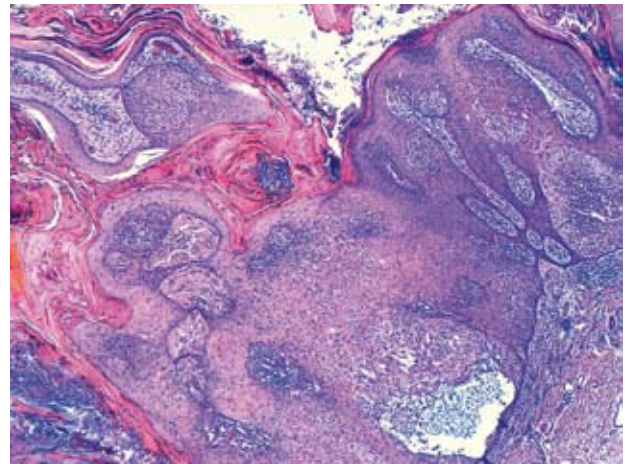


Figure 2. The right side of the image shows seborrheic keratosis with acanthosis, intraepidermal bridges, and the transition to Bowen disease, with keratinocyte disorganization and areas of dyskeratosis (hematoxylin-eosin, $\times 10$).

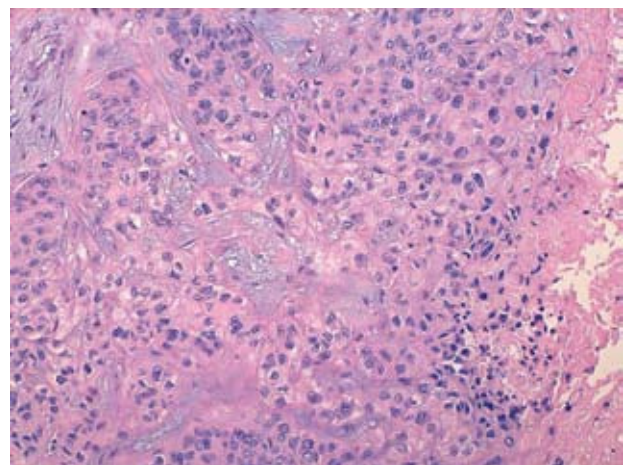


Figure 3. Infiltration of the dermis by squamous cell carcinoma with atypical, hyperchromatic epithelial cells with mitoses (hematoxylin-eosin, $\times 20$).

squamous cell carcinoma^{5,6}; the incidence is higher in men with long-standing lesions situated on the head, neck, or other areas exposed to sunlight.⁷

The molecular mechanism of this transformation is not fully understood. A number of theories implicate the proteins involved in regulation of the cell cycle, alterations of which could lead to the appearance of other tumors. Carcinoembryonic antigen,⁸ growth hormone,⁹ and proteins p63, BCL2, and BCL6 have also been implicated in the pathogenesis of malignant change.^{10,11} In addition, the role of HPV in the appearance of squamous cell carcinoma is well known. In our case, HPV type 59 was detected in one of the blocks sent for study. This is a strain with a high oncogenic risk, although the viral load in the samples was very low.

In conclusion, rapid growth or transformation of seborrheic keratosis may be a sign of the appearance of a squamous cell carcinoma. In these cases, adequate and complete excision of the lesion is recommended.

Correspondence:

Lucía Carnero González
Servicio de Dermatología
Hospital Santiago Apóstol
C/ Olaguibel, 29
01004 Vitoria, Álava, Spain
LUCIA.CARNEROGONZALEZ@osakidetza.net

Conflicts of Interest

The authors declare no conflicts of interest.

References

1. Sibley K. Seborreic verrucae and multiple basal-cell epithelioma. *Proc R Soc Med.* 1932;25:670.
2. Vun Y, De'Ambosis B, Spelman L, Muir JB, Yong-Gee S, Wagner G, et al. Seborrheic keratosis and malignancy: collision tumour or malignant transformation? *Austral J Dermatol.* 2006;47:106-8.
3. Alegre V, Pujol J, Calatayud A, Evole M. Queratosis seborreica y carcinoma epidermoide infiltrante. *Actas Dermosifiliogr.* 1989;80:621.
4. Díaz-Cascajo C, Reichel M, Sánchez JL. Malignant neoplasms associated with seborrheic keratoses. *Am J Dermatopat.* 1996;18:278-82.
5. Sharma P, Sarma DP, Adickes E. Seborrheic keratosis with in-situ squamous cell carcinoma changes. *Dermatol Online J.* 2006;12:19.
6. Anderson PJ, Zuck JA, Path MR, Rao GS, Berry FR. Squamous cell carcinoma arising within seborrheic keratosis. *Plast Reconstr Surg.* 1998;102:453-5.
7. Maize JC, Snider RL. Nonmelanoma skin cancers in association with seborrheic keratoses. *Dermatol Surg.* 1995; 21:960-2.
8. Egawa K, Honda Y, Ono T, Kuroki M. Immunohistochemical demonstration of carcinoembryonic antigen and related antigens in various cutaneous keratinous neoplasms and verruca vulgaris. *Br J Dermatol.* 1998;139:178-85.
9. Ginarte M, García-Caballero T, Fernández-Redondo V, Beiras A, Toribio J. Expression of growth hormone receptor in benign and malignant cutaneous proliferative entities. *J Cutan Pathol.* 2000;27:276-82.
10. Nakagawa K, Yamamura K, Maeda S, Ichihashi M. bcl-2 expression in epidermal keratinocytic diseases. *Cancer.* 1994;74:1720-4.
11. Wrono D, Yoo S, Chipps LK, Moy RL. The expression of p63 in actinic keratoses, seborrheic keratosis, and cutaneous squamous cell carcinomas. *Dermatol Surg.* 2004;30:1299-302.

Facial Dystrophic Calcinosis Cutis Secondary to Acne

T. Saavedra, F. Mardones, I. Sazunic, and X. Wortsman

Departamento de Dermatología, Hospital Clínico, Universidad de Chile, Santiago, Chile

To the Editor:

Acne is a common condition in the general population, mainly affecting older children and adolescents. Physical sequelae such as scarring and pigmentation disorders are often observed. However, other secondary lesions such as cutaneous calcification are occasionally reported in the literature.¹ Calcinosis cutis occurs due to the deposition of calcium and phosphate salts in the skin and, in general, can develop around localized tissue damage or in association with systemic metabolic disorders. It is classified into 4 groups according to its etiology: dystrophic, metastatic,

iatrogenic, and idiopathic; in some cases different mechanisms can coexist.²

We present 2 cases of dystrophic calcinosis cutis of the face as a sequela of inflammatory acne.

The patients were women of 48 and 58 years of age, with no past history of note. Both patients reported that they had had severe inflammatory acne during adolescence, mainly affecting the face, making particular mention of the repetitive traumatic manipulation of the facial lesions. They attended our department for treatment of the residual scars on their faces.