

squamous cell carcinoma<sup>5,6</sup>; the incidence is higher in men with long-standing lesions situated on the head, neck, or other areas exposed to sunlight.<sup>7</sup>

The molecular mechanism of this transformation is not fully understood. A number of theories implicate the proteins involved in regulation of the cell cycle, alterations of which could lead to the appearance of other tumors. Carcinoembryonic antigen,<sup>8</sup> growth hormone,<sup>9</sup> and proteins p63, BCL2, and BCL6 have also been implicated in the pathogenesis of malignant change.<sup>10,11</sup> In addition, the role of HPV in the appearance of squamous cell carcinoma is well known. In our case, HPV type 59 was detected in one of the blocks sent for study. This is a strain with a high oncogenic risk, although the viral load in the samples was very low.

In conclusion, rapid growth or transformation of seborrheic keratosis may be a sign of the appearance of a squamous cell carcinoma. In these cases, adequate and complete excision of the lesion is recommended.

---

Correspondence:

Lucía Carnero González  
Servicio de Dermatología  
Hospital Santiago Apóstol  
C/ Olaguibel, 29  
01004 Vitoria, Álava, Spain  
LUCIA.CARNEROGONZALEZ@osakidetza.net

**Conflicts of Interest**

The authors declare no conflicts of interest.

## References

1. Sibley K. Seborreic verrucae and multiple basal-cell epithelioma. *Proc R Soc Med.* 1932;25:670.
2. Vun Y, De'Ambosis B, Spelman L, Muir JB, Yong-Gee S, Wagner G, et al. Seborrheic keratosis and malignancy: collision tumour or malignant transformation? *Austral J Dermatol.* 2006;47:106-8.
3. Alegre V, Pujol J, Calatayud A, Evole M. Queratosis seborreica y carcinoma epidermoide infiltrante. *Actas Dermosifiliogr.* 1989;80:621.
4. Díaz-Cascajo C, Reichel M, Sánchez JL. Malignant neoplasms associated with seborrheic keratoses. *Am J Dermatopat.* 1996;18:278-82.
5. Sharma P, Sarma DP, Adickes E. Seborrheic keratosis with in-situ squamous cell carcinoma changes. *Dermatol Online J.* 2006;12:19.
6. Anderson PJ, Zuck JA, Path MR, Rao GS, Berry FR. Squamous cell carcinoma arising within seborrheic keratosis. *Plast Reconstr Surg.* 1998;102:453-5.
7. Maize JC, Snider RL. Nonmelanoma skin cancers in association with seborrheic keratoses. *Dermatol Surg.* 1995; 21:960-2.
8. Egawa K, Honda Y, Ono T, Kuroki M. Immunohistochemical demonstration of carcinoembryonic antigen and related antigens in various cutaneous keratinous neoplasms and verruca vulgaris. *Br J Dermatol.* 1998;139:178-85.
9. Ginarte M, García-Caballero T, Fernández-Redondo V, Beiras A, Toribio J. Expression of growth hormone receptor in benign and malignant cutaneous proliferative entities. *J Cutan Pathol.* 2000;27:276-82.
10. Nakagawa K, Yamamura K, Maeda S, Ichihashi M. bcl-2 expression in epidermal keratinocytic diseases. *Cancer.* 1994;74:1720-4.
11. Wrono D, Yoo S, Chipps LK, Moy RL. The expression of p63 in actinic keratoses, seborrheic keratosis, and cutaneous squamous cell carcinomas. *Dermatol Surg.* 2004;30:1299-302.

## Facial Dystrophic Calcinosis Cutis Secondary to Acne

T. Saavedra, F. Mardones, I. Sazunic, and X. Wortsman

Departamento de Dermatología, Hospital Clínico, Universidad de Chile, Santiago, Chile

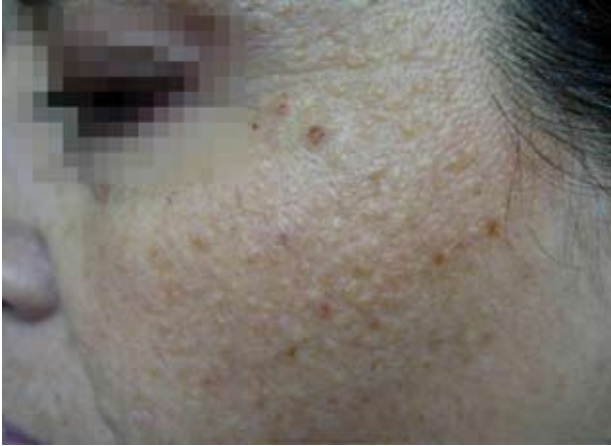*To the Editor:*

Acne is a common condition in the general population, mainly affecting older children and adolescents. Physical sequelae such as scarring and pigmentation disorders are often observed. However, other secondary lesions such as cutaneous calcification are occasionally reported in the literature.<sup>1</sup> Calcinosis cutis occurs due to the deposition of calcium and phosphate salts in the skin and, in general, can develop around localized tissue damage or in association with systemic metabolic disorders. It is classified into 4 groups according to its etiology: dystrophic, metastatic,

iatrogenic, and idiopathic; in some cases different mechanisms can coexist.<sup>2</sup>

We present 2 cases of dystrophic calcinosis cutis of the face as a sequela of inflammatory acne.

The patients were women of 48 and 58 years of age, with no past history of note. Both patients reported that they had had severe inflammatory acne during adolescence, mainly affecting the face, making particular mention of the repetitive traumatic manipulation of the facial lesions. They attended our department for treatment of the residual scars on their faces.



**Figure 1.** Millimetric, skin-colored papules on the left cheek and temporal region.

The women presented numerous depressed pinpoint scars and multiple, hard, asymptomatic, skin-colored papules of 2 to 3 mm in diameter (Figures 1 and 2). There were no other significant clinical findings.

Ultrasound was performed of the soft tissues of the papules, showing, in both cases, numerous hyperechogenic foci of calcified appearance, located in the dermis.

Histopathological study of the lesions revealed the presence of calcified nodules in the dermis associated with signs of actinic damage (Figure 3).

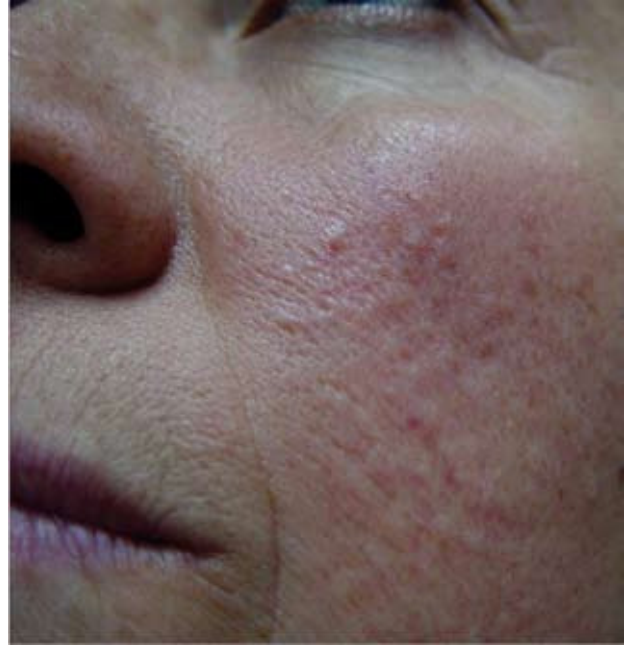
Laboratory studies showed no abnormalities of the plasma levels of calcium, phosphate, parathyroid hormone, or the markers of renal function, and the study for connective tissue diseases (antinuclear antibodies, extractable nuclear antigen, scleroderma-70) was negative.

Finally, the diagnosis of facial dystrophic calcinosis cutis secondary to acne was made.

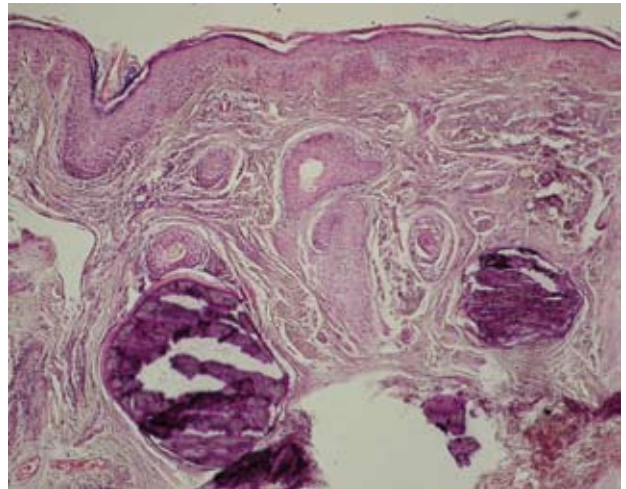
In view of the number, spread, and site of the lesions, it was decided to start medical treatment with diltiazem at a dose of 60 mg a day for a period of 2 months. At the end of this period there was no clinical improvement and, furthermore, the patients reported poor tolerance of the medication; the therapy was therefore withdrawn. In the end, abrasive treatment was prescribed to ameliorate the facial scars.

The deposits of amorphous and insoluble calcium salts in the skin are formed mainly of amorphous calcium hydroxyapatite or phosphate crystals. There appear to be multiple local and systemic mechanisms that lead to the onset of this condition.

In the absence of a tissue lesion, ectopic deposits of calcium salts develop when the calcium phosphate product in plasma exceeds 70 mg/dL.<sup>3</sup> If tissue damage is present, it has been suggested that the following pathogenic phenomena may play a role: increased intracellular calcium concentration, denaturation of proteins that preferentially



**Figure 2.** Numerous hard papules on the left cheek.



**Figure 3.** Calcium deposits in the dermis in areas with signs of actinic damage (hematoxylin-eosin, x200)

bind phosphate, genetic mutations of elastic fibers and collagen, and increased  $\gamma$ -carboxyglutamic acid.

The majority of cases of calcinosis cutis are associated with connective tissue diseases. Dystrophic calcinosis cutis is the most common form and develops around localized tissue damage, with no alterations of calcium or phosphate metabolism.<sup>2</sup> In general the patients have a past history of an underlying disease, previous injury, or inflammatory dermatosis.

The majority of cases of calcinosis cutis have a gradual onset and are asymptomatic; however, the history and clinical course of the condition vary mainly according to

the etiology of the calcification. Clinical manifestations will also depend on the underlying disorder (if present), but usually there are multiple, hard, whitish papules, plaques, or nodules with a symmetrical distribution.

Morbidity depends on the extent and site of the cutaneous calcification; joints, muscles, and organs such as the lungs, kidneys, and intestine may also be affected. In addition, vascular deposits of calcium can give rise to distal ischemia and necrosis. Areas of ulceration or the transcutaneous elimination of a whitish-yellow, chalk-like material may be observed, and secondary infection can develop. The therapeutic measures used depend on the underlying disease; in general the outcomes are not very satisfactory and only the results of case reports are available.

Most medical treatments for calcinosis cutis have been described in patients with connective tissue diseases. They include warfarin, colchicine, probenecid, bisphosphonates, minocycline, and diltiazem.<sup>4-8</sup>

Success has also been reported with other treatment modalities, such as carbon dioxide laser and intralesional corticosteroid injection.<sup>9,10</sup>

Finally, surgery is a possible option to remove calcium deposits in necrotic or infected tissues.

In conclusion, calcinosis cutis is a rarely reported sequela of acne and represents a therapeutic challenge. Clinical suspicion and appropriate additional tests are required to reach the diagnosis.

---

Correspondence:  
Felipe Mardones Valdivieso  
Departamento de Dermatología  
Hospital Clínico Universidad de Chile  
Santos Dumont, 999 Santiago, Chile  
fmardonesv@yahoo.com

### Conflicts of Interest

The authors declare no conflicts of interest.

### References

1. Basler RS, Watters JH, Taylor WB. Calcifying acne lesions. *Int J Dermatol.* 1977;16:755-8.
2. Walsh JS, Fairley JA. Calcifying disorders of the skin. *J Am Acad Dermatol.* 1995;33:693-706.
3. Nagore E, Molinero J, Sánchez-Motilla JM, Vidal E, Oliver V, Aliaga A. Nódulos subcutáneos dolorosos abdominales como forma de presentación de una calcifilaxia en la insuficiencia renal crónica. *Actas Dermosifiliogr.* 2002;93:332-3.
4. Berger RG, Featherstone GL, Raasch RH, McCartney WH, Hadler NM. Treatment of calcinosis universalis with low-dose warfarin. *Am J Med.* 1987;83:72-6.
5. Harel L, Harel G, Korenreich L, Straussberg R, Amir J. Treatment of calcinosis in juvenile dermatomyositis with probenecid: the role of phosphorus metabolism in the development of calcifications. *J Rheumatol.* 2001;28:1129-32.
6. Mukamel M, Horev G, Mimouni M. New insight into calcinosis of juvenile dermatomyositis: a study of composition and treatment. *J Pediatr.* 2001;138:763-6.
7. Robertson LP, Marshall RW, Hickling P. Treatment of cutaneous calcinosis in limited systemic sclerosis with minocycline. *Ann Rheum Dis.* 2003;62:267-9.
8. Dolan AL, Kassimos D, Gibson T, Kingsley GH. Diltiazem induces remission of calcinosis in scleroderma. *Br J Rheumatol.* 1995;34:576-8.
9. Chamberlain AJ, Walker NP. Successful palliation and significant remission of cutaneous calcinosis in CREST syndrome with carbon dioxide laser. *Dermatol Surg.* 2003;29:968-70.
10. Lee SS, Felsenstein J, Tanzer FR. Calcinosis cutis circumscripta. Treatment with an intralesional corticosteroid. *Arch Dermatol.* 1978;114:1080-1.

## Melanoma and Retinoblastoma\*

S. Martínez-García, L. Martínez-Pilar, E. Gómez-Moyano, and V. Crespo

Servicio de Dermatología y Venereología, Complejo Hospitalario Universitario Carlos Haya, Malaga, Spain

### To the Editor:

Retinoblastoma is an embryonal tumor derived from retina cells that affects 5 in every 100 000 newborns and accounts for 3% of cancers in those children aged less than 15 years. It is the most common type of malignant

intraocular tumor in children and the second most common for all age groups after melanoma.<sup>1</sup>

Most cases are diagnosed in the first 4 years of life. Presentation is unilateral in 60% to 75% of cases, and 60% are classed as sporadic.<sup>2</sup> The remaining cases are bilateral and mostly hereditary.

Bilateral forms are caused by a double mutation in the Rb gene on the long arm of chromosome 13.<sup>3,4</sup> The

---

\*This case was presented as a poster in the XXXVI National Congress on Dermatology in Barcelona 2008 and was awarded a special mention within the Oncology section