

CASE REPORT

Amicrobial Pustulosis of the Folds: Report of a New Case and Review of the Literature

G. Márquez-Balbás,^a M. Iglesias,^a E. Herrera-Acosta,^b I. Vidal-Olmo,^a A. Guilabert,^c J.M. Mascaró-Galy,^c and P. Umbert^a

^aServicio de Dermatología, Hospital Universitari Sagrat Cor, Barcelona, Spain

^bServicio de Dermatología, Hospital Clínic, Malaga, Spain

^cServicio de Dermatología, Hospital Clínic i Provincial, Barcelona, Spain

Abstract. Amicrobial pustulosis of the folds is a rare disorder characterized by a recurrent sterile pustular rash mainly affecting the skinfolds, scalp, and periorificial regions such as around the external auditory meatus. Few cases have been reported in the literature, most of them occurring in women and all of them associated with some immunological disorder, the most common being lupus erythematosus. We present a new case of amicrobial pustulosis of the folds in a woman; the only immunologic abnormality detected was an elevation of immunoglobulin E. We have also reviewed the 35 cases reported in the literature.

Key words: amicrobial pustulosis of the folds, pustular dermatosis, neutrophilic dermatosis, connective tissue disease, lupus erythematosus.

PUSTULOSIS AMICROBIANA DE LAS FLEXURAS. DESCRIPCIÓN DE UN NUEVO CASO Y REVISIÓN DE LA LITERATURA

Resumen. La pustulosis amicrobiana de las flexuras es una entidad poco frecuente, caracterizada por erupciones formadas por pústulas estériles, de curso recidivante, que afectan a los grandes pliegues cutáneos, cuero cabelludo y áreas periorificiales como el conducto auditivo externo, mayormente. Se han descrito pocos casos en la literatura, la mayoría de ellos en mujeres, y todos ellos asociados a alguna alteración inmunológica, siendo el lupus eritematoso el más frecuente. Presentamos un nuevo caso de esta enfermedad, en una mujer que como única alteración inmunológica presentaba una elevación de la IgE, revisando también los casos descritos en la literatura por el momento.

Palabras clave: pustulosis amicrobiana de las flexuras, dermatosis pustulosa, dermatosis neutrofílica, enfermedad del tejido conectivo, lupus eritematoso.

Introduction

Amicrobial pustulosis of the folds is an entity characterized by outbreaks of papulopustular, eczematous, and aseptic lesions that appear suddenly and tend to recur. It predominantly affects the skin folds, external ear canal, scalp, and genital area.

Amicrobial pustulosis of the folds, which typically occurs in autoimmune disorders, should be included in the spectrum of noninfectious neutrophilic dermatoses. These include Sweet syndrome,^{1,2} which can also appear in patients with autoimmune disorders. The disease was first reported in 1991 by Crickx et al,³ who described 2 young women with systemic lupus erythematosus and outbreaks of amicrobial pustules in the scalp, large folds, and external ear canal. These patients responded well to treatment with systemic corticosteroids. The 34 cases described to date in the literature refer to a broad spectrum of underlying immunologic disorders, the most frequent of which is systemic lupus erythematosus.

We describe the clinicopathologic characteristics and laboratory findings for a new presentation of this unusual entity.

Correspondence:
Gemma Márquez Balbás
Hospital Sagrat Cor
C/ Paris, 83
08029 Barcelona, Spain
40871gmb@comb.es

Accepted February 11, 2009. .

Case Description

The 30-year-old female patient had no personal or family history of relevance. She consulted for a clinical picture, which had developed over a year and a half, consisting of outbreaks of skin lesions in the form of scaly erythematous and erosive plaques with small coalescent pustules. The main location was skin folds (axillae, groin, submammary folds, intergluteal folds, and external ear canal). There was evidence of involvement of the interdigital folds in the feet and also of suppurating paronychia (Figure 1). Exudative alopecic plaques with follicular pustules in the scalp had been observed to occasionally partially resolve in response to treatment with oral antibiotics (cefuroxime and fusidic acid), oral antifungal agents (itraconazole), and topical agents (antibiotics, antifungal agents, and corticosteroids).

Laboratory tests revealed all parameters to be within normal limits, except for raised C-reactive protein

concentrations, increased immunoglobulin (Ig) E (IgE) levels (2960 IU/mL; normal range 0-380 IU/mL), and a decreased response to the nitroblue tetrazolium test. An exhaustive immunologic study was conducted that revealed normal values for the following parameters: interleukin 6 and 10; tumor necrosis factor; IgG, IgA, and IgM; C3; C4; CH50; C1q; C1-inhibitor; the antinuclear, antimitochondrial, antigastric parietal cell, and antismooth muscle antibodies; anti-Sm, anti-DNA, anti-U1-RNP, anti-SSA-Ro, anti-SSB-La, CD3, CD4, CD8, and Mannose-binding-lectin; and Fc- γ IIIa and IIb polymorphisms.

Bacterial and mycological cultures of sterile pustules were either negative or showed excessive *Staphylococcus aureus* growth. Periodic acid-Schiff staining was negative.

A number of skin biopsies were conducted, revealing psoriasiform hyperplasia of the epidermis, small subcorneal spongiform pustules with exocytosis of the neutrophils, and a mixed infiltrate in the upper and

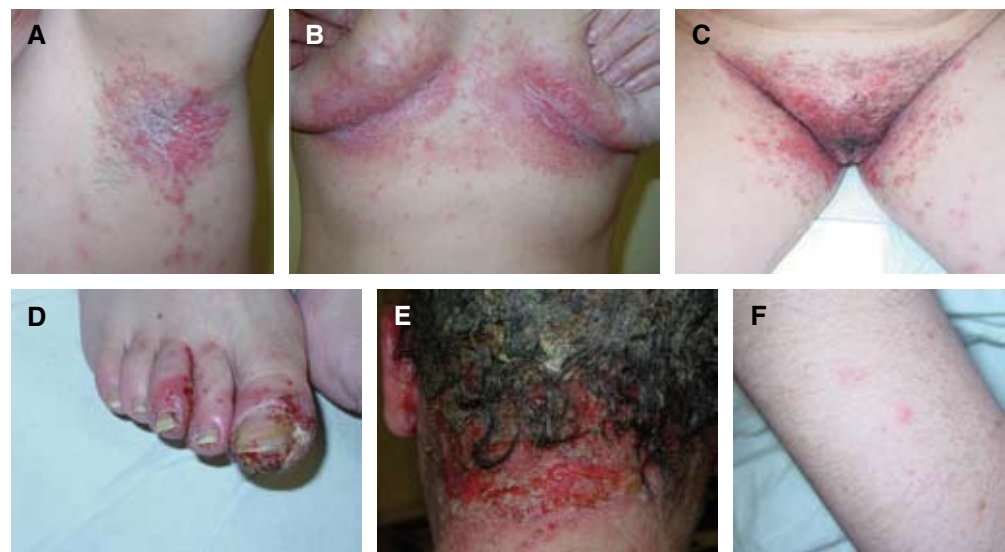

Figure 1. A, B, and C. Scaly erythematous lesions with isolated pustules in large folds. D. Interdigital and periungual folds. E. Pustular and exudative plaques in the scalp. F. An intact pustule.

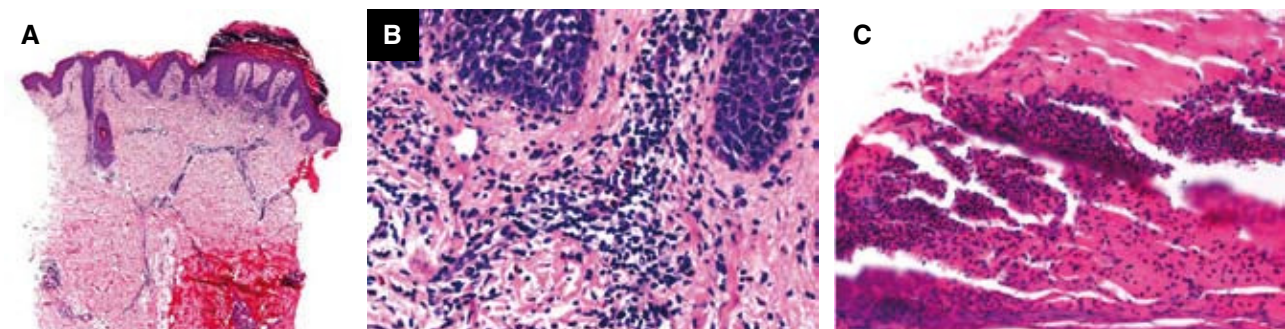


Figure 2. Punch biopsy, hematoxylin-eosin staining, $\times 8$. A. Hyperparakeratosis with parakeratosis, psoriasiform epidermal hyperplasia, infiltrate in the upper and middle epidermis, and perifollicular infiltrate. B and C. Enlargement ($\times 15$) revealing mixed infiltrate in the dermis and in subcorneal spongiform pustules.

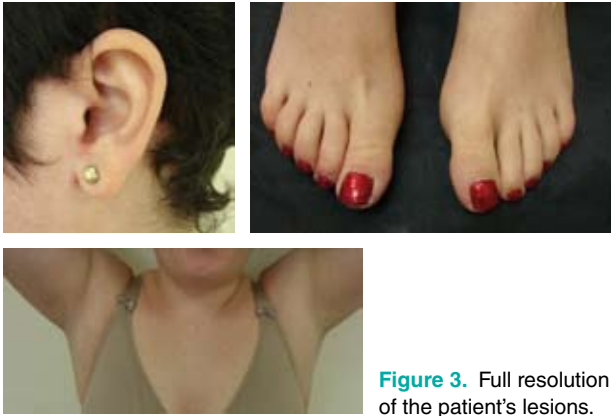


Figure 3. Full resolution of the patient's lesions.

Table 1. Diagnostic Criteria for Amicrobial Pustulosis of the Folds

Mandatory Criteria	Minor Criteria
Pustulosis affecting 1 or more of the major folds, or 1 or more of the minor folds and also the anogenital fold	Association with 1 or more autoimmune disorders
Histology: Intraepidermal spongiform pustules and a neutrophil infiltrate in the dermis	ANA titers of 1/160 or more
Negative culture of an intact pustule	Presence of 1 or more of ENA, anti-DNA, antismooth muscle, antimitochondrial, antigastric parietal cell, or endomysial antibodies.

A diagnosis of amicrobial pustulosis of the folds should be suspected if a mandatory criterion plus a minor criterion are satisfied.

Abbreviations: ANA, antinuclear antibodies; ENA, extractable nuclear antigens

middle dermis (Figure 2). Direct immunofluorescence for the IgA, IgM, and IgG, C3, and fibrinogen, and indirect immunofluorescence were all negative.

Based on these clinical and pathologic findings, and after ruling out other diagnoses, it was decided to treat the case as amicrobial pustulosis of the folds. Treatment was initiated with low doses of oral prednisone (15 mg/d for 4 days, subsequently tapered). The lesions on the scalp were surgically debrided, resulting in satisfactory resolution and new hair growth. Within a month the patient's lesions had improved significantly, and eventually resolved completely (Figure 3). The prednisone dose was progressively reduced, with lasting and sustained remission achieved with 5-mg doses of prednisone on alternate days, supplemented with 100-mg daily doses of oral zinc sulfate. In the last 2 years the patient has experienced minor

relapses in the form of some periumbilical pustules, which rapidly resolved in response to low to moderate strength topical corticosteroids. Test results revealed persistently high levels of IgE, with all other immunologic parameters remaining within normal limits.

It should be mentioned that the patient became pregnant in the last year. It was decided jointly with the gynecology and obstetrics department to stop the oral zinc treatment, but not to modify the corticosteroid maintenance treatment during the pregnancy. The pregnancy unfolded normally, resulting in a full-term healthy baby with no skin lesions.

Discussion

Amicrobial pustulosis of the folds is a relatively new entity, characterized by recurring outbreaks of pustular lesions that mainly affect the skin folds and that occur in patients with autoimmune disorders.

Its etiology remains unclear. Neutrophils, as the body's first line of defense, appear to play an important role in triggering this disease, as suggested by the histology. It has been reported that the disease is caused by neutrophil dysfunction.^{4,5} The fact that our patient showed a decreased response to the nitroblue tetrazolium test reinforces the hypothesis of altered neutrophil function in the pathogenesis of this entity. The predominance of women with this disorder may be explained by underlying autoimmune disorders, such as systemic lupus erythematosus, that tend to occur more in women than men.

Our diagnosis of amicrobial pustulosis of the folds was mostly based on clinical and histopathologic criteria. Described recently was a set of criteria to assist with differential diagnosis of this disease. The criteria are based on cases described in the literature to date, and take into account the number of affected sites, histologic features, and immunologic findings (Table 1).

Of the possible differential diagnoses considered initially, we ruled out drug-induced entities and infectious diseases. The possible diagnostic options are summarized in Table 2.

Immunohistologic features in lesions resulting from amicrobial pustulosis of the folds have been recently studied,⁶ with findings that show overexpression of Bcl-2, accompanied by normal expression of CD8 and p53. This contrasts with skin lesions caused by lupus erythematosus, which show p53 overexpression and reduced Bcl-2 expression. In the skin biopsies of our patient, immunohistology revealed that the infiltrate was 30% positive for Bcl-2 and less than 5% positive for CD8—data that are consistent with the pattern described above.

Table 2. Differential Diagnosis of Amicrobial Pustulosis of the Folds.

Possible Diagnosis	Characteristic Features
Pustular psoriasis	Pustules on an erythematous base, which develop de novo or over previous psoriasis lesions, and which tend to lead to systemic affectation
Pemphigus foliaceus	Superficial blisters that burst easily, leaving exposed areas in the face, neck, and trunk
	Histology: intraepidermal blisters, granulomatous acantholysis
	DIF positive (IgG and C3)
	IIF positive (desmoglein I)
Pemphigus IgA	Vesicular-pustular lesions arranged in a ring, especially in the axillary and groin areas
	Histology: intraepidermal pustules and vesicles
	DIF positive (IgA)
	IIF positive (desmocollin I)
Subcorneal pustular dermatosis (Sneddon-Wilkinson disease)	Superficial and fragile vesicles, and pustules on an erythematous base
	Histology: subcorneal pustules and vesicles with abundant neutrophils
	DIF and IIF positive at 50% (IgA)
Pyoderma vegetans	Numerous pustules and large raised wartlike plaques
	Histology: pseudoepitheliomatous hyperplasia, intraepidermal and subepidermal neutrophilic microabscesses
	DIF negative

Abbreviations: DIF, direct immunofluorescence; IgA, immunoglobulin A; IgG, immunoglobulin G; IIF, indirect immunofluorescence.

In a review of cases of amicrobial pustulosis of the folds described to date,^{5,7-10} it is notable that most patients are women (94%) and that these women are young to middle aged (mean age, 31.5 years). Noteworthy also is the fact that 82% of the cases were associated with systemic lupus erythematosus or other immunologic alterations associated with lupus, such as raised antinuclear antibody, anti-DNA, anti-Ro, and anti-La levels. The remaining patients had

other immunological disorders, such as myasthenia gravis, Sjögren syndrome, celiac disease, or Sharp syndrome.

Our patient currently has markedly raised IgE levels although repeated tests have not revealed any other alterations. Reported in the literature are 2 patients with raised IgE levels but without any accompanying lupus disorder.^{7,9} However, given the frequent association of this disease with lupus erythematosus and other immunologic disorders, we are of the opinion that our patient needs to be monitored closely with a view to making an early diagnosis of any autoimmune disorder in the future.

With regard to treatment of amicrobial pustulosis of the folds, as with other neutrophilic noninfectious dermatoses, systemic corticosteroids (prednisone) administered at mean doses of 0.5 to 1 mg/kg/d are effective in most cases. Corticosteroid therapy is currently the most effective treatment, although the lesions reappear in some patients once dosage is reduced or treatment is stopped. Systemic antibiotics are not effective in treating this disease unless there is secondary impetiginization in the lesions. Several other treatments have been tried, such as oral retinoids and sulfones, with varying results. Oral zinc supplements have been used successfully to treat 2 patients,¹¹ 1 with a zinc deficiency. A recent article has reported the efficacy of oral cimetidine (400 mg/12 hours) combined with ascorbic acid (3 g/d) in 5 patients, resulting in rapid and maintained improvement in the skin lesions.⁸ This is a safe and effective alternative to systemic corticosteroids. A satisfactory clinical response to hydroxychloroquine (400 mg/d) in combination with prednisone (0.5 mg/kg/d) has also been described in a patient who failed to tolerate treatment with oral sulfone.⁵ Other treatments, such as cyclosporin, methotrexate, levamisole, and colchicine,^{1,10} have been tested in isolated cases but with mixed results.

Conflicts of Interest

The authors declare no conflicts of interest.

References

1. Lagrange S, Chosidow O, Piette JC, Wechsler B, Godeau P, Frances C. A peculiar form of amicrobial pustulosis of the folds with systemic lupus erythematosus and other autoimmune diseases. *Lupus*. 1997;6:514-20.
2. Callen JP. Neutrophilic dermatoses. *Dermatol Clin*. 2002; 20:409-19.
3. Crickx B, Diego ML, Guillemin L, Picard C, Grossins M, Belaïch S. Pustulose amicrobienne et lupus érythémateux systémique. Communication n.º 11. Journées Dermatologiques de Paris. Paris, March 1991.
4. Marzano AV, Capsoni F, Berti E, Gasparini G, Bottelli S, Caputo R. Amicrobial pustular dermatosis of cutaneous folds associated with systemic lupus erythematosus and other autoimmune diseases. *Dermatology*. 1996;193:88-93.

5. Antille C, Frei M, Sorg O, Tran C, Kaya G, Masouyé I, et al. Amicrobial pustulosis of the folds associated with autoimmune disorders. *Dermatology*. 2008;216:324-9.
6. Gambichler T, Boms S, Hochdorfer B, Altmeyer P, Kreuter A. Immunohistology of amicrobial pustulosis of the folds. *Clin Exp Dermatol*. 2007;32:155-8.
7. Natsuga K, Sawamura D, Homma E, Nomura T, Abe M, Muramatsu R, et al. Amicrobial pustulosis associated with IgA nephropathy and Sjögren's syndrome. *J Am Acad Dermatol*. 2007;57:523-6.
8. Marzano AV, Ramoni S, Caputo R. Amicrobial pustulosis of the folds. Report of 6 cases and a literature review. *Dermatology*. 2008;216:305.
9. Okuyama R, Masu T, Kumasaka N, Aiba S, Tagamy H. Amicrobial pustulosis of the folds affecting a young male with out any accompanying autoimmune diseases. *Dermatology*. 2008;217:121-3.
10. Boms S, Gambichler T. Review of literature on amicrobial pustulosis of the folds associated with autoimmune disorders. *Am J Clin Dermatol*. 2006;7:369-74.
11. Bénétou N, Wolkenstein P, Bagot M, Cosnes A, Wechsler J, Roujeau JC, et al. Amicrobial pustulosis associated with autoimmune diseases: healing with zinc supplementation. *Br J Dermatol*. 2000;143:1306-10.