

4. Yoshii N, Kanekura T, Churei H, Kanzaki T. Syringoma-like eccrine sweat duct proliferation induced by radiation. *J Dermatol.* 2006;33:36-9.
5. Guitart J, Rosenbaum MM, Requena L. "Eruptive syringoma": a misnomer for a reactive eccrine gland ductal proliferation? *J Cutan Pathol.* 2003;30:202-5.
6. Corredor F, Cohen PR, Tschen JA. Syringomatous changes of eccrine sweat ducts associated with prurigo nodularis. *Am J Dermatopathol.* 1998;20:296-301.
7. Garrido-Ruiz MC, Enguita AB, Navas R, Polo I, Rodríguez-Peralto JL. Eruptive syringoma developed over a waxing skin area. *Am J Dermatopathol.* 2008;30:377-80.
8. De Pietro WP. Primary familial cutaneous amyloidosis: a study of HLA antigens in a Puerto Rico family. *Arch Dermatol.* 1981;117:639-43.
9. Weyers W, Weyers I, Bonczkowitz M, Díaz-Cascajo C, Schill WB. Lichen amyloidosis: a consequence of scratching. *J Am Acad Dermatol.* 1997;37:923-8.

Tattoo-induced Pigmentation in a Sentinel Node in a Patient With Melanoma

Ó. Suárez-Amor,^a T. Alonso-Alonso,^a M.A. González-Morán,^b E. Pastor,^c A. Turienzo,^c C. de la Fuente,^d and M.Á. Rodríguez-Prieto^a

^aServicio de Dermatología, ^bServicio de Anatomía Patológica, ^cServicio de Cirugía General, and ^dUnidad de Medicina Nuclear, Complejo Asistencial de León, León, Spain

To the Editor:

In patients with melanoma the most common cause of dark pigmentation of lymph nodes is metastases from the tumor. However, the finding of pigmented lymph nodes in these patients is not always a reliable sign of metastasis, as there are other causes that can give rise to this phenomenon.

A 33-year-old man with a history of schizophrenia was referred to our department to perform wider surgical resection and selective biopsy of the sentinel lymph node. This patient had undergone excision of a melanocytic lesion in the interscapular region; clinical atypia was present and the pathologic study was compatible with a superficial spreading melanoma with ulceration and a Breslow index of 0.7 mm. The rest of the dermatologic examination was completely normal, with the exception of the presence of a dark blue-grayish tattoo on the right arm. There were no palpable locoregional lymph nodes and no organomegaly. Preoperative lymphoscintigraphy showed drainage towards both axillas, with a single sentinel lymph node in each territory. During the operation, a sentinel lymph node of dark color was identified in the right axilla and there were 3 adherent adjacent lymph nodes that were also pigmented but with no radioactivity uptake. The 4 lymph nodes were excised in case they were metastases from the melanoma. The pathologic study of the lymph nodes of the right axilla showed reactive lymphadenitis with sinus histiocytosis and abundant deposits of dark pigment (Figure 1). Immunohistochemistry (S100 and human melanoma black-45) excluded infiltration of the lymph nodes by tumor cells. Histological study of the sentinel lymph node from the left axilla and of the extended surgical margins showed no pathological findings. The pigmentation of the right axillary lymph

nodes was related to the tattoo that the patient had on the upper limb of that side (Figure 2).

Melanoma is a malignant tumor that has the potential to spread to the lymph nodes. At the present time, selective biopsy of the sentinel lymph node is used for staging the tumor. The pathological state of the sentinel lymph node is the strongest independent prognostic factor in terms of overall survival in patients with clinical stage I or II melanoma. Early radical lymphadenectomy is indicated in cases with a positive lymph node on pathologic evaluation.¹

Tattooing is a popular cosmetic practice in Western countries.^{2,3} In permanent tattoos, the pigment is deposited in the dermis. Pigment particles migrate through the lymph vessels and are deposited in the lymph nodes, both within histiocytes and extracellularly.² The methods used

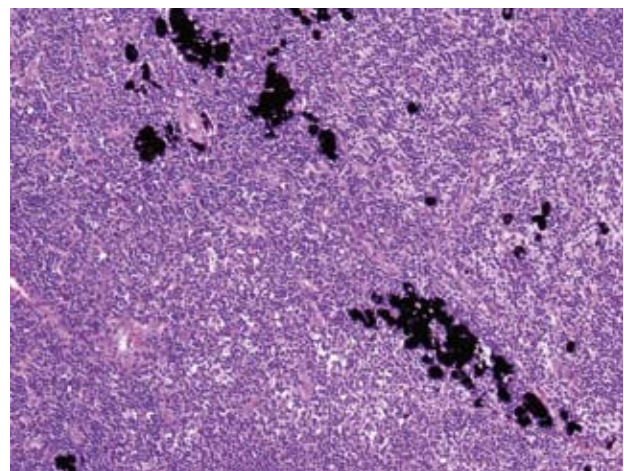


Figure 1. Granules of pigment in the macrophages and in the extracellular areas of the lymph node (hematoxylin-eosin, $\times 10$).

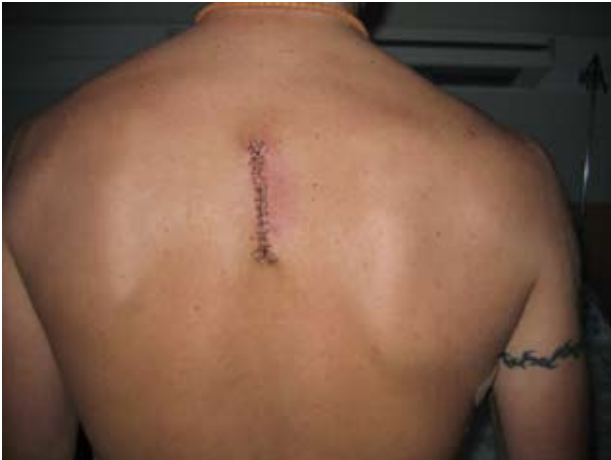

Figure 2. Scar of the widening of the surgical margins of a melanoma in the interscapular region. A tattoo can be seen on the right arm.

to remove tattoos do not eradicate the presence of the pigment in lymph nodes.³

Apart from metastases from melanoma, lymph node pigmentation has also been associated with tattoos, hemosiderin deposits secondary to local trauma or surgery, dental amalgam, aluminum, titanium, and anthracosilicotic pigment.^{2,5} Furthermore, the lymph node metastases of melanoma are not always pigmented, as the metastases may be small or the tumor may be the amelanotic variant.³ Cases of lymph node pigmentation due to tattoos have been reported in the medical literature after the excision and subsequent pathologic study of clinically palpable lymph nodes in patients with melanoma.^{2,6} This phenomenon has also been reported in the context of selective biopsy of the sentinel lymph node in cases of melanoma.^{3,4,7,8}

In the staging work-up for melanoma, the finding of a lymph node with black pigmentation can lead the surgeon to excise all the areas of drainage, despite the lack of specificity of the surgical specimen. Due to the morbidity associated with this operation, we agree with the suggestion of other authors that histological study of the sentinel lymph node should be an obligatory step before radical surgery is undertaken, particularly in those patients who have or have had a tattoo. However, the presence of nonmelanic pigment in the lymph nodes does not totally exclude the possibility of metastases; therefore, even if such pigment is present, immunohistochemical studies should be performed to exclude this risk.^{4,8}

In conclusion, we would like to reiterate that the presence of pigmented lymph nodes is not a absolute criterion for

performing radical lymphadenectomy in patients with melanoma; histological confirmation of metastases should be obtained first. In addition, in patients with melanoma, it is important to make a note in the medical history of the presence of tattoos or of their removal using techniques such as a Q-switched laser.

Acknowledgments

To Dr. Soto of Hospital El Bierzo (Ponferrada, Spain) for his collaboration in this case.

Correspondence:
Óscar Suárez Amor
Servicio de Dermatología
Complejo Asistencial de León
Altos de Nava, s/n
24080 León, Spain
osuamo@yahoo.es

Conflicts of Interest

The authors declare no conflicts of interest.

References

1. Mangas C, Paradelo C, Rex J, Ferrándiz C. La biopsia del ganglio centinela: su papel diagnóstico y pronóstico en el melanoma maligno. *Actas Dermosifiliogr.* 2008;99:331-48.
2. Bordea C, Latifaj B, Jaffe W. Delayed presentation of tattoo lymphadenopathy mimicking malignant melanoma lymphadenopathy. *J Plast Reconstr Aesthet Surg.* In press 2008.
3. Chikkamuniyappa S, Sjuve-Scott R, Lancaster-Weiss K, Miller A, Yeh IT. Tattoo pigment in sentinel lymph nodes: a mimicker of metastatic malignant melanoma. *Dermatol Online J.* 2005;11:14.
4. Mangas C, Fernández-Figueras MT, Carrascosa JM, Soria X, Paradelo C, Ferrandiz C, et al. A tattoo reaction in a sentinel lymph node from a patient with melanoma. *Dermatol Surg.* 2007;33:766-7.
5. Mataix J, Silvestre JF. Reacciones cutáneas adversas por tatuajes y piercings. *Actas Dermatosifiliogr.* 2009;100:643-56.
6. Hannah H, Falder S, Steele PR, Dhital SK. Tattoo pigment masquerading as secondary malignant melanoma. *Br J Plast Surg.* 2000;53:359.
7. Domínguez E, Alegre V, García-Melgares ML, Laguna C, Martín B, Sánchez JL, et al. Tattoo pigment in two lymph nodes in a patient with melanoma. *J Eur Acad Dermatol.* 2008;22:101-2.
8. Moehrle M, Blaheta HJ, Ruck P. Tattoo pigment mimics positive sentinel lymph node in melanoma. *Dermatology.* 2001;203:342-4.