

CASES FOR DIAGNOSIS

Symptomatic Perioral, Perinasal, and Periocular Papules

Á. Palomo, I. Cervigón, and L.M.Torres-Iglesias

Servicio de Dermatología, Hospital Nuestra Señora del Prado, Talavera de la Reina, Toledo, Spain

Clinical History

A 12-year-old girl was seen for a 2-month history of multiple asymptomatic lesions on the face. She denied applying any topical products and there were no accompanying systemic symptoms.

Physical Examination

Physical examination revealed multiple, confluent, infiltrated, yellowish papules in the central facial region (perioral, perinasal, and palpebral) (Figure 1). No similar lesions were observed elsewhere on the body.

Additional Tests

A complete blood analysis was performed, together with measurement of angiotensin converting enzyme and chest radiograph, with no abnormal findings.

Histopathology

Perifollicular and interfollicular infiltrate of noncaseating epithelioid granulomas formed of lymphocytes, histiocytes, and multinuclear giant cells (Figure 2).

What Was the Diagnosis?

Correspondence:
Iván Cervigón González
Servicio de Dermatología
Hospital Nuestra Señora del Prado
Carretera de Madrid, km 114
45600 Talavera de la Reina, Toledo, Spain
icervigon@sescam.jccm.es

Manuscript accepted for publication May 7, 2009 .

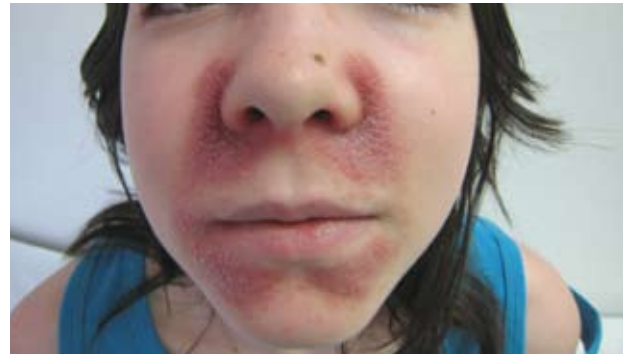

Figure 1.

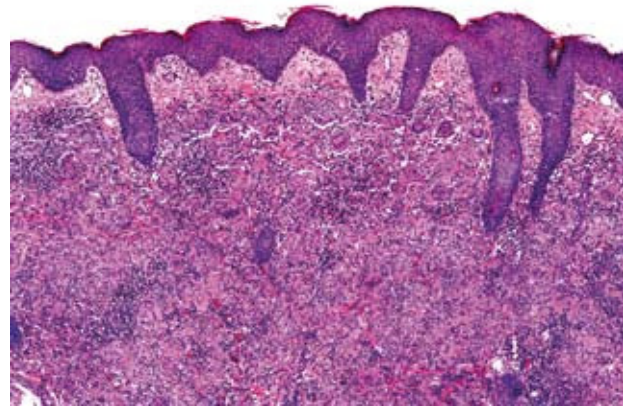


Figure 2. Hematoxylin-eosin, $\times 40$.

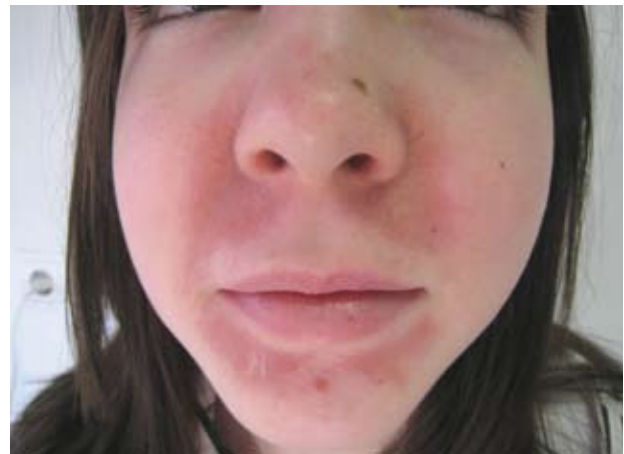

Figure 3.

Diagnosis

Childhood granulomatous periorificial dermatitis.

Clinical Course and Treatment

Topical metronidazole and oral tetracyclines were prescribed, but there was no improvement in the condition after 30 days. Treatment was changed to oral isotretinoin, which led to a deterioration of the lesions after 1 month; it was therefore decided to withdraw all medication. After 1 year of follow-up, there continues to be a mild erythema but the papules have disappeared (Figure 3).

Discussion

The first description of this disease was made by Gianotti et al¹ in 1970, who presented 5 children with an asymptomatic, granulomatous perioral rash. Williams et al² coined the acronym FACE (*Facial Afro-Caribbean Childhood Eruption*) on observing a higher prevalence in that race. Knautz and Leshner³ were the first to use the term childhood granulomatous periorificial dermatitis, based on the site of the lesions, the granulomas, and the onset during childhood. About 100 cases have been published to date.

Although the etiology of the disease is unknown, it has been related to the application of topical corticosteroids or irritants, and may be a nonspecific granulomatous inflammatory response.^{4,7} For many authors, childhood granulomatous periorificial dermatitis is a granulomatous variant of perioral dermatitis.⁷

The lesions are asymptomatic, monomorphic, and do not have an inflammatory appearance.^{4,7} They consist of small, yellowish papules that may coalesce, forming plaques; they are located in the central facial region (perioral, perinasal, and periocular).^{4,7} Lesions in sites other than the face are rare.

Histopathologically, the lesions are characterized by perifollicular and parafollicular noncaseating epithelioid granulomas, with multinuclear giant cells and lymphocytes.^{4,7} The infiltrate is sometimes more diffuse and the granulomas not clearly visible.⁷

The disease runs a self-limiting course; although the lesions can persist for years, they do not leave scars.^{4,5,7}

Although childhood granulomatous periorificial dermatitis may be considered a granulomatous variant of perioral dermatitis, it has a series of differentiating characteristics: onset during childhood, monomorphic, noninflammatory lesions, granulomas, and a minimal

response to treatment. The confusion that exists in the literature, in which conditions that do not present these characteristic are called childhood granulomatous periorificial dermatitis, has led to distortion of the clinical-pathologic criteria of this disease, confusing the differential diagnosis.

The periorificial site and the absence of erythema and telangiectasias distinguish childhood granulomatous periorificial dermatitis from granulomatous rosacea, which, furthermore, is not typically seen in children.⁶

Other differential diagnoses include childhood acne, factitious dermatitis caused by lip biting, sarcoidosis, granulosis rubra nasi, lupus miliaris disseminatus faciei, and familial juvenile systemic granulomatosis.⁶

Apart from avoiding possible triggers, the principal treatments used in childhood granulomatous periorificial dermatitis include topical and oral antibiotics (metronidazole, macrolides, and tetracyclines), although they have not been shown to alter the course of the disease.^{4,7} The use of isotretinoin in our patient led to deterioration.

Acknowledgments

To Dr. Luis Requena Caballero for the histological images.

Conflicts of Interest

The authors declare no conflicts of interest.

References

1. Gianotti F, Ermacora E, Benelli MG, Caputo R. Particulière dermatite péri-orale infantile: observations sur cinq cas. *Bull Soc Fr Dermatol Syphiliogr.* 1970;77:341.
2. Williams HC, Ashworth J, Pembroke AC, Breathnach SM. FACE-facial Afro-Caribbean childhood eruption. *Clin Exp Dermatol.* 1990;15:163-6.
3. Knautz MA, Leshner JL. Childhood granulomatous periorificial dermatitis. *Pediatr Dermatol.* 1996;13:131-4.
4. Torrelo A, Mediero IG, Zambrano A. Dermatitis perioral granulomatosa infantil. *Actas Dermosifiliogr.* 1996;87:626-8.
5. García Arpa M, Rodríguez Vázquez M, Delgado Portela M, Cortina de la Calle P, Romero Aguilera G. Dermatitis granulomatosa periorificial infantil. *Acta Pediatr Esp.* 2004;62:78-81.
6. Medina Castillo DE, Orozco la Roche JE, Beirana Palencia A, Alonzo-Romero Pareyon L. Enfermedad granulomatosa periorificial de la infancia. Estudio clínico de 10 casos. *Piel.* 2003;18:359-63.
7. Calzado L, Galera CM, Arrue I, Rodríguez-Peralto JL, Guerra A, Vanaclocha F. Dermatitis perioral granulomatosa infantil. *Actas Dermosifiliogr.* 2004;95:580-2.