

# ACTAS Derma-Sifiliográficas

Full English text available at  
[www.elsevier.es/ad](http://www.elsevier.es/ad)



## CONTROVERSIES IN DERMATOLOGY

# Surgical vs Nonsurgical Treatment of Basal Cell Carcinoma

I.R. Aguayo-Leiva\* L. Ríos-Buceta, and P. Jaén-Olasolo

*Servicio de Dermatología, Hospital Universitario Ramón y Cajal, Madrid, Spain*

Manuscript received February 13, 2010; accepted for publication June 22, 2010

### KEYWORDS

Carcinoma;  
Basal cell;  
Skin cancer;  
Treatment;  
Surgery

### PALABRAS CLAVE

Carcinoma;  
Basocelular;  
Cáncer de piel;  
Tratamiento;  
Cirugía

### Abstract

Numerous therapeutic options are now available for the treatment of basal cell carcinoma. However, few randomized controlled trials with 5-year follow-up have compared the effectiveness of the different treatments. Such a comparison is difficult, probably because efficacy depends on several factors: those related to the tumor, the patient, the technique, and the dermatologist's experience. We first describe the available therapeutic options, including certain innovative treatments. We have divided them into 2 main groups—surgical and nonsurgical—and focus on the indications, advantages, and disadvantages of each one, as well as on the cure and recurrence rates. Then, based on the evidence reviewed, we attempt to provide an outline of the therapeutic strategies recommended in basal cell carcinoma, and the approach to be used in specific situations. We also describe our own experience.

© 2010 Elsevier España, S.L. and AEDV. All rights reserved.

### Tratamiento quirúrgico vs. no quirúrgico en el carcinoma basocelular

### Resumen

El arsenal terapéutico para el tratamiento de los carcinomas basocelulares hoy en día es muy amplio. No obstante, existen pocos estudios controlados, aleatorizados con seguimiento a 5 años que comparen la eficacia de los diferentes tratamientos. Esto es difícil, debido probablemente a que la eficacia de los mismos depende de varios factores: los derivados del propio tumor, del paciente, de la técnica y del manejo de ella hecho por el dermatólogo. Describiremos en primer lugar las opciones terapéuticas con las que contamos, incluyendo además algunos tratamientos innovadores, dividiéndolas en dos grupos principales: quirúrgicos y no quirúrgicos, enfatizando en las indicaciones, ventajas y desventajas de cada tipo, así como las tasas de curación y recurrencia de los mismos.

\*Corresponding author.

E-mail address: [ingridaguayo77@hotmail.com](mailto:ingridaguayo77@hotmail.com)  
(I.R. Aguayo-Leiva).

Posteriormente con las evidencias presentadas intentaremos, de manera esquemática, exponer las estrategias terapéuticas recomendadas en cada caso, las actitudes a adoptar en determinadas situaciones así como nuestra propia experiencia.  
© 2010 Elsevier España, S.L. y AEDV. Todos los derechos reservados.

## Introduction

Basal cell carcinoma (BCC) is the most common malignant skin tumor in the white population. Sunlight is considered the main etiological factor leading to this malignant tumor, which can be locally destructive but metastasizes only very rarely. Over recent decades the incidence of BCC has increased worldwide. According to the 2008 statistics of the American Cancer Society, the annual incidence of nonmelanoma skin cancer is estimated at 1.3 million cases and BCC accounts for 75%.<sup>1</sup> The mean incidence reported in Spain is of 80 to 90 cases per 100 000 population per year,<sup>2</sup> but Bielsa et al<sup>3</sup> observed a higher incidence of 253 cases per 100 000 population per year in a Mediterranean population in Spain.

Therapeutic options for treating BCC encompass a variety of approaches. Although very few studies have compared the efficacy of these treatments, surgery and radiotherapy appear to be the most effective, with surgery having the lowest recurrence rate.<sup>4</sup>

## Factors Affecting the Choice of Therapeutic Approach

The aim of therapy in BCC is to eliminate the tumor with minimal loss of healthy skin, while preserving function and achieving a good cosmetic result. Treatment must be individualized and will be based on factors related to the tumor, the patient, and the dermatologist's experience.<sup>5</sup>

1. *Tumor-related factors:* These include anatomical site, size, definition of the margins, whether the lesion is a primary or a recurrence, whether or not the tumor appeared on a pre-existing lesion (radiation therapy

or chronic inflammation), histological type, and the presence or absence of perineural involvement.

2. *Patient-related factors:* Life-expectancy, life-altering diseases, and immunosuppression must be taken into account.
3. *Treatment-related factors:* These include the cure rate with each treatment, the surgeon's training and skill with the technique, preservation of function, technique-related morbidity, cost, and cosmetic result.

Based on the first 2 sets of factors, 2 groups with high risk and low risk of recurrence can be defined (Table 1, Figure 1). High-risk tumors, which are more likely to recur, therefore require more aggressive treatments. However, not all variables may be relevant in classifying a tumor as high or low risk.

Nonsurgical options for treating BCC are currently available in addition to the traditional surgical approaches; these less invasive methods have a good safety profile and sufficient follow-up has now been accumulated to enable us to compare them with standard treatments.

Considering both surgical and nonsurgical approaches to BCC treatment, our aim is to define the indications for each modality based on evidence available in the literature.

## Surgical Treatment

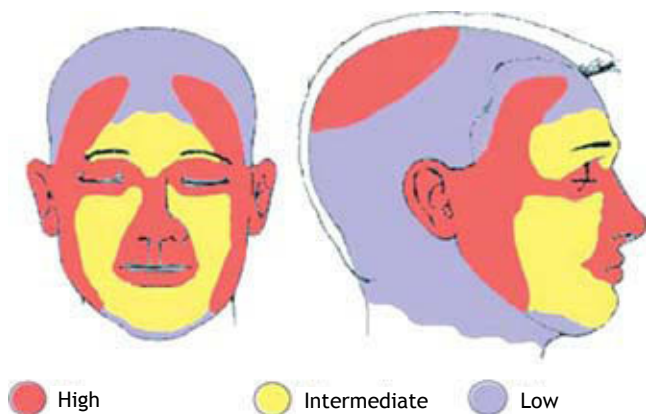
### Excisional Surgery

1. *Excisional surgery:* consists of the removal of the tumor with margins. According to the National Comprehensive Cancer Network (NCCN),<sup>6</sup> low-risk BCCs should be excised with 4-mm margins and high-risk lesions with 10-mm margins.

Surgery is considered the treatment of choice for BCC for 2 main reasons: it is associated with the highest cure

**Table 1** Risk Factors for Recurrence of Basal Cell Carcinoma

	Low Risk	High Risk
<i>Site/ Size</i>	Area L <20 mm Area M <10 mm Area H <6 mm	Area L ≥20 mm Area M ≥10 mm Area H ≥6 mm
<i>Borders</i>	Well defined	Poorly defined
<i>Primary vs recurrent</i>	Primary	Recurrent
<i>Immunosuppression</i>	No	Yes
<i>Site of prior radiation therapy</i>	No	Yes
<i>Histological pattern</i>	Nodular, superficial	Aggressive growth pattern: morpheaform, sclerosing, infiltrative, micronodular
<i>Perineural invasion</i>	Absent	Present



**Figure 1** Area H: mask area (central area of the face, eyelids, eyebrows, periorbital region, nose, lips [cutaneous and vermillion], chin, mandible, preauricular and postauricular areas), genitalia, hands, and feet. Area L: cheeks, forehead, scalp, and neck. Area M: Trunk and limbs.

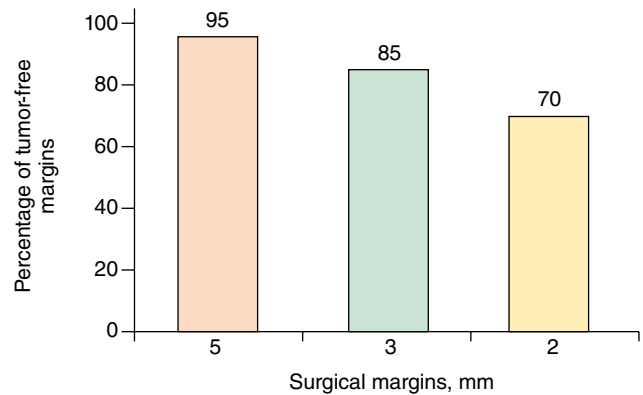
Source: Adapted from the NCCN 2009 Clinical Practice Guidelines in Oncology.<sup>6</sup>

rate and it allows for histological evaluation of the tumor margins. However, the sensitivity of conventional histology to detect residual tumor in small and well-defined BCCs that are excised with a peripheral margin of 2 mm is only 44%.<sup>7</sup> Despite this low sensitivity, histology study does reveal the presence of tumor in the resection margins in many cases. The rate of incomplete resection of BCC reported in retrospective studies varies from 6.3% to 25%, and in prospective studies from 2% to 18%.<sup>8</sup> A 5-year recurrence rate of 17% has been reported when there is involvement of the peripheral margins and of 33% when the deep margin is positive.<sup>9,10</sup>

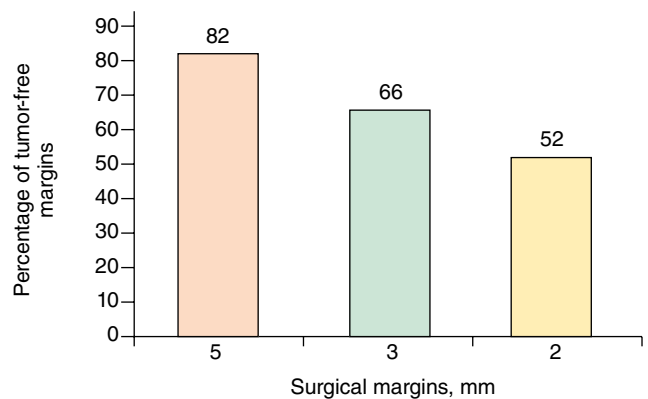
Different sizes of resection margins have been proposed based on the literature. In primary BCCs with a diameter of less than 2 cm, a nonaggressive histopathological pattern (nodular, superficial), and well-defined borders, surgical margins of 5 mm have been found to achieve negative histology in 95% of cases. However, this figure falls to 85% when margins are 3 mm and to 70% when margins are 2 mm (Figure 2).<sup>11-13</sup> When Griffiths et al<sup>12</sup> analyzed 1539 primary BCCs without specifying the histological subtype, they concluded that more than 70% of BCCs in areas of cosmetic importance (periorbital area, nose, cheeks, lips, chin, and neck) were completely excised with margins of less than 5 mm.

In BCCs with diameters of 1 to 2 cm and with an infiltrative histological pattern, negative margins were obtained in 82% by excision with 5-mm margins, in 66% with 3-mm margins, and in only 52% with 2-mm margins (Figure 3).<sup>11</sup> Some authors have therefore suggested that BCCs with an aggressive histological pattern (sclerodermiform, mixed infiltrative, or micronodular), a diameter greater than 2 cm, or recurrent lesions require minimum margins of 5 to 10 mm in order to achieve tumor-free margins in 95% of cases.<sup>14,15</sup>

The recurrence rates after excisional surgery for BCC vary from 1.3% to 10% in primary BCC and exceed 17% in recurrent BCC (Table 2).<sup>16,17</sup> When analyzing these



**Figure 2** Percentage of tumor-free margins according to the width of the resection margins in basal cell carcinomas less than 2 cm in diameter and with a nonaggressive histological pattern.



**Figure 3** Percentage of tumor-free margins according to the width of the resection margins in basal cell carcinomas less than 2 cm in diameter and with an infiltrative histological pattern.

**Table 2** Recurrence Rates of Primary and Recurrent Basal Cell Carcinomas Treated by Surgical Excision<sup>16,17</sup>

BCC	Recurrence Rate
Primary	1.3%-10%
Recurrent	>17%

Abbreviation: BCC, basal cell carcinoma.

recurrence rates, a number of tumor-related factors must be taken into account:

- Histological subtype: Su et al<sup>8</sup> looked at the rates of incomplete resection according to histological subtype and found the highest rates for infiltrative (62.8%), superficial (16%), and nodular (7.3%) subtypes. Staub et al<sup>18</sup> studied 674 primary BCCs treated by surgical excision and followed for 5 years, detecting a recurrence rate of 3.8%. The histological subtypes of these recurrent lesions were infiltrative (33%), nodular (25%), superficial (25%), and other (17%).

- b) Lesion size: In 1993, Silverman et al<sup>19</sup> treated 588 BCCs by surgical excision (without specifying the resection margins) and followed the patients for 5 years. For BCCs located on the head, they found recurrence rates of 3.2% for lesions less than 6 mm in diameter, 8% for those of 6 to 9 mm in diameter, and 9% for those with a diameter of 10 mm or larger.
- c) Anatomical site: For some years now, anatomical site has been a well-known risk factor for recurrence. The concept of the so-called mask area of the face dates from the year 1983, when it was discussed in a review by Swanson,<sup>20</sup> who had noted higher recurrence rates in the central area of the face; preauricular and postauricular areas; periorbital region, and on the eyelids and eyebrows; and on the nose, mandible, lips, and chin. The study by Silverman et al<sup>19</sup> found 5-year recurrence rates of 6.6% for tumors located on the head and 0.7% for tumors at other sites; this difference was statistically significant. Another study, published in 2005, included 1635 primary BCCs located on the head; these tumors were also treated by complete surgical excision by plastic surgeons and were followed at 5 years.<sup>17</sup> The reported recurrence rate was 1.3%, and two thirds of the recurrences occurred in lesions located in the temporal region and on the forehead.
- d) Primary vs recurrent: A large series of patients with a total of 5755 BCCs, two thirds of which were primary, were treated using various techniques—conventional surgery, curettage and electrodesiccation, radiation therapy.<sup>21</sup> After a follow-up of 5 years, the recurrence rate was 10.6% for primary BCCs and 15.4% for recurrent lesions. A study that compared recurrence rates in BCCs treated by conventional surgery reported a mean recurrence rate of 4.8% for primary lesions and 11.6% for recurrent tumors.<sup>19</sup>

2. *Mohs Surgery*: Described by Frederick Mohs in 1941, Mohs surgery is used to excise high-risk skin tumors and involves histological examination of borders. In contrast to other techniques for the treatment of skin cancer, Mohs surgery enables the evaluation of all borders. It also spares as much healthy tissue as possible and has the highest cure rates: 99% for primary tumors and 95% for recurrent lesions.<sup>5</sup> The main indications for Mohs surgery are listed in Table 3.

The majority of published series consistently show that large or recurrent tumors, those with an aggressive histological subtype, and lesions situated on embryonic fusion planes require more Mohs stages and have a greater

subclinical extension and likelihood of recurrence.<sup>22,23</sup> A systematic review of the literature led to the conclusion that Mohs surgery is associated with 5-year recurrence rates of approximately 1% to 3% in primary BCC and 5% to 7% in recurrent BCC.<sup>8</sup> A randomized controlled trial comparing Mohs surgery to conventional surgical excision of high-risk BCC tumors showed statistically significant differences in favor of Mohs surgery in the 5-year recurrence rate for recurrent BCCs but not for primary BCCs.<sup>16</sup> However, in that study it should be noted that some patients treated by surgical excision underwent re-excision using Mohs surgery when resection was incomplete; those patients were still included in the surgical excision group for the statistical analysis.

Mohs surgery has certain limitations: it requires specialized training, the operating time is longer, and the procedure is more costly, although skin preservation and the very low recurrence rates makes it cost-effective.<sup>23,24</sup>

## Nonsurgical Treatment

1. *Cryosurgery*: In cryosurgery the skin is frozen and thawed, leading to biological changes; the aim is to produce tissue necrosis. The technique is most commonly achieved through the use of either an aerosol or a cryoprobe. Cryosurgery is recommended in palpable, nodular, or ulcerated BCCs with well-defined borders and a diameter of less than 2 cm. It is particularly useful in those tumors that are located in areas with complex contours, on skin overlying bone or cartilage, and in senile patients or those with concomitant diseases.<sup>25</sup> It has the advantages of safety, speed, efficacy, low cost, and a satisfactory cosmetic result. The main disadvantage of cryosurgery is that histopathological assessment of the tumor margins cannot be performed. Careful curettage followed by 2 cycles of cryotherapy is associated with a minimal risk of recurrence<sup>26</sup>; in low-risk BCC the cure rate is 95% to 97% with this technique.<sup>27</sup> A recently published study of high-risk BCC treated using topical imiquimod for 2 to 5 weeks followed by cryosurgery (spray, 10-20 seconds, 2 cycles) and subsequent imiquimod treatment for a further 2 to 12 weeks achieved promising results, with an efficacy of 95% after 18 months of follow-up.<sup>28</sup>

2. *Curettage and Electrodesiccation*: This technique consists of curettage followed by electrodesiccation of the surgical site, with repetition of the procedure as many times as is considered necessary. Curettage and electrodesiccation is only recommended for well-defined low-risk lesions, such as BCCs that are superficial or nodular, have a diameter less than 1 cm, are limited to the upper dermis, and are situated in a low-risk area of hairless skin (because the tumor may not be completely eliminated if it has infiltrated follicular structures). If involvement of the subcutaneous tissue is observed during the procedure, surgical excision must be performed.<sup>6</sup> Curettage and electrodesiccation is a simple and cheap technique that achieves good functional and cosmetic results. Its drawbacks are that histopathology of the margins cannot be performed and healing is by second intention. In the right case and in expert hands, cure rates of up to 97% can be achieved in low-risk primary BCC,

**Table 3** Indications for Mohs Surgery

Site: on or around the eyelids, ears, nose, lips, nasolabial fold, forehead, scalp, or embryonic fusion planes
Histological subtypes: sclerosing, infiltrative, micronodular
Recurrence
Size: >2 cm
Perineural involvement
Poorly defined margins in a high-risk area

but the cure rate is much lower in recurrent or high-risk tumors.<sup>5,29</sup> A recent study of curettage comparing disposable vs reusable curettes in 405 primary BCCs, the majority of which were superficial or nodular lesions less than 1 cm in diameter located on the head and neck, reported a cure rate of 80% at 5 years, with no statistically significant differences between the 2 types of curette.

**3. Photodynamic Therapy:** Photodynamic therapy (PDT) is a relatively new treatment modality that is based on the application of a photosensitizing substance followed by illumination of the lesion with visible light in order to produce activated oxygen molecules that selectively destroy the target cells. Methyl aminolevulinate (MAL) offers the advantage of being a more lipophilic agent that achieves greater penetration than 5- $\alpha$ -aminolevulinic acid.<sup>31</sup> According to the 2007 clinical guidelines of the International Society for Photodynamic Therapy (I-PDT), PDT with MAL is a good option in superficial BCC because of its efficacy after 5 years of follow-up, and its excellent cosmetic result (evidence level 1a).<sup>32</sup> Furthermore, this approach is particularly useful for large or multiple lesions and those situated in areas in which healing may be problematic. In BCC, the most widely recommended protocol calls for 2 sessions. Basset-Seguin et al<sup>33</sup> compared PDT with cryotherapy in superficial BCC, finding cure rates of 78% and 80%, respectively, and better cosmetic results in the PDT group. In the case of nodular BCC, the main problem concerns penetration of both the photosensitizer and the light to a sufficient depth to treat the deepest part of the tumor. Topical MAL has been shown to penetrate to a depth of 2 mm in nodular BCC. The 2007 I-PDT clinical guidelines therefore recommend this therapy as an effective and safe therapeutic option in nodular BCC, preferably for thin lesions, with the advantage of a good cosmetic result (evidence level 1a).<sup>32</sup> At 3 months, the complete response rate of nodular BCC to PDT with red light and MAL was 91%, compared to 98% in a group treated by surgery; the 5-year recurrence rates were 14% and 2%, respectively.<sup>34</sup> However, the cosmetic outcome was excellent in 85% of patients treated with PDT compared to 19% of those treated by surgery.

The lack of histological confirmation is once again a disadvantage on comparison with surgery, and careful follow-up must therefore be performed to detect recurrence. The technique is contraindicated in infiltrative, pigmented, or recurrent BCC.<sup>32</sup>

**4. Radiation Therapy:** Radiation therapy has been used for many years and was the first-line therapy for BCC until only a few years ago. However, for a number of reasons it has been losing ground in the management of this tumor. In the latest NCCN guidelines<sup>6</sup> its use was a subject of debate. This technique is particularly indicated for tumors more than 15 mm in diameter in high-risk areas and those more than 20 mm in diameter in medium-risk areas; it is not indicated for the treatment of low-risk tumors situated on the trunk, limbs, or genitalia.<sup>6</sup> Its main drawback is the lack of evaluation of margins. The principal revisions report 5-year cure rates of 91.3% in primary BCC and 90.2% in recurrent tumors.<sup>5</sup> A study that compared surgical excision of 174 BCCs (primary tumors less than 4 cm in diameter, located on the face, and with nonaggressive histological

characteristics) with radiation therapy of 173 BCCs of similar characteristics, detected a 4-year recurrence rate of 0.7% in the surgical group and of 7.5% in the radiation therapy group.<sup>35</sup> The cosmetic results at 4 years were significantly better in the patients treated using surgery. Radiation therapy is therefore an effective treatment option for primary or recurrent tumors in patients who are not surgical candidates and in patients over 60 years of age (because of the probable long-term sequelae), and as adjuvant therapy after surgical treatment or when perineural invasion is detected; it is contraindicated in patients with genetic conditions that predispose to skin cancer (xeroderma pigmentosa, basal cell nevus syndrome) or connective tissue diseases (scleroderma).<sup>6</sup>

**5. Imiquimod:** Imiquimod is a toll-like receptor 7 agonist that modifies the immune response and has antiviral and antitumor activity; it acts through induction of the local release of interferon- $\alpha$ , tumor necrosis factor- $\alpha$ , and other cytokines and also induces tumor cell apoptosis. Topical imiquimod is approved for the treatment of superficial BCC; a regimen of 5 applications a week for 6 weeks is prescribed with the purpose of achieving a therapeutic balance between efficacy and patient tolerance of the local inflammatory reactions. Long-term data on clinical recurrence rates are limited. An open multicenter study including 182 patients with superficial BCC, using the regimen of 5 applications a week for 6 weeks, resulted in an initial response to treatment in 89.6% of patients<sup>36</sup>; these patients were then included in a 5-year follow-up phase with annual evaluations. Overall treatment success (no clinical evidence of recurrence) estimated using the Kaplan-Meier method using an intention-to-treat analysis of the entire study population was 77.9%; this figure rose to 80.9% when histology findings (negative results in 4 cases with clinical suggestion of tumor) were taken into account. The majority of recurrences occurred within the first year.

In a study of 102 patients with nodular BCC less than 1.5 cm in diameter treated with imiquimod 3 times a week for 8 to 12 weeks followed by excision biopsy of the primary tumor with a 3 mm margin at 8 weeks (with documented and photographed primary tumors) found that only 90 patients completed the treatment.<sup>37</sup> Clinical resolution of the lesions was achieved in 78% of cases, and histological resolution in 64%. The best response occurred in lesions of less than 1 cm in diameter.

Recent studies have tested the combination of curettage followed by the topical application of imiquimod. Tillman et al<sup>38</sup> studied 90 patients with a total of 101 BCCs with a mean diameter of 1 cm. The majority (66%) were located in high-risk anatomical regions (mainly on the nose) and were of the nodular subtype (61%). Treatment was performed with curettage followed by 5% imiquimod cream 5 times a week for 6 weeks, with a follow-up of 36 months. The rate of clinical resolution was 96%, and the cosmetic result was excellent.

**6. Laser:** Laser therapy consists of the application of a source of coherent or noncoherent light in order to eliminate tumors. Various types of laser are used for the ablation of tumors; some instruments are tissue-selective. This modality is indicated for the treatment of low-risk tumors, but has the disadvantage that histological

evaluation is not possible. Cosmetic results are very good, however. Few large studies of cure rates with this technique been undertaken; most of the studies done have involved pulsed dye or carbon dioxide lasers, and information on long-term follow-up is not available.<sup>39</sup> Moskalik et al<sup>40</sup> recently published a study of the treatment of 3346 primary facial BCCs with a diameter of less than 2 cm, without specifying the histological type, and 188 well-defined recurrent BCCs that developed after treatment by other techniques. They used high-energy pulsed neodymium and neodymium:yttrium aluminium garnet (Nd:YAG) lasers, with a single treatment session in the majority of the cases. Only 75% of patients were followed for a full 5 years (range of follow-up, 3 months to 5 years). The recurrence rates were 1.8% in BCCs treated with the neodymium laser, 2.5% in BCCs treated with the Nd:YAG laser, and 3.7% in recurrent BCCs treated with the neodymium laser; the majority of recurrences developed in the first year after treatment. Cosmetic results were acceptable.

**7. 5-Fluorouracil:** Up to now, 5-fluorouracil (5-FU) has been the most frequently studied topical chemotherapeutic agent. It acts by blocking DNA synthesis through inhibition of the enzyme thymidylate synthase. It is approved for the treatment of superficial BCC, at a concentration of 5%, with application twice a day for a minimum of 6 weeks; cure rates are of approximately 93%.<sup>41</sup> An important disadvantage is the local inflammatory reaction, which can be intense. Studies have also been performed with the intralesional injection of 0.5 mL of 5-FU, administered once a week for 6 weeks, achieving cure rates of 80%.<sup>42</sup> A recent literature review comparing the use of imiquimod and topical 5-FU in the treatment of BCC in studies with acceptable levels of evidence reported cure rates of 69% (2 years) to 91% (5 years) for imiquimod in superficial BCC, 53% in nodular BCC, and 56% in infiltrative BCC. In a study of 31 superficial BCCs, the use of topical 5-FU twice a day for 11 weeks achieved cure rates of 90%, although there was no long-term follow-up.<sup>43</sup> The authors therefore recommended using imiquimod and topical 5-FU for treating small superficial BCCs in low-risk areas and in patients who are not candidates for surgical treatment.

**8. Interferon:** The intralesional injection of interferon (INF) induces apoptosis of BCC cells through the CD95 receptor-ligand interaction pathway, stimulation of interleukin 2, and inhibition of interleukin 10. This treatment is only used in specific circumstances, such as in patients who are not candidates for surgery, have a debilitating disease, or when surgery could be disfiguring; 3 injections per week are given for 3 weeks.<sup>44</sup> Complete response rates of 50% to 80% have been reported, though these results may not persist over time with high-risk tumors. The disadvantages of this treatment are the low cure rates, the need for multiple intralesional injections, and the fact that interferon can cause influenza-like symptoms.<sup>45</sup> A recent, prospective, open-label study evaluated the combination of intralesional and perilesional IFN- $\alpha$  and IFN- $\gamma$  in large, aggressive, recurrent BCCs resistant to other treatments (surgery, radiation therapy, chemotherapy). The IFNs were administered 3 times a week for 3 weeks

and skin biopsy was performed 13 weeks after treatment had been completed. A total of 12 BCCs were included. Complete elimination of the tumor was achieved in 47% of cases, a 30% reduction in the size of the tumor in 40% of cases, and in 13% the lesion remained stable at 38 months of follow-up.<sup>46</sup>

**9. New Therapies: Inhibition of the Hedgehog Pathway:** Although the discovery and study of the Sonic-Hedgehog (Hh) signaling pathway revealed the important role it plays in the development of the embryo, it has more recently been implicated in a wide variety of tumors, including BCC. The pathway consists of intercellular signaling molecules that modulate the activity of transcription factors involved in cell development.<sup>47</sup> In 2002, it was reported that cyclopamine, a steroid alkaloid with teratogenic properties blocks the Hh signaling pathway.<sup>48</sup> A new drug, GDC-0449, was then developed through chemical optimization to produce a stronger and more selective inhibition of the Hh pathway; GDC-0449 has more favorable pharmaceutical properties than cyclopamine. A recent open-label multicenter study looked at the efficacy and safety of this drug in patients with metastatic or locally advanced BCC refractory to standard therapies.<sup>47</sup> The trial enrolled 33 patients, 18 with metastatic disease and 15 with locally advanced tumors. The recommended dose in the second stage of the 2-stage study was 150 mg/d by mouth and the mean duration of treatment was 9.8 months. Response to treatment was demonstrated in 50% of patients with metastatic disease and in 60% of those with locally advanced tumors. Thus, of the 33 patients enrolled, 55% presented a response to GDC-0449. In conclusion, based on that study, this new drug may be useful mainly in inoperable tumors; more importantly, it opens a new approach to the treatment of BCC.

**10. Cashew Nut Extract:** SA-3C is a compound that has recently been isolated from the kernel of the cashew nut (*Semecarpus anacardium*); SA-3C has significant antitumor activity in monotherapy and combined therapy.<sup>49</sup> In a surgery department of Hospital General de Filipinas, an open-label prospective study was conducted in 36 patients with large BCCs on the middle third of the face. Cashew nut extract was applied every 1 to 2 weeks as required. After a mean of 7 applications, all the lesions were undetectable on physical examination. Sixteen of the 36 patients had had no recurrences at 5 years.<sup>50</sup>

## Discussion

Even though BCC is considered the most common tumor, there are few prospective randomized trials comparing treatment results at 5-years—a key period because 82% of recurrences occur within the first 5 years. A systematic review of the literature to evaluate recurrence rates with different treatments found that a comparison could not be performed due to a lack of uniformity between studies<sup>51</sup>; however, based on the available data, the authors concluded that Mohs surgery presented the lowest recurrence rates, followed, in order, by conventional surgery, cryosurgery, and curettage with electrodesiccation. Rowe et al<sup>52</sup> reviewed trials comparing different treatments for primary BCC,

selecting only trials with 5-year follow-up. They reported the following recurrence rates: Mohs surgery, 1%; cryosurgery, 7.5%; curettage and electrodesiccation, 7.7%; radiation therapy, 8.7%; and surgical excision, 10%. The same authors compared the reported recurrence rates in recurrent BCC after 5 years of follow-up, finding the following rates: Mohs surgery, 5.6%; radiation therapy, 9.8%; surgical excision, 17.4%; and curettage and electrodesiccation, 40%.<sup>53</sup>

The therapeutic regimens for the treatment of low-risk and high-risk BCC recommended by the NCCN 2009 guidelines<sup>6</sup> are shown in Figures 4 and 5. Those guidelines suggest that topical treatments should be reserved for low-risk tumors. The treatment of aggressive tumors with other types of therapy is only justified if surgery or radiation therapy is contraindicated or is not feasible based on patient factors. Mosterd et al,<sup>54</sup> in a recent review of randomized controlled trials, concluded that conventional surgery is the treatment of choice for BCC and that Mohs surgery is preferable for recurrent BCC on the face and for aggressive histological subtypes. Those authors also stated that radiation therapy is a noninvasive option that is effective for nodular BCC and aggressive histological subtypes, and that selected low-risk BCCs can be treated with nonaggressive therapies such as PDT or imiquimod.

Although we consider the NCCN clinical guidelines to be a very good starting point, we would like to make 2 comments:

a) The surgical margins for the excision of high-risk BCC are not defined in those guidelines (except for tumors larger than 20 mm in area L). We do not support the idea of pre-established margins (5-10 mm) for

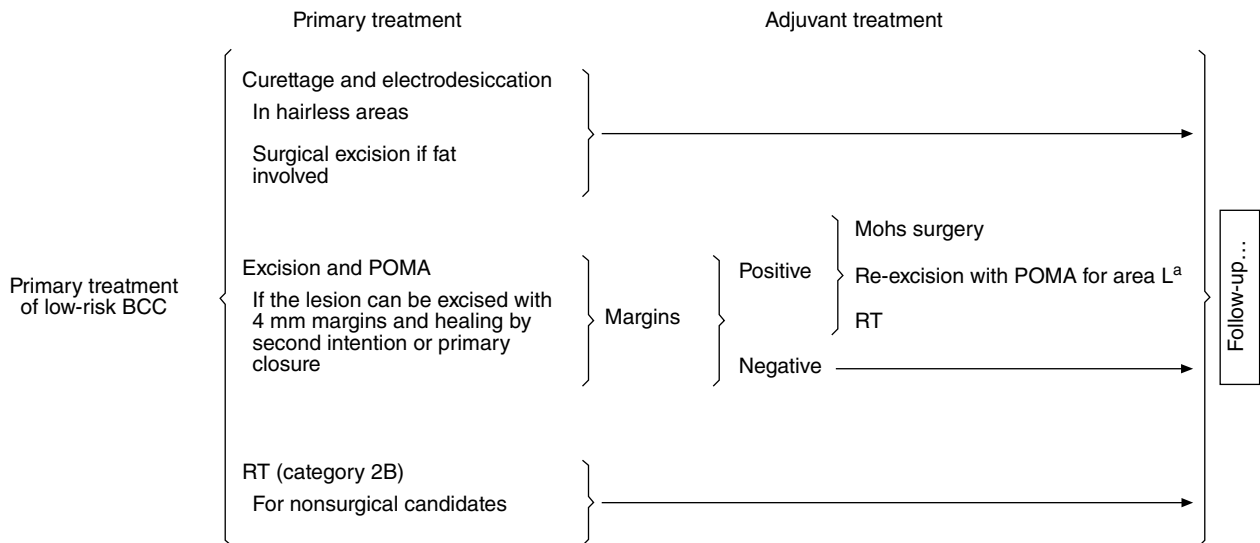
all high-risk tumors, as a number of factors must be taken into account. In particular, a detailed clinical-histological evaluation of each type of tumor should be undertaken.

b) A BCC is classed as primary or recurrent not as a function of its intrinsic nature, but rather because of a failure of the previous treatment technique. We therefore believe that the modality chosen to treat a recurrence will depend on which technique failed. The aggressiveness of a tumor does not depend on the technique used; however, recurrence of a BCC after excisional surgery with a 5 mm margin will often indicate greater aggressiveness than if the recurrence occurs after nonsurgical treatment.

We consider using nonsurgical therapies (imiquimod, PDT, curettage and electrodesiccation, among others) in primary, superficial BCC and in some cases of small nodular BCC. Conventional surgery and Mohs surgery are our first choices for infiltrative or recurrent tumors, and we reserve radiation therapy for cases in which surgery is contraindicated, usually because of the patient's physical condition (Figures 6 and 7).

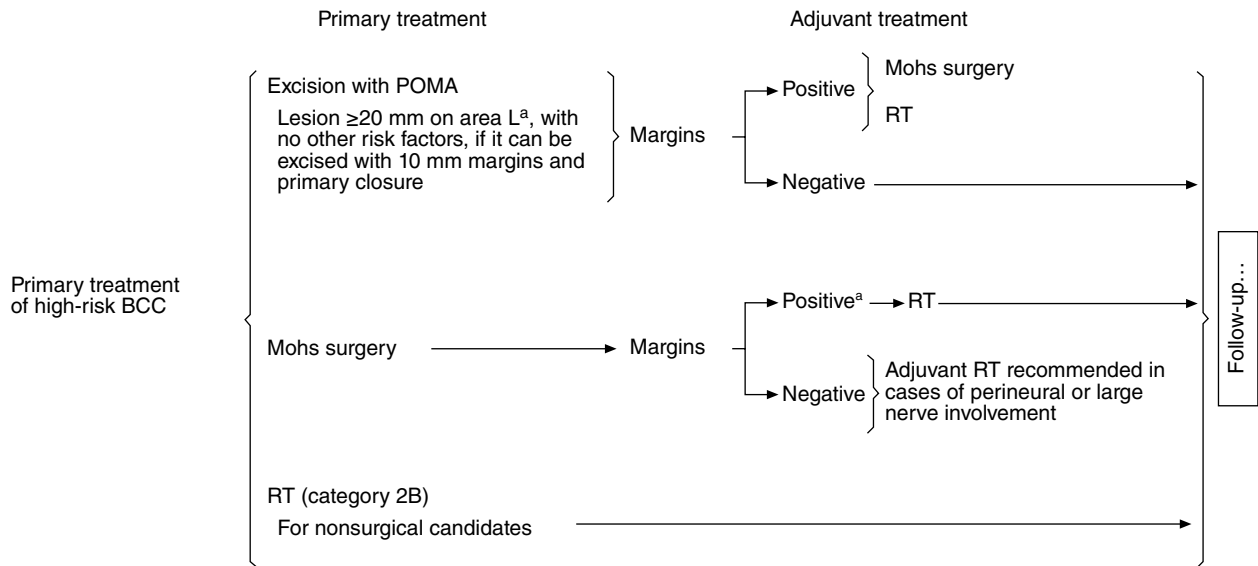
### Conclusions

Despite there being few studies that compare surgical and nonsurgical therapies for BCC, it is clear that surgery is associated with the lowest recurrence rates. However, the nonsurgical option is becoming more important in those patients who are not candidates for surgery but who



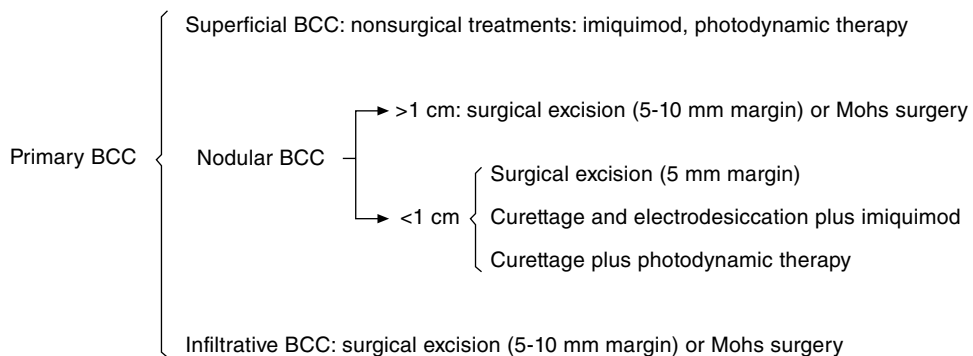
<sup>a</sup>Area L: trunk and limbs.  
Adapted from the National Comprehensive Cancer Network 2009 Clinical Practice Guidelines in Oncology.<sup>6</sup>  
BCC indicates basal cell carcinoma; POMA, postoperative margin assessment; RT, radiation therapy.

**Figure 4** Primary treatment of low-risk basal cell carcinoma.



<sup>a</sup>Area L: trunk and limbs.  
<sup>b</sup>Negative margins not achieved by Mohs surgery or by more extensive surgical procedures.  
 BCC indicates basal cell carcinoma; POMA, postoperative margin assessment; RT, radiation therapy.  
 Adapted from the National Comprehensive Cancer Network 2009 Clinical Practice Guidelines in Oncology.<sup>6</sup>

**Figure 5** Primary treatment of high-risk basal cell carcinoma.



BCC indicates basal cell carcinoma.

**Figure 6** Treatment of primary basal cell carcinoma.

might benefit from nonsurgical monotherapy or combined therapies.

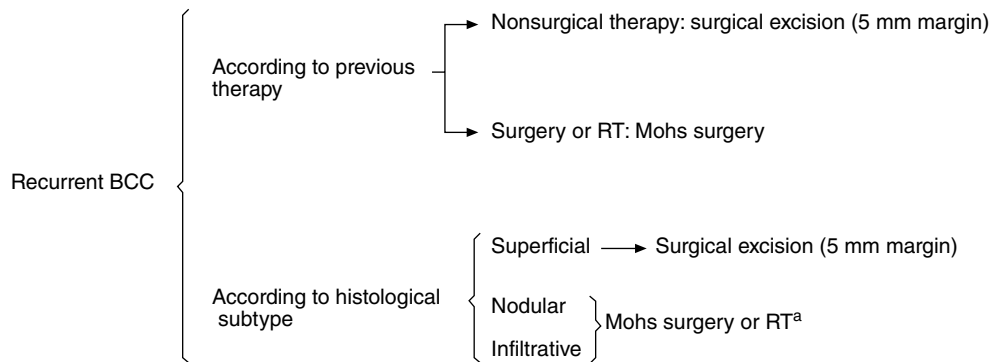
**Conflict of Interest**

The authors declare that they have no conflicts of interest.

**References**

1. Jemal A, Siegel R, Ward E, Hao Y, Xu J, Murray T, et al. Cancer statistics 2008. CA Cancer J Clin. 2008;58:71-96.
2. Técnicas avanzadas de Investigación en Servicios de Salud (TAISS). Aproximación a la incidencia de cáncer de piel en cuatro provincias españolas. Versión 1. 26 de marzo del 2007.
3. Bielsa I, Soria X, Esteve M, Ferrándiz C, Skin Cancer Study Group of Barcelonès Nord. Population-based incidence of basal





<sup>a</sup>RT reserved for cases in which surgery is contraindicated.  
BCC indicates basal cell carcinoma; RT, radiation therapy.

**Figure 7** Treatment of recurrent basal cell carcinoma.

- cell carcinoma in a Spanish Mediterranean area. *Br J Dermatol.* 2009;161:1341-6.
- Bath-Hextall FJ, Perkins W, Bong J, Williams HC. Interventions for basal cell carcinoma of the skin. *Cochrane Database Syst Rev.* 2007;CD003412.
  - Ríos-Buceta L, Picoto A. Cirugía de Mohs. *Actas Dermosifiliogr.* 2003;94:503-23.
  - NCCN Clinical Practice Guidelines in Oncology TM v.1.2009. Basal Cell and Squamous Cell Skin Cancers. National Comprehensive Cancer Network, Inc. [Cited 26/11/2008]. Available from: <http://www.nccn.org>.
  - Kimyai-Asadi A, Goldberg LH, Jih MH. Accuracy of serial transverse cross-sections in detecting residual basal cell carcinoma at the surgical margins of an elliptical excision specimen. *J Am Acad Dermatol.* 2005;53:469-74.
  - Su SY, Giorlando F, Ek EW, Dieu T. Incomplete excision of basal cell carcinoma: a prospective trial. *Plast Reconstr Surg.* 2007;120:1240-8.
  - Liu FF, Maki E, Warde P, Payne D, Fitzpatrick P. A management approach to incompletely excised basal cell carcinomas of skin. *Int J Radiat Oncol Biol Phys.* 1991;20:423-8.
  - Ríos-Buceta L. Management of basal cell carcinomas with positive margins. *Actas Dermosifiliogr.* 2007;98:679-87.
  - Breuninger H, Dietz K. Prediction of subclinical tumor infiltration in basal cell carcinoma. *J Dermatol Surg Oncol.* 1991;17:574-8.
  - Griffiths RW, Suvarna SK, Stone J. Basal cell carcinoma histological clearance margins: an analysis of 1539 conventionally excised tumours. Wider still and deeper? *J Plast Reconstr Aesthet Surg.* 2007;60:41-7.
  - Kimyai-Asadi A, Alam M, Goldberg LH, Peterson SR, Silapunt S, Jih MH. Efficacy of narrow-margin excision of well-demarcated primary facial basal cell carcinomas. *J Am Acad Dermatol.* 2005;53:464-8.
  - Burg G, Hirsch RD, Konz B, Braun-Falco O. Histographic surgery: accuracy of visual assessment of the margins of basal-cell epithelioma. *J Dermatol Surg.* 1975;1:21-4.
  - Goldberg DP. Assessment and surgical treatment of basal cell skin cancer. *Clin Plast Surg.* 1997;24:673-86.
  - Mosterd K, Krekels GA, Nieman FH, Ostertag JU, Essers BA, Dirksen CD, et al. Surgical excision versus Mohs' micrographic surgery for primary and recurrent basal-cell carcinoma of the face: a prospective randomised controlled trial with 5-years' follow-up. *Lancet Oncol.* 2008;9:1149-56.
  - Griffiths RW, Suvarna SK, Stone J. Do basal cell carcinomas recur after complete conventional surgical excision? *Br J Plast Surg.* 2005;58:795-805.
  - Staub G, Revol M, May P, Bayol JC, Verola O, Servant JM. Excision skin margin and recurrence rate of skin cancer: a prospective study of 844 cases. *Ann Chir Plast Esthet.* 2008;53:389-98.
  - Silverman MK, Kopf AW, Bart RS, Grin CM, Levenstein MS. Recurrence rates of treated basal cell carcinomas. Part 3: Surgical excision. *J Dermatol Surg Oncol.* 1992;18:471-6.
  - Swanson NA. Mohs surgery. Technique, indications, applications, and the future. *Arch Dermatol.* 1983;119:761-73.
  - Silverman MK, Kopf AW, Grin CM, Bart RS, Levenstein MJ. Recurrence rates of treated basal cell carcinomas. Part 1: Overview. *J Dermatol Surg Oncol.* 1991;17:713-8.
  - Alonso T, Sánchez P, González A, Ingelmo J, Ruiz I, Delgado S, et al. Cirugía Micrográfica de Mohs: nuestros primeros cien pacientes. *Actas Dermosifiliogr.* 2008;99:275-80.
  - Smeets NW, Kuijpers DI, Nelemans P, Ostertag JU, Verhaegh ME, Krekels GA, et al. HA. Mohs' micrographic surgery for treatment of basal cell carcinoma of the face-results of a retrospective study and review of the literature. *Br J Dermatol.* 2004;151:141-7.
  - Tierney EP, Hanke CW. Cost effectiveness of Mohs micrographic surgery: review of the literature. *J Drugs Dermatol.* 2009;8:914-22.
  - Dachów-Siwiéc E. Cryosurgery in the treatment of skin cancers: Indications and Management. *Clin Dermatol.* 1990;8:80-5.
  - Guevara-Gutiérrez E, García-Silva C. Curetaje y Criocirugía en el tratamiento del carcinoma basocelular: resultado del seguimiento a cinco años. *Piel.* 2001;16:439-43.
  - Holt PJA. Cryotherapy for skin cancer: results over a 5-year period using liquid nitrogen spray cryosurgery. *Br J Dermatol.* 1988;119:231-40.
  - Gaitanis G, Nomikos K, Vava E, Alexopoulos E, Bassukas I. Immunocryosurgery for basal cell carcinoma: results of a pilot, prospective, open-label study of cryosurgery during continued imiquimod application. *J Eur Acad Dermatol Venereol.* 2009;23:1427-31.
  - Spiller WF, Spiller RF. Treatment of basal cell epithelioma by curettement and electrodesiccation. *J Am Acad Dermatol.* 1984;11:808-14.
  - Julian C, Bowers PW, Pritchard C. A comparative study of the effects of disposable and Volkmann spoon curettes in the

- treatment of basal cell carcinoma. *Br J Dermatol.* 2009;161:1407-9.
31. Larkö O. Photodynamic therapy. *Australas J Dermatol.* 2005;46:S1-2. discussion S23-5
  32. Braathen LR, Szeimies RM, Basset-Seguín N, Bissonnette R, Foley P, Pariser D, et al. Guidelines on the use of photodynamic therapy for nonmelanoma skin cancer: An international consensus. *J Am Acad Dermatol.* 2007;56:125-43.
  33. Basset-Seguín N, Ibbotson SH, Emtestam L, Tarstedt M, Morton C, Maroti M, et al. Topical methyl aminolaevulinate photodynamic therapy versus cryotherapy for superficial basal cell carcinoma: a 5 year randomized trial. *Eur J Dermatol.* 2008;18:547-53.
  34. Rhodes LE, de Rie M, Enström Y, Groves R, Morken T, Goulden V, et al. Photodynamic therapy using topical methyl aminolevulinic acid vs surgery for nodular basal cell carcinoma: results of a multicenter randomized prospective trial. *Arch Dermatol.* 2004;140:17-23.
  35. Avril MF, Auperin A, Margulis A, Gerbaulet A, Du villard P, Benhamou E, et al. Basal cell carcinoma of the face: surgery or radiotherapy? Results of a randomized study. *Br J Cancer.* 1997;76:100-6.
  36. Gollnick H, Barona CG, Frank RG, Ruzicka T, Megahed M, Maus J, et al. Recurrence rate of superficial basal cell carcinoma following treatment with imiquimod 5% cream: conclusion of a 5-year long-term follow-up study in Europe. *Eur J Dermatol.* 2008;18:677-82.
  37. Eigentler TK, Kamin A, Weide BM, Breuninger H, Caroli UM, Möhrle M, et al. A phase III, randomized, open label study to evaluate the safety and efficacy of imiquimod 5% cream applied thrice weekly for 8 and 12 weeks in the treatment of low-risk nodular basal cell carcinoma. *J Am Acad Dermatol.* 2007;57:616-21.
  38. Tillman DK, Carroll MT. A 36-month clinical experience of the effectiveness of curettage and imiquimod 5% cream in the treatment of basal cell carcinoma. *J Drugs Dermatol.* 2008;7:S7-S14.
  39. Shah SM, Konnikov N, Duncan LM, Tannous ZS. The effect of 595 nm pulsed dye laser on superficial and nodular basal cell carcinomas. *Lasers Surg Med.* 2009;41:417-22.
  40. Moskalik K, Kozlov A, Demin E, Boiko E. The efficacy of facial skin cancer treatment with high-energy pulsed neodymium and Nd:YAG lasers. *Photomed Laser Surg.* 2009;27:345-9.
  41. McGillis S, Fein H. Topical treatment strategies for non-melanoma skin cancer precursor lesions. *Semin Cutan Med Surg.* 2004;23:174-83.
  42. Orenberg EK, Miller BH, Greenway HT, Koperski JA, Lowe N, Rosen T, et al. The effect of intralesional 5-fluorouracil therapeutic implant (MPI 5003) for treatment of basal cell carcinoma. *J Am Acad Dermatol.* 1992;27:723-8.
  43. Love WE, Bernhard JD, Bordeaux JS. Topical imiquimod or fluorouracil therapy for basal and squamous cell carcinoma: a systematic review. *Arch Dermatol.* 2009;145:1431-8.
  44. Gross K, Kircik L, Kricorian G. 5% 5-Fluorouracil cream for the treatment of small superficial Basal cell carcinoma: efficacy, tolerability, cosmetic outcome, and patient satisfaction. *Dermatol Surg.* 2007;33:433-9.
  45. Neville JA, Welch E, Leffell DJ. Management of nonmelanoma skin cancer in 2007. *Nat Clin Pract Oncol.* 2007;4:462-9.
  46. Anasagasti-Angulo L, García-Vega Y, Barcelona-Perez S, López-Saura P, Bello-Rivero I. Treatment of advanced, recurrent, resistant to previous treatments basal and squamous cell skin carcinomas with a synergistic formulation of interferons. Open, prospective study. *BMC Cancer.* 2009;9:262.
  47. Von Hoff DD, LoRusso PM, Rudin CM, Reddy JC, Yauch RL, Tibes R, et al. Inhibition of the hedgehog pathway in advanced basal-cell carcinoma. *N Engl J Med.* 2009;361:1164-72.
  48. Chen JK, Taipale J, Cooper MK, Beachy PA. Inhibition of hedgehog signaling by direct binding of cyclopamine to Smoothened. *Genes Dev.* 2002;16:2743-8.
  49. Nair PK, Melnick SJ, Wnuk SF, Rapp M, Escalon E., Ramachandran C. Isolation and characterization of an anticancer catechol compound from *Semecarpus anacardium*. *J Ethnopharmacol.* 2009;122:450-6.
  50. Talens E, Ocampo O, de la Paz D, Estrada H, Tica P, de la Cruz R. *Anacardium occidentale* (Linn.) Cashew nut extract (De BCC) in the treatment of basal cell carcinoma. 12th World Congress on Cancers of the Skin. Tel Aviv, 2009.
  51. Thissen MR, Neumann MH, Schouten LJ. A systematic review of treatment modalities for primary basal cell carcinomas. *Arch Dermatol.* 1999;135:1177-83.
  52. Rowe DE, Carroll RJ, Day CL. Long-term recurrence rates in previously untreated (primary) basal cell carcinoma: implications for patient follow-up. *J Dermatol Surg Oncol.* 1989;15:315-28.
  53. Rowe DE, Carroll RJ, Day CL. Mohs surgery is the treatment of choice for recurrent (previously treated) basal cell carcinoma. *J Dermatol Surg Oncol.* 1989;15:424-31.
  54. Mosterd K, Arits AH, Thissen MR, Kelleners-Smeets NW. Histology-based treatment of basal cell carcinoma. *Acta Derm Venereol.* 2009;89:454-8.