

CASE AND RESEARCH LETTERS

Idiopathic Facial Aseptic Granuloma[☆]

Granuloma aséptico facial idiopático

To the Editor:

Idiopathic facial aseptic granuloma (IFAG) is a pediatric condition first described in 1999 by a group of French dermatologists who used the name *pyodermite froide* because of the lesion's resemblance to an abscess, although with mild signs of inflammation.^{1,2} The condition is characterized by the appearance of 1 or more painless red to violaceous nodules on the face, typically located on the cheeks or eyelids.¹ The lesions are benign, last from a few months to a year, and usually heal without leaving a scar.²

Histologic examination reveals a granulomatous inflammatory response similar to that observed in granulomas caused by foreign bodies or infectious agents such as mycobacteria.² Ultrasound studies reveal a solid hypochoic lesion without calcium deposits.³

We present the case of a 2-year-old girl with no past medical history of interest who was referred to our clinic because of an asymptomatic nodular lesion on the left cheek that had appeared approximately 2 months before the consultation (Fig. 1). Physical examination revealed a red to violaceous nodule of approximately 1 cm in diameter; the painless lesion was nonfluctuant on palpation and no regional lymph node involvement was observed. When questioned, the infant's mother did not recall any insect bite or trauma at the site.

Cultures for bacteria, fungi, and mycobacteria were negative. Histopathologic study of a 3-mm punch biopsy of the lesion revealed marked inflammation affecting the full thickness of the dermis. The inflammatory infiltrate was composed of histiocytes, either isolated or forming poorly defined granulomas, and some multinucleated giant cells interspersed with lymphocytes, plasma cells, and neutrophils. No suppurative granulomas were observed. In addition to hematoxylin-eosin staining, other special techniques involving staining with methenamine silver, periodic acid Schiff, Gram, Ziehl-Neelsen and Fite Faraco were used to rule out an infectious etiology (Fig. 2).

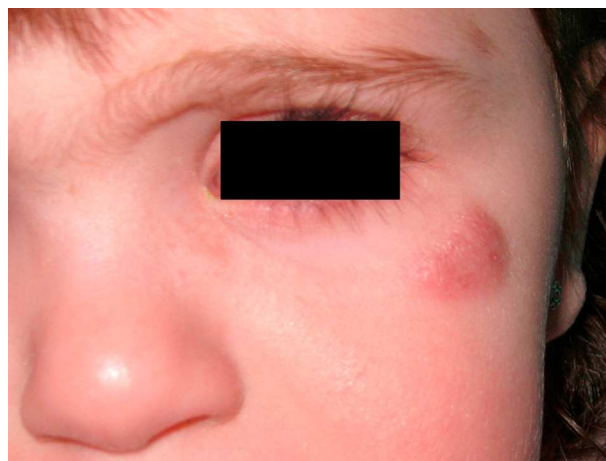

Figure 1 Asymptomatic red to violaceous nodule in the upper region of the left cheek.

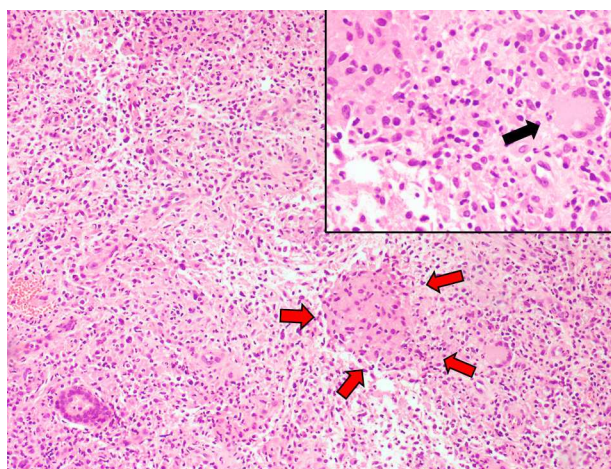


Figure 2 Note the presence of a granuloma composed of histiocytes (red arrows). To the right of this is a multinucleated giant cell (black arrow). Note the higher magnification in top right-hand corner of the image. Hematoxylin-eosin $\times 20$.

Based on the results obtained, the lesion was diagnosed as an idiopathic facial aseptic granuloma. No treatment was prescribed.

Four months after the first visit, the lesion had completely disappeared, leaving a slightly pink macule in its place (Fig. 3.)

[☆] Please cite this article as: Hiraldo-Gamero A, et al. Granuloma aséptico facial idiopático. Actas Dermosifiliogr. 2013;104:635–6.

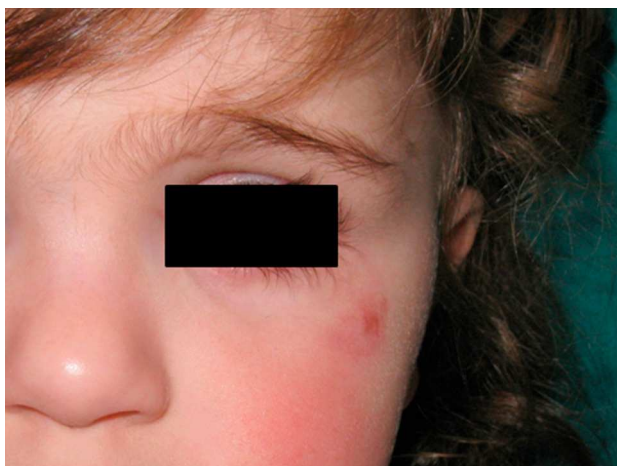

Figure 3 The lesion resolved spontaneously leaving a residual pink macule.

The exact etiology of IFAG is unknown, although Boralevi et al.² have postulated that these lesions may be related to a granulomatous process around an embryological remnant or may belong to the spectrum of granulomatous rosacea in infants. A prospective multicenter study of 30 cases by the same authors reported the mean duration of the lesions to be 11 months and found antibiotic treatment ineffective.

The principal differential diagnosis for this type of lesion includes benign tumors (especially pilomatricomas of the eyelids or eyebrows,^{4,5} dermoid or epidermoid cysts, and chalazia), pyogenic granulomas, Spitz nevi, and xanthogranulomas. It is also important to rule out the possibility of a bacterial or fungal infection, or infection with mycobacteria or parasites (leishmaniasis), all of which are more common in immunocompromised patients.² These lesions can sometimes resemble vascular malformations or hemangiomas, although the clinical course is very different.³ Other differential diagnoses include nodulocystic acne presenting few symptoms.^{2,6}

Our aim in presenting this case is to emphasize the importance of considering IFAG in the differential diagnosis of

acquired facial nodules in children. It is important to inform parents of the benign course of these lesions. Follow-up until the lesion resolves is recommended.¹

The characteristic clinical appearance and location of IFAG and the lack of lymphadenopathy or constitutional symptoms may make a direct clinical diagnosis possible and thereby avoid unnecessary interventions.

References

- Martínez-Díaz GJ, Kim J, Bruckner A. A toddler with facial nodules: A case of idiopathic facial aseptic granuloma. *Dermatol Online J.* 2010;16:9.
- Boralevi F, Léauté-Labrèze C, Lepreux S, Barbarot S, Mazereeuw-Hautier J, Eschard C, et al. Idiopathic facial aseptic granuloma: a multicentre prospective study of 30 cases. *Br J Dermatol.* 2007;156:705–8.
- Roul S, Léauté-Labrèze C, Boralevi F, Bioulac-Sage P, Maleville J, Taieb A. Idiopathic aseptic facial granuloma (pyodermitis froide du visage): a pediatric entity. *Arch Dermatol.* 2001;137:1253–5.
- Yap EY, Hohberger GG, Bartley GB. Pilomatricoma of the eyelids and eyebrows in children and adolescents. *Ophthalm Plast Reconstr Surg.* 1999;15:185–9.
- Yencha MW. Head and neck pilomatricoma in the pediatric age group: a retrospective study and literature review. *Int J Pediatr Otorhinolaryngol.* 2001;57:123–8.
- Cunliffe WJ, Baron SE, Coulson IH. A clinical and therapeutic study of 29 patients with infantile acne. *Br J Dermatol.* 2001;145:463–6.

A. Hiraldo-Gamero,^{a,*} Á. Vera-Casaño,^b A. Sanz-Trélles^c

^a *Unidad de Dermatología, Hospital de Mérida, Badajoz, Spain*

^b *Servicio de Dermatología Médico Quirúrgica, HRU Carlos Haya, Málaga, Spain*

^c *Servicio de Anatomía Patológica, HRU Carlos Haya, Málaga, Spain*

* Corresponding Author.

E-mail address: alihiraldo@hotmail.com

(A. Hiraldo-Gamero).

Periorbital Necrobiosis Lipoidica[☆]

Necrobiosis lipoidica periorbitaria

To the Editor:

Necrobiosis lipoidica (NL) is a granulomatous disease of unknown etiology that typically occurs in diabetic patients. It is characterized by sclerotic plaques that most often appear on the legs.

A 15-year-old girl was admitted to our hospital with facial lesions that had appeared 5 months earlier. She had previously consulted with a surgeon who had suggested surgical excision of the lesions. Physical examination revealed yellowish nodules and plaques with superficial telangiectasias

on the upper and lower eyelids of the left eye (Fig. 1). The patient had been diagnosed with type 1 diabetes mellitus at age 6 years and had a history of marked insulin resistance and chronic poor blood glucose control (hemoglobin A_{1c}, 13%). Skin biopsy revealed an inflammatory infiltrate in the reticular dermis and hypodermis, predominantly composed of histiocytes that had aggregated to form granulomas surrounded by degenerated collagen fibers. Other findings included extracellular lipid deposits and no increase in stromal mucin. Plasma cells and multinucleated giant cells were also observed (Fig. 2). A diagnosis of NL was established on the basis of clinical and histologic findings and the patient's past history. Because the site of the skin lesions made the use of topical or intralesional corticosteroids inadvisable, treatment was started with twice daily applications of 0.1% tacrolimus ointment. After 2 months of treatment with no improvement, oral pentoxifylline (600 mg/12 h) was added but was subsequently discontinued owing to gastrointestinal intolerance. When the lesions had resolved only

[☆] Please cite this article as: G. Pitarch, Giner F. Necrobiosis lipoidica periorbitaria. *Actas Dermosifiliogr.* 2013;104:636–8.