

of Aragón, Spain and by the research groups B85 and B65 recognized by the Government of Aragón, Spain.

## References

- Ruiz-Cendoya M, Madrid H, Pastor FJ, Mayayo E, Mariné M, Guarro J. Development of murine models of disseminated infection by *Neoscytalidium dimidiatum*. *Med Mycol*. 2010;48:681–6.
  - Downs AM, Lear JT, Archer CB. *Scytaalidium hyalinum* onychomycosis successfully treated with 5% amorolfine nail lacquer. *Br J Dermatol*. 1999;140:555.
  - Dunand J, Viguie C, Paugam A. Intermittent posaconazole regimen to treat superficial *Scytaalidium dimidiatum* infection. *Eur J Dermatol*. 2010;20:649–50.
  - Dai T, Fuchs BB, Coleman JJ, Prates RA, Astrakas C, St. Denis TG, et al. Concepts and principles of photodynamic therapy as an alternative antifungal discovery platform. *Front Microbiol*. 2012;3:120.
  - Gilaberte Y, Aspiroz C, Martes MP, Alcalde V, Espinel-Ingroff A, Rezusta A. Treatment of refractory fingernail onychomycosis caused by nondermatophyte molds with methylaminolevulinate photodynamic therapy. *J Am Acad Dermatol*. 2011;65:669–71.
  - Aspiroz C, Gilaberte Y, Paz-Cristóbal P, Rezusta A. Distal onycholysis resolved with photodynamic therapy in an elderly patient on multiple medication. *Enferm Infecc Microbiol Clin*. 2011;29:626–8.
  - Piraccini BM, Rech G, Tosti A. Photodynamic therapy of onychomycosis caused by *Trichophyton rubrum*. *J Am Acad Dermatol*. 2008;59 Suppl.:S75–6.
  - Sotiriou E, Koussidou-Eremonti T, Chaidemenos G, Apalla Z, Ioannides D. Photodynamic therapy for distal and lateral sub-ungual toenail onychomycosis caused by *Trichophyton rubrum*: preliminary results of a single-centre open trial. *Acta Derm Venereol*. 2010;90:216–7.
  - Smijs TGM, Mulder AA, Pavel S, Onderwater JJ, Koerten HK, Bouwstra JA. Morphological changes of the dermatophyte *Trichophyton rubrum* after photodynamic treatment: a scanning electron microscopy study. *Med Mycol*. 2008;46:315–25.
  - Amichai B, Davidovici B, Trau H, Lyakhovitsky A, Grunwald MH, Shemer A. A rationale for systemic treatment in onychomycosis with negative results on fungal examination. *Clin Exp Dermatol*. 2011;36:724–7.
- C. Aspiroz<sup>a,b,\*</sup> B. Fortuño-Cebamanos<sup>a</sup> A. Rezusta<sup>b,c</sup>  
Y. Gilaberte<sup>b,d</sup>
- <sup>a</sup> *Unidad de Microbiología, Hospital Royo Villanova, Zaragoza, Spain*  
<sup>b</sup> *Instituto de Ciencias de la Salud de Aragón, Zaragoza, Spain*  
<sup>c</sup> *Servicio de Microbiología, Hospital Universitario Miguel Servet, Zaragoza, Universidad de Zaragoza, Spain*  
<sup>d</sup> *Unidad de Dermatología, Hospital San Jorge, Huesca, Spain*
- \* Corresponding author.  
E-mail address: [caspiroz@gmail.com](mailto:caspiroz@gmail.com) (C. Aspiroz).

## Urticaria-Like Reaction Secondary to Photodynamic Therapy in 2 Pediatric Patients<sup>☆</sup>

### Reacción urticariforme secundaria a terapia fotodinámica en 2 pacientes pediátricos

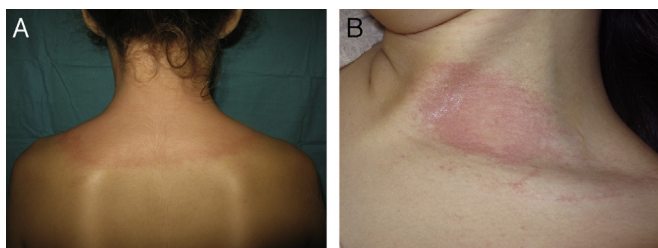
To the Editor:

Photodynamic therapy (PDT) is a light therapy that involves the production of reactive oxygen species and free radicals to induce oxidation in biological tissues. The effect is achieved through the application of a photosensitizing agent, which is then activated by exposure to wavelength-specific light.<sup>1</sup> The most commonly used photosensitizer is methyl aminolevulinate (MAL). PDT is primarily used in the treatment of basal cell carcinoma, actinic keratosis, and Bowen disease, although it can also be used to treat certain non-neoplastic diseases. The most common side effects are pain and local inflammation; wheals are very rare.<sup>2</sup> We present the cases of 2 pediatric patients who developed urticarial reactions to PDT.

The first patient was an 11-year-old girl with nevoid basal cell carcinoma syndrome (Gorlin syndrome) who presented with the characteristic clinical manifestations, including frontal bossing, hypertelorism, small ears, syndactyly, palmar pits, and a large number of small, pedunculated, papular lesions on the neck, axillas, groin, and popliteal fossae. Histologic examination of these lesions revealed basal cell carcinoma. The lesions had previously been treated with cryotherapy, electrocoagulation, and imiquimod. PDT treatment was prescribed and administered on several lesions on the upper back and the neck according to the standard protocol: MAL 160 mg/g cream (Metvix) applied under occlusion for 3 hours followed by illumination using an Aktelite lamp at a dose of 37 J/cm<sup>2</sup>. Three minutes after starting illumination, semicircular wheals appeared in the area being treated, and light exposure was stopped (Fig. 1A). The lesions disappeared after a few hours without treatment and did not recur. Some months later the patient underwent provocation testing with the MAL cream applied under occlusion for 3 hours followed by illumination. Wheals appeared in the illuminated area where the cream had been applied, but no lesions were observed in the area exposed to light without prior application of cream (Fig. 1B). The wheals disappeared spontaneously and there was no recurrence.

The second patient was a 4-year-old girl with no relevant past history or family history who presented with brownish, erythematous, maculopapular lesions in a blaschkoid distribution affecting the dorsum and anterior aspect of the

<sup>☆</sup> Please cite this article as: Miguélez A, et al. Reacción urticariforme secundaria a terapia fotodinámica en 2 pacientes pediátricos. *Actas Dermosifiliogr*. 2013;104:727–9.

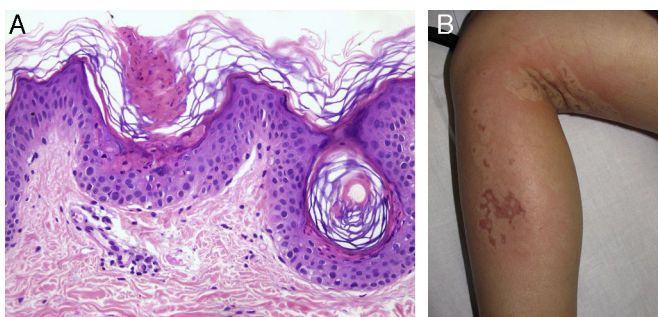


**Figure 1** A, Large semicircular wheals on the upper back where PDT was administered. B, Wheals on the skin illuminated following the application of methyl aminolevulinate cream (Metvix) and no visible lesion on the illuminated area where no cream was applied (positive provocation test result).

left forearm, thigh, and left leg. Porokeratosis was revealed on histology (Fig. 2A). The lesions had not responded to treatment with topical corticosteroids or retinoids. Treatment with PDT was administered using the standard protocol without pretreatment curettage. After 2 minutes of light exposure, large erythematous, edematous lesions appeared in the area being treated and the procedure was stopped (Fig. 2B). The lesions disappeared after a few hours without treatment and did not recur. Provocation testing was not carried out due to the young age of the patient.

In both patients, Giemsa staining of skin biopsies taken prior to PDT showed no significant increase in the number of mast cells.

Urticarial reactions to PDT using 5-aminolevulinic acid and MAL have been described in the literature.<sup>3-5</sup> A 2008 study reported a 0.9% prevalence (12/1353 patients) for severe itching and wheals within the first minute of illumination.<sup>5</sup> The patients most predisposed to reaction were those who had received more than 7 courses of treatment (3.8% prevalence).<sup>5</sup> Those authors postulated that this type of urticaria may be mediated by immunoglobulin E with histamine release from mast cells in the dermis. This pathogenesis is consistent with the recurrent nature of the reactions in subsequent treatments, the satisfactory control of these reactions through the administration before treatment of an antihistamine such as cetirizine, and the immediate appearance of urticaria in areas not previously



**Figure 2** A, Observe the cornoid lamella—a column of stacked parakeratotic cells extending through the stratum corneum characteristic of porokeratosis. Hematoxylin-eosin, original magnification  $\times 100$ . B, Large erythematous, edematous lesions on the left leg on the area where PDT treatment was applied.

treated with PDT.<sup>5</sup> In our patients, urticaria appeared during the first course of treatment. In the first patient, a subsequent provocation skin test confirmed that the reaction was produced by the combination of MAL and illumination, and not by either one separately.

Of particular note was the especially extensive reaction in our patients. We found no reports in the literature of nevoid basal cell carcinoma syndrome involving a similar reaction to PDT, despite the increasing use of PDT in these patients.<sup>6-8</sup> Similarly, we found no reports of urticarial reactions in patients with porokeratosis treated with PDT.<sup>9,10</sup> An additional associated factor could be the young age of these patients. We found no cases in the literature of reaction to PDT in children, but this treatment is rarely used in this age group. It has been suggested that mast cells may play a role in this type of reaction and at the same time participate in the nonspecific immune response that results in the tissue damage caused indirectly by PDT. We therefore postulated the possibility of high mast cell counts in the affected areas, but this hypothesis was ruled out by the results of Giemsa staining.

In summary, these 2 rare cases of urticaria during PDT in children, a previously unreported reaction in this age group, demonstrate the need for dermatologists to be aware of this reaction so that they will stop illumination promptly and treat the resulting lesions appropriately.

## References

- Gilaberte Y. *Terapia fotodinámica*. Madrid: Aula Médica; 2008.
- Brogeras M, Romero Mate A, Nieto Perea O, Borbujo Martínez JM. Complicaciones en la terapia fotodinámica. *Piel*. 2007;22:309-13.
- Yokoyama S, Nakano H, Nishizawa A, Kaneko T, Harada K, Hanada K. A case of photocontact urticaria induced by photodynamic therapy with topical 5-aminolaevulinic acid. *J Dermatol*. 2005;32:843-7.
- Kerr AC, Ferguson J, Ibbotson SH. Acute phototoxicity with urticarial features during topical 5-aminolaevulinic acid photodynamic therapy. *Clin Exp Dermatol*. 2007;32:201-2.
- Kaae J, Philipson PA, Haedersdal M, Wulf HC. Immediate whealing urticaria in red light exposed areas during photodynamic therapy. *Acta Derm Venereol*. 2008;88:480-3.
- Leger M, Quintana A, Tzu J, Yee H, Kamino H, Sanchez M. Nevoid basal cell carcinoma syndrome. *Dermatol Online J*. 2011;17:23.
- Segura S, Puig S, Carrera C, Lecha M, Borges V, Malveyh J. Non-invasive management of non-melanoma skin cancer in patients with cancer predisposition genodermatosis: a role for confocal microscopy and photodynamic therapy. *J Eur Acad Dermatol Venereol*. 2011;25:819-27.
- Pauwels C, Mazereeuw-Hautier J, Basset-Seguín N, Livideanu C, Viraben R, Paul C, et al. Topical methyl aminolevulinate photodynamic therapy for management of basal cell carcinomas in patients with basal cell nevus syndrome improves patient's satisfaction and reduces the need for surgical procedures. *J Eur Acad Dermatol Venereol*. 2011;25:861-4.
- García-Navarro X, Garcés JR, Baselga E, Alomar A. Linear porokeratosis: excellent response to photodynamic therapy. *Arch Dermatol*. 2009;145:526-7.
- Sim JH, Kang Y, Kim YC. Verrucous epidermal nevus successfully treated with photodynamic therapy. *Eur J Dermatol*. 2010;20:814-5.

A. Miguélez,<sup>a,\*</sup> A. Martín-Santiago,<sup>b</sup> A. Bauzá,<sup>b</sup>  
Y. Gilaberte<sup>c</sup>

<sup>a</sup> Servicio de Dermatología, Hospital Universitario de la Princesa, Madrid, Spain

<sup>b</sup> Servicio de Dermatología, Hospital Universitario Son Espases, Palma de Mallorca, Spain

<sup>c</sup> Servicio de Dermatología, Hospital San Jorge, Huesca, Spain

\*Corresponding author.

E-mail address: [anamig@telefonica.net](mailto:anamig@telefonica.net) (A. Miguélez).

## Skin Dimpling as a Complication of Amniocentesis: Histopathologic Findings<sup>☆</sup>

### Hoyuelos cutáneos como consecuencia de amniocentesis: hallazgos histopatológicos

To the Editor:

During pregnancy, delivery, and postpartum, a series of diagnostic and therapeutic procedures are currently performed which have led to reduced neonatal morbidity and mortality but which have also increased the risk of certain iatrogenic cutaneous and traumatic injuries.<sup>1-3</sup>

The incidence of fetal puncture due to amniocentesis has declined since the introduction of ultrasound guidance<sup>4,5</sup>; however, increasing maternal age has led to more frequent use of amniocentesis,<sup>6</sup> thus making awareness of fetal puncture a matter of importance for dermatologists, obstetricians, and pediatricians.<sup>7</sup>

This letter describes the case of a 3-month-old infant who presented several skin dimples as a result of amniocentesis-related puncture. A search of the literature found no other cases of this entity in which a histopathologic study had been performed.<sup>5</sup>

A male infant aged 3 months with no relevant medical history presented for assessment of a number of skin lesions on the abdomen and left thigh which were first noticed during the first month of life. The infant had no congenital abnormalities and had been born following a full-term pregnancy by unassisted vaginal delivery in cephalic presentation. One of the techniques performed on the mother during gestation and delivery was an amniocentesis in the 18th week which required several punctures.

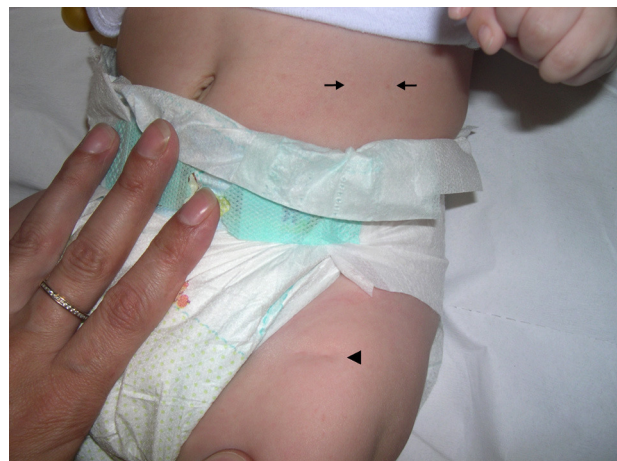
A physical examination revealed 2 dimples measuring 2 mm in diameter on the left side of the abdomen and a linear depression 1.2 cm long on the anterior aspect of the proximal third of the left thigh (Figs. 1 and 2). The patient did not present any other skin lesions, involvement of the oral or genital mucosae, or abnormalities of the hair or nails. The infant's weight and height were normal.

A diagnosis of skin dimpling as a complication of amniocentesis was established. The parents were informed of the benign nature of the skin condition, although they decided to request a biopsy of the thigh lesion so as to rule out other pathologies. The histopathologic study revealed a dermis

with collagen bundles having an abnormal morphology and distribution (fine bundles arranged in multiple directions). A reduction and fragmentation of elastic fibers was observed using orcein staining. No abnormalities were seen in the epidermis or the subcutaneous tissue (Fig. 3). The skin lesions remained unchanged over the subsequent 8 months.

Amniocentesis is the most frequently used technique for prenatal diagnosis of genetic alterations. It is usually performed during the second trimester of pregnancy. One of the possible complications of the procedure is fetal puncture, the most frequent manifestation of which is skin dimpling.<sup>4</sup> Amniocentesis may also cause injury to underlying structures, such as peripheral nerves, tendons, or the eyeball, and result in ileocutaneous or arteriovenous fistulas.<sup>3</sup>

Skin dimpling as a complication of amniocentesis presents as punctate depressions or linear scars measuring 1 to 5 mm in diameter. These manifestations may be isolated or multiple; when multiple, they are sometimes grouped and sometimes follow a linear path due to fetal puncture along a single plane. Clearer observation may be achieved by pinching the surrounding skin.<sup>8</sup> Skin dimples caused by amniocentesis are present at birth, although some are not clearly visible until weeks or months later; they do not resolve spontaneously.<sup>6</sup> The most common site is the thigh, followed by the abdomen, buttocks, and upper limbs. These dimples tend to be found by chance during examination and are not usually the reason for consultation.<sup>7</sup> It has been speculated that dimpling results from localized lipoatrophy or a loss of subcutaneous tissue. The histopathologic findings in this case, namely, fine collagen bundles and a reduction in elastic fibers, are consistent with localized depressed



**Figure 1** Cutaneous scars on the abdomen (←) and right thigh (◄).

<sup>☆</sup> Please cite this article as: Monteagudo B, et al. Hoyuelos cutáneos como consecuencia de amniocentesis: hallazgos histopatológicos. *Actas Dermosifiliogr.* 2013;104:729-31.