




# ACTAS Dermo-Sifiliográficas

Full English text available at  
[www.actasdermo.org](http://www.actasdermo.org)



## VIDEOS OF SURGICAL PROCEDURES IN DERMATOLOGY

### Combination of a Glabellar Flap and a Transposition Flap for the Reconstruction of 2 Noncontiguous Nasal Defects<sup>☆</sup>



### Colgajo glabellar combinado con colgajo de transposición para la reconstrucción de 2 defectos nasales discontinuos

L.M. Valladares-Narganes,\* A. Pérez-Bustillo, G. Pérez-Paredes, M.Á. Rodríguez-Prieto

*Servicio de Dermatología, Complejo Asistencial Universitario de León, León, Spain*

#### Description

The reconstruction of multiple surgical defects of the nasal pyramid is not a common situation and can be a challenge for the dermatologic surgeon, as the reconstructive techniques are limited. The problem is further compounded when the surgical defects are anatomically independent and cannot be united into a single defect.

In such reconstructions, it is essential to take into account the color, texture, and morphology of the different anatomical subunits of the nose, as well as the tension lines in each region, making the situation yet more complex.<sup>1</sup>

The skin of the glabellar region is frequently used to close defects of the external nose because of its excellent blood supply, its ample reserve of tissue, and its satisfactory

mobility. Over the years, the classic glabellar flap, first described by Gillies and subsequently modified by Reiger, has become a flap of choice for defects on the lateral surfaces of the root of the nose and in the area of the medial canthus.<sup>2</sup> Variants of this flap can be used to repair defects of the dorsum, tip, or lateral walls of the nose and of the ala nasi. A large range of movement of the skin of the glabella and of the dorsum of the nose is possible without distorting the anatomy of the lateral wall of the nose on the same side, although a Burow triangle must be created on the opposite side.

Transposition flaps, which have numerous morphological variants, are moved into the surgical defect by rotation and/or advancement.<sup>3</sup> On the external nose, these flaps have the advantage of an excellent blood supply derived from nasal branches of the angular artery, a branch of the facial artery, which supplies the lateral walls of the nose. There is therefore a low risk of necrosis.<sup>4</sup>

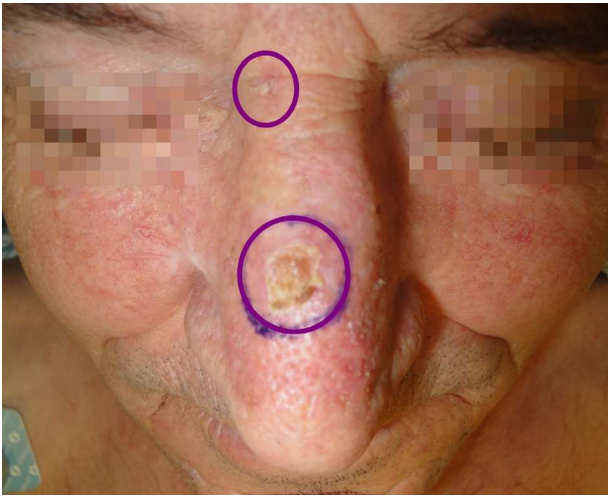The great advantage of these flaps is their versatility, as their design can be varied in each patient according to surgical considerations, such as the site, size, and depth of the defect and cosmetic factors.<sup>5</sup>

Both flaps are therefore highly versatile, easy to design and perform, and provide excellent functional and cosmetic results; we have capitalized on these advantages to combine the 2 flaps in the following case.

<sup>☆</sup> Please cite this article as: Valladares-Narganes L, Pérez-Bustillo A, Pérez-Paredes G, Rodríguez-Prieto M. Colgajo glabellar combinado con colgajo de transposición para la reconstrucción de 2 defectos nasales discontinuos. Actas Dermosifiliogr. 2014;105:193–195.

\* Corresponding author.

E-mail address: [lmvalladares84@hotmail.com](mailto:lmvalladares84@hotmail.com)  
(L.M. Valladares-Narganes).



**Figure 1** Basal cell carcinomas on the dorsum and root of the nose. The circles indicate the size of the surgical defects after excision with adequate margins.

### Technique

The patient was a 63-year-old man with a history of hypertension and dyslipidemia on medical treatment. He was seen in our outpatient clinic because of 2 progressively enlarging tumors that had arisen some months earlier on the dorsum of the nose and close to the root of the nose (Fig. 1); the tumors were clinically compatible with basal cell carcinomas and did not infiltrate deeply. The lesion on the root of the nose was approximately 0.5 cm in diameter and the one on the dorsum measured 1.2 cm. Both lesions were excised with adequate margins, with dissection to the depth of the supraperichondrial plane.

To reconstruct the 2 defects in a single operation, we designed a superior glabellar flap combined with an inferior transposition flap with a vascular pedicle from the lateral wall of the nose. The defects were triangulated on the side opposite to the surgical incisions.

In order to avoid tension in the suture, it is important to free the deep plane of the flap completely to the lateral border of the pedicle, using the same plane as the surgical defect. The secondary glabellar defect is easily closed using a V-Y technique.

It should be emphasized that this combined flap, if well designed, is very unlikely to develop necrosis, as it has a very high base to height ratio, providing a pedicle that is more than sufficient.

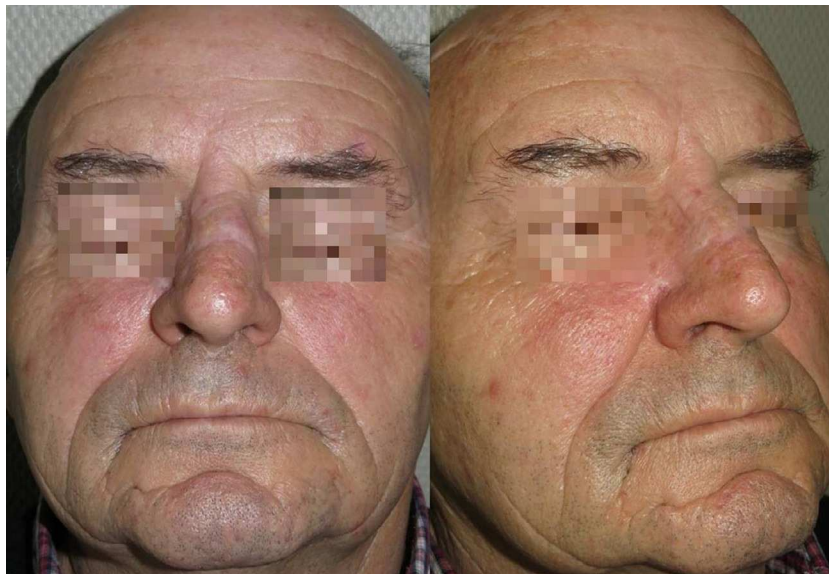The postoperative result was excellent from a functional point of view, the scar was almost imperceptible, and, at the 12-month follow-up, the patient presented no signs of tumor recurrence (Fig. 2).

### Indications

- This combined flap is indicated for the reconstruction of multiple, medium-sized, noncontiguous surgical defects on the dorsum and/or root of the nose, in which the separation of the defects permits the 2 flaps to be mobilized without risk of necrosis.

### Contraindications

- Small surgical defects that can be closed by primary suture or with smaller individual flaps.
- Very large defects that require more complex combined flaps or closure in 2 operations.
- Defects that, due to their proximity, can be made into a single surgical defect, which can be repaired using a more suitable flap.



**Figure 2** Postoperative result 12 months after the operation.

## Benefits

- This method provides a simple and rapid technique for the reconstruction of multiple defects on the dorsum of the nose in a single operation, with a low risk of necrosis.
- The anatomical features of the different subunits of the external nose are respected.

## Risks

- Postoperative infection.
- Postsurgical hematomas in the periorbital and intercilary regions.
- Tenting.
- Unsightly scar.
- Introduction of hair from the intercilary region onto the root of the nose.
- Risk of distal necrosis—this is low but could be increased by poor flap design.
- Approximation of the eyebrows.

## Alternatives

- Closure of the 2 surgical defects using individual flaps.
- Full-thickness skin grafts or Burow graft.
- Advancement flaps from the perialar region, triangular advancement flaps, A-T advancement flaps, or transposition flaps.

## Conclusions

The glabellar flap and its variants have been described extensively in the literature for the repair of defects of the nose or canthus. The flap is very simple to design, has a good blood supply, and provides excellent functional and cosmetic results.

In the literature we have been unable to find any description of the use of the glabellar flap in combination with other types of transposition flap for the reconstruction of multiple, independent surgical defects of the nasal pyramid.

We have presented a variant of the glabellar flap combined with a transposition flap with a lateral pedicle. This modification enabled us to close 2 surgical defects in a single operation using a simple technique that is within the scope of all dermatologists with experience in reconstructive surgery.

## Conflicts of Interest

The authors declare that they have no conflicts of interest.

## Appendix A. Supplementary data

Supplementary data associated with this article can be found, in the online version, at <http://dx.doi.org/10.1016/j.adengl.2013.10.003>.

## References

1. Koch CA, Archibald DJ, Friedman O. Glabellar flaps in nasal reconstruction. *Facial Plast Surg Clin North Am.* 2011;19:113–22.
2. Fliss DM, Freeman JL. The nasal glabellar flap. *J Otolaryngol.* 1994;23:6–7.
3. Román J, Yébenes M. Resolución de los defectos quirúrgicos de la pirámide nasal. *Actas Dermosifiliogr.* 2007;98:302–11.
4. Rodríguez-Prieto MA. Cirugía topográfica del dorso nasal. In: Rodríguez-Prieto MA, editor. *Cirugía dermatológica de la pirámide nasal.* 2<sup>nd</sup> ed. Madrid: Aula Médica; 2012. p. 122–4.
5. Turgut G, Ozcan A, Yesiloglu N, Bas L. A new glabellar flap modification for the reconstruction of medial canthal and nasal dorsal defects: "Flap in flap" technique. *J Craniofac Surg.* 2009;20:198–200.