




ACTAS Derma-Sifiliográficas

Full English text available at
www.actasdermo.org



REVIEW

Update on the Treatment of Chronic Urticaria[☆]

L. Curto-Barredo,^{a,*} J.F. Silvestre,^b A.M. Giménez-Arnau^a

^a Servicio de Dermatología, Hospital del Mar-Parc de Salut Mar, Universitat Autònoma, Barcelona, Spain

^b Servicio de Dermatología, Hospital General universitario, Alicante, Spain

Received 19 September 2012; accepted 25 December 2012

Available online 14 May 2014

KEYWORDS

Chronic spontaneous urticaria;
Autoimmune chronic urticaria;
Treatment;
Antihistamines

PALABRAS CLAVE

Urticaria crónica espontánea;
Urticaria crónica autoinmune;
Tratamiento;
Antihistamínicos

Abstract Chronic spontaneous urticaria, also known as chronic idiopathic urticaria or simply chronic urticaria, is a common disorder that has a prevalence in the general population that ranges between 0.5% and 1%. This condition negatively affects the patient's quality of life and has considerable impact on direct and indirect health-related costs. Chronic urticaria is difficult to manage. Nonsedating H₁ antihistamines are the first line of therapy, but fewer than 50% of patients experience relief at recommended dosages. Although guidelines call for increasing the dosage when response is inadequate, some patients still do not achieve adequate control of symptoms. New treatment alternatives, with proven efficacy under the standards of evidence-based medical practice, must therefore be developed.

© 2012 Elsevier España, S.L. and AEDV. All rights reserved.

Actualización en el tratamiento de la urticaria crónica

Resumen La urticaria crónica espontánea, también conocida como urticaria crónica idiopática o urticaria crónica, es un proceso frecuente con una prevalencia estimada de entre el 0,5 y el 1% de la población general. Es un proceso que interfiere en la calidad de vida del paciente y ocasiona un notable impacto en los costes sanitarios directos e indirectos. La urticaria crónica es una entidad que plantea dificultades de manejo terapéutico. Se considera que los fármacos antihistamínicos H₁ no sedantes son el tratamiento de primera elección. Su prescripción a las dosis recomendadas solo consigue una reducción de los síntomas en menos del 50% de los pacientes. Aunque las guías terapéuticas recomiendan incrementar las dosis en casos de respuestas no adecuadas, persiste un grupo de pacientes en los que no se consigue controlar la sintomatología. Existe, pues, la necesidad del desarrollo de nuevas alternativas terapéuticas cuya eficacia se establezca bajo criterios de medicina basada en la evidencia.

© 2012 Elsevier España, S.L. y AEDV. Todos los derechos reservados.

[☆] Please cite this article as: Curto-Barredo L, Silvestre JF, Giménez-Arnau AM. Actualización en el tratamiento de la urticaria crónica. Actas Dermosifiliogr. 2014;105:469–482.

* Corresponding author.

E-mail address: laia.curto@gmail.com (L. Curto-Barredo).

Etiological and Pathophysiological Aspects to Be Taken Into Account in the Treatment of Chronic Urticaria

A large number of factors can trigger the onset of urticaria and/or angioedema, including physical stimuli (cold, heat, pressure, vibration, UV light), drugs (nonsteroidal anti-inflammatory drugs [NSAIDs], angiotensin-converting enzyme inhibitors, opioids), infections (*Helicobacter pylori*, intestinal parasites), foods, hypocomplementemia, and autoimmune disorders. To date, in contrast to urticarial vasculitis, no relationship has been detected between urticaria and malignancy. Due to the lack of consensus on the definition of the causative criteria, notable differences exist between authors regarding identification of the etiological factors implicated in chronic spontaneous urticaria. In some series, an etiological factor is identified in up to 40% to 50% of cases. The traditional term *chronic idiopathic urticaria* should be avoided or reserved only for those cases in which no etiological factor can be identified.¹⁻⁵

The main effector cell in the production of the wheal is the cutaneous mast cell, which, after its activation, undergoes degranulation with the release of histamine and other vasoactive and proinflammatory mediators. Potential mast-cell activators include opioids, immunoglobulin (Ig) E (mast cells have a high-affinity IgE receptor [Fc ϵ RI] on their cell membranes), complement factors (C5A), and substance P. Once activated, mast cells release granules that mainly contain histamine, though other inflammatory mediators are also present, such as platelet activating factor (PAF), tumor necrosis factor (TNF), interleukin (IL) 3, IL-4, IL-5, IL-6, IL-8, IL-13, granulocyte-macrophage colony stimulating factor (GM-CSF), prostaglandin (PG) D-2, and leukotrienes (LT) (LTC₄, LTD₄, LTEA). Histamine, TNF, and IL-8 also stimulate endothelial adhesion molecules, which favor eosinophil, monocyte, and neutrophil migration from the bloodstream into the skin.^{3,4} It has recently been suggested that thrombin could play a role in the pathogenesis of chronic urticaria (CU), as this molecule has been found to increase vascular permeability, to act on the complement pathway, and to promote mast-cell degranulation.⁶

The chronic form of urticaria (wheals and/or angioedema lasting more than 6 weeks) is a skin disease with a prevalence in the general population between 0.1% and 3%.⁷ Many patients with CU report a considerable reduction in quality of life as a result of the pruritus, sleep disturbances, fatigue, social isolation, and emotional disorders; its impact on quality of life is comparable to that suffered by patients with severe coronary artery disease.^{8,9} Chronic spontaneous urticaria accounts for around 70% of all cases of CU and can persist for several years.

It has been shown that approximately a third of patients with chronic spontaneous urticaria present a positive response to the intradermal injection of their own serum (serum autoreactivity) in the autologous serum skin test (ASST). However, only a minority of these patients have detectable antibodies to the Fc ϵ RI or to autologous IgE (autoimmunity). Chronic autoimmune urticaria accounts for 30% to 50% of all cases of CU.

In chronic autoimmune urticaria the cutaneous mast cells become permanently activated due to the presence

of functional IgG antibodies to the alpha subunit of the Fc ϵ RI (30%-50%) or to the IgE of the mast cell directly (5%-10%). Basophils also express Fc ϵ RI, and thus a fall in basophil levels is usually detected in patients with chronic autoimmune urticaria. The capacity of the patient's serum to induce the degranulation of healthy basophils can be demonstrated by the in vitro detection of functional antibodies. It has recently been reported that IgE antithyroperoxidase antibodies can also induce mast-cell degranulation. Mast-cell degranulation is also thought to be induced by the classic complement pathway, particularly factor C5A, which, apart from favoring mast-cell and basophil degranulation, is involved in chemotaxis to recruit neutrophils, eosinophils, and monocytes. Antithyroid antibodies are detected in 25% of cases of chronic autoimmune urticaria (in contrast to 6% of the general population) and this form of urticaria has frequently been associated with diseases such as Hashimoto thyroiditis and, less commonly, with Graves disease; its association with other autoimmune diseases, such as diabetes mellitus and vitiligo, has also been reported.

General Bases for the Treatment of Chronic Urticaria

General Measures

In the treatment of urticaria it is important to avoid possible nonspecific triggers or aggravating factors such as heat, stress, alcohol, and certain drugs, including acetylsalicylic acid, NSAIDs, angiotensin-converting enzyme (ACE) inhibitors (particularly if the urticaria presents with angioedema, with or without wheals) and codeine. Cooling, antipruritic lotions such as calamine or 1% menthol in aqueous cream can be applied.^{2,3,10,11}

Pharmacological Treatment

The treatments of CU can be classified according to their different functional effects. The majority of drugs modulate the capacity of mast cells to undergo degranulation and release their mediators. This group includes certain antihistamines, the corticosteroids, ciclosporin A (CsA), tacrolimus, methotrexate, and phototherapy. Drugs routinely used in the treatment of CU act by blocking the receptors and modulating the mediators that, situated on the nerve fibers and blood vessels, induce pruritus, vasodilatation, and chemotaxis. These are the most widely used drugs in the management of CU and include the antihistamines (H₁ and H₂ blocking agents), antileukotrienes, and dapsone. Some drugs act prior to activation of the effector cell or mast cell. This group includes omalizumab (a monoclonal antibody with the ability to bind IgE), plasmapheresis, and intravenous immunoglobulins (Table 1).

Antihistamines

Histamine plays a key role in the formation of the typical lesion of urticaria. It has been observed that patients with CU have higher local levels of histamine than healthy individuals both in affected skin and in healthy skin.¹² There

Table 1 Mechanism of Action of the Treatments for Chronic Urticaria.

IgE Modulators	Mast-Cell Modulators	Receptors on Nerves and Blood Vessels, and Chemotaxis
Omalizumab	Antihistamines	Antihistamines
Intravenous immunoglobulin	Corticosteroids	Antileukotrienes
Plasmapheresis	Ciclosporin	Dapsone
Mycophenolate mofetil	Tacrolimus	Colchicine
	Phototherapy	Mycophenolate mofetil
	Tranexamic acid + LMWH	Tranexamic acid + LMWH
		Interferon
		Anti-TNF

Abbreviations: LMWH, low-molecular-weight heparin; TNF, tumor necrosis factor.

are 4 types of histamine receptor in the skin: the H₁ receptors, found mainly in the endothelium, smooth muscle, and central nervous system; the H₂ receptors, located also on the parietal cells of the digestive tract; the H₃ receptors, present in the central nervous system and on the bronchial smooth muscle; and the H₄ receptors, found on dendritic cells in the skin, and in the thymus, spleen, small bowel, and colon, and which are currently a subject of therapeutic research. The antihistamines are effective in the treatment of urticaria because of their antagonism of the H₁ receptors.

Antihistamines have been used to treat CU for more than 60 years and continue to be the treatment of first choice. The majority of symptoms of urticaria are the result of the actions of histamine on the H₁ receptors located on the endothelial cells (wheal) and on the sensory nerve endings (pruritus). The antihistamines act on the endothelium of the postcapillary venules, reducing extravasation and wheal formation, and on the afferent C nerve fibers of the skin, reducing pruritus. In addition, the effect of the antihistamines on cutaneous axonal reflexes reduces erythema. Many of the antihistamines have anti-inflammatory activity as they reduce the levels of preformed or newly formed cytokine mediators and cell adhesion molecules, leading to a reduction in the recruitment of inflammatory cells (lymphocytes, monocytes, neutrophils, eosinophils). These actions occur mainly through 2 mechanisms: stabilization of the basophil and mast-cell membranes by the H₁-antihistamines and the inhibition of cytoplasmic transcription factors such as nuclear factor kappa-B.¹³

The antihistamines can be classified into anti-H₁, anti-H₂, anti-H₃, and anti-H₄ according to the receptors on which they act. The antihistamines currently used for the treatment of CU are the first-generation H₁-antihistamines, the second-generation H₁-antihistamines, and the H₂ antihistamines.

The first-generation H₁-antihistamines have been used for many years to treat CU and other allergic disorders. They have anticholinergic effects and cross the blood-brain barrier, leading to sedative effects. These side effects can limit adherence to treatment, and such drugs are therefore usually reserved for cases in which the pruritic symptoms occur mainly at night (interference with sleep initiation) and in patients who do not respond to second-generation antihistamines. The first-generation H₁-antihistamines include hydroxyzine, diphenhydramine, ciproheptadine, and dexchlorpheniramine (Table 2).

The efficacy of the second-generation H₁-antihistamines has also been demonstrated in the symptomatic treatment of urticaria. Some, such as rupatadine, have even been found to have greater affinity for binding to the histamine receptors than the first-generation H₁-antihistamines.¹⁴ They do not cross the blood-brain barrier and therefore do not give rise to sedative effects and they usually have no anticholinergic side effects. They are the only treatment with level 1 evidence and grade A recommendation. The second-generation H₁-antihistamines are currently the drugs of choice for the treatment of CU. However, symptoms persist in a large proportion of patients despite treatment with antihistamines at the recommended doses. In a recent study performed by Maurer et al.,⁵ up to 50% of patients with CU did not respond to the recommended doses of antihistamines, probably because those doses are based on the treatment of other allergic diseases, such as seasonal rhinitis. In nonresponders, it has been suggested that the dose of antihistamine be increased up to 4 times the recommended dose. Other mediators released by the mast cells, such as cytokines, eicosanoids, proteases, and PAF, have been implicated in the formation of wheals in patients with CU.¹⁵ It has recently been observed that PAF can induce mast-cell degranulation in vitro.¹⁶ The authors of this paper have been able to study the specific characteristics of the wheal induced by PAF in healthy volunteers; in this context, the wheal developed independently of mast-cell degranulation.¹⁷

Two potent second-generation H₁-antihistamines, terfenadine and astemizole, were withdrawn from the market due to the appearance of cardiac side effects (ventricular arrhythmias-torsade de pointes). Since that time, both the Food and Drug Administration and the European Medicines Agency require cardiotoxicity studies to be performed during the development of any new antihistamine.

Numerous clinical trials have been performed to compare the different second-generation antihistamines against each other and against placebo. No statistically significant differences were detected with regard to symptom control, safety profile, or quality of life.^{13,18-22} A description of the second-generation H₁-antihistamines is given below.

Acrivastine

Acrivastine has a short half-life and must therefore be administered 3 times a day (the other antihistamines are usually recommended once a day). It has a rapid onset of

Table 2 Table Comparing the First-Generation H₁ Antihistamines^a

Family	Active Substance	Mechanism of Action	Dose	Side Effects	Trade Name ^b
Alkylamide (propylamine)	Dexchlorpheniramine maleate Chlorpheniramine maleate Brompheniramine maleate	H ₁ -receptor antagonist	4-8 mg/6 h	Somnolence	Polaramine
Aminoalkyl ether (ethanolamine)	Diphenhydramine hydrochloride	H ₁ -receptor antagonist Anticholinergic Cough suppressant	25-50 mg/4 h	Somnolence Gastrointestinal disturbances Dryness of mucosas Blurred vision Hypotension Difficulty urinating	Benadryl
Ethylenediamine	Clemastine fumarate Tripelenamine hydrochloride	Antihistamine	25-50 mg/4 h	Somnolence Gastrointestinal disturbances	Pyribenzamine
Phenothiazine	Tripelenamine citrate Promethazine hydrochloride	H ₁ -receptor antagonist	25 mg/8 h	Somnolence Agranulocytosis Liver toxicity Photosensitivity	Fenergan
Piperidine	Methdilazine Methdilazine hydrochloride Ciproheptadine hydrochloride	H ₁ -receptor antagonist Antiserotonergic Anticholinergic	4 mg/8 h	Somnolence CNS alterations Auditory disturbances Cardiac disturbances Agranulocytosis Dryness of mucosas Gastrointestinal disturbances Difficulty urinating Photosensitivity	Periactin
Piperazine	Azatadine maleate Hydroxyzine hydrochloride	H ₁ -receptor antagonist Antiadrenergic Bronchodilator Antiemetic	25 mg/6-8 h	Somnolence Headache Fatigue Dryness of the mouth Sedation	Atarax

^a Names in bold correspond to the active substance of the drug whose trade name appears in the final column.

^b Trade names of drugs available in Spain

action. Acrivastine is excreted intact in the urine and its use must therefore be avoided in patients with moderate kidney failure.²³

Cetirizine

Cetirizine is the active metabolite of hydroxyzine and it can therefore present sedative effects, particularly at high doses. Cetirizine reaches its maximum plasma concentration very quickly, which can be an important clinical advantage due to its rapid bioavailability. It has antiallergic effects on

inflammatory mediators released by mast cells, particularly at high doses. Cetirizine must be avoided in cases of severe kidney failure.²⁴

Levocetirizine

Levocetirizine is the active enantiomer of cetirizine. It is more potent.¹³ It has a higher potency than other antihistamines for the inhibition of wheal and of erythema after the intradermal injection of histamine.²⁵

Loratadine

Loratadine undergoes first-pass metabolism in the liver, where it is transformed into its active molecule, desloratadine. It has antiallergic properties.²⁶

Desloratadine

Desloratadine is the active metabolite of loratadine, and it is therefore more potent. It has a longer elimination half-life than loratadine (27 hours), and its administration must therefore be stopped 6 days before performing skin prick tests. It binds selectively and with high affinity to the H₁ receptors. Desloratadine also has anti-inflammatory and antiallergic activity as it acts on cytokines and cell adhesion molecules. It inhibits other mediators implicated in the appearance of wheals, including cytokines IL-4, IL-13, IL-6, TNF, and GM-CSF, chemokines such as IL-8 and RANTES (regulated on activation, normal T-cell expressed and secreted), and adhesion molecules such as P-selectin and intercellular adhesion molecule (ICAM) 1. It reduces eosinophil chemotaxis and activation *in vitro*.^{27,28} Both desloratadine and loratadine must be used with caution in patients with severe kidney failure.

Mizolastine

Mizolastine is contraindicated in clinically significant heart disease as it can cause prolongation of the QT interval. It must not be administered concomitantly with drugs that inhibit liver metabolism via the cytochrome P450 pathway (including macrolide antibiotics and imidazole antifungal drugs) or with potentially arrhythmogenic drugs (including tricyclic antidepressants such as doxepin). Its use is contraindicated in cases of liver failure.

Ebastine

Ebastine is a second-generation H₁-antihistamine with a structure based on oxopiperidine. It undergoes first-pass metabolism in the liver; its active form is carebastine. It is mainly excreted in the urine. Ebastine produces a dose-dependent inhibition of histamine release by cutaneous mast cells. It has activity on H₁ receptors and also inhibits the release of inflammatory mediators by mast cells.^{22,29} The usual dose of 10 mg must be adjusted in patients with kidney or liver failure.

Rupatadine

Rupatadine is a new second-generation antihistamine with a long half-life. It is a dual antagonist of the peripheral H₁ receptors and of PAF. Rupatadine competitively inhibits PAF-induced platelet aggregation *in vitro*, although to a lesser extent than its specific antagonist. Rupatadine also has anti-inflammatory properties: it inhibits eosinophil chemotaxis *in vivo* and *in vitro*, it suppresses the synthesis of inflammatory cytokines by activated T lymphocytes *in vitro*, and it interferes with cutaneous mast-cell degranulation and the release of histamine and other cytokines.^{14,15,22,30,31} It

is indicated for the treatment of CU and allergic rhinitis. The usual dose is 10 mg. The proportion of patients with CU who respond to rupatadine rises significantly if the dose is doubled to 20 mg. It is a safe and well-tolerated drug.

Fexofenadine

Fexofenadine is a potent antihistamine that is selective for the peripheral H₁ receptors. It is an effective drug for the treatment of both CU and allergic rhinitis³² (Table 3).

There is controversy concerning the role of the H₂-antihistamines in the treatment of CU. The cutaneous blood vessels have both H₁ and H₂ receptors and the activation of either type will induce the formation of wheal and erythema, although activation of the H₂ receptors has a limited pruritic effect. The efficacy of combinations of H₁-antihistamines with H₂-antihistamines has been evaluated in a number of studies and a possible synergic effect has been reported. However, this association does not appear to be justified for the treatment of CU as efficacy has not been shown to be significantly better. The H₂-antihistamines include cimetidine, ranitidine, nizatidine, and famotidine.^{13,18}

Special Situations^{2-4,10,11,13,18,23}

Pregnancy and Breastfeeding

The use of any drug, including the antihistamines, should be avoided if possible during pregnancy, especially during the first trimester. The antihistamines are in pregnancy categories B and C. The second-generation antihistamines sertraline and loratadine are in category B (no evidence of fetal damage during pregnancy). Because of the greater cumulative experience, the prescription of first-generation H₁-antihistamines such as chlorpheniramine is usually recommended. If an antihistamine has to be used during breastfeeding, once again cetirizine and loratadine are recommended, at the lowest possible dose.

Childhood

All the antihistamines can be used in children over 12 years of age. Cetirizine, loratadine, and desloratadine are authorized for the treatment of CU in children over 2 years of age.

Kidney and Liver Failure

The antihistamines that are excreted mainly in the urine are cetirizine (60%) and levocetirizine (85%). The urinary excretion of the other second-generation antihistamines is only of the order of 10% to 20%. The metabolism of the majority of these drugs usually involves first-pass metabolism in the liver via the cytochrome P-450 or CYP pathway, with the exception of cetirizine, levocetirizine, fexofenadine, and desloratadine. In any case, a dose reduction of all second-generation H₁-antihistamines is recommended in patients with severe kidney or liver disease.

Table 3 Table Comparing the Second-Generation H₁ Antihistamines.

Family	Active Substance	Mechanism of Action	Dose	Side Effects	Trade Name ^a
Piperidine	Mizolastine	Neutrophil recruitment 5-lipoxygenase VEGF, TNF	10 mg/24 h	Prolongation of the QT interval Gastrointestinal disturbances Dryness of the mouth, somnolence, headache Increased appetite	Mizolen Zolistan
	Terfenadine	Eosinophil chemotaxis Eosinophil adherence Superoxide synthesis IL-6, IL-8, TNF GM-CSF	60-120 mg/24 h	Cardiotoxicity Headache, vertigo Increased sweating Digestive disturbances Sedation, dryness of the mouth	Triludan
	Fexofenadine		180 mg/24 h	Headache, dizziness, somnolence, fatigue, dryness of the mouth, nausea	Telfast
	Loratadine	Eosinophil chemotaxis IL-8, RANTES, ICAM-1	10 mg/24 h	Somnolence/insomnia, headache, increased appetite	Clarytine
	Desloratadine	Eosinophil chemotaxis Superoxide production TNF, IL-1, IL-6, IL-8, IL-13 P-selectin, ICAM-1 Eosinophil apoptosis NK-kB cell activation	5 mg/24 h	Tiredness, dryness of the mouth Headache	Aerius Azomyr
	Rupatadine	PAF, TNF	10 mg/24 h	Somnolence, headache, fatigue	Rupafin Alergoliber, Rinialer
	Ebastine	Antihistamine Antiallergic	10-20 mg/24 h	Headache, somnolence, fatigue, dryness of the mouth, rhinitis, pharyngitis	Ebastel
Alkylamine Piperazine	Acrivastine Cetirizine	Eosinophil adhesion Eosinophil and neutrophil chemotaxis T-cell and monocyte chemotaxis IL-8, MCP1/RANTES NF-kB 19 ICAM-1 LTC4	16-24 mg/24 h 10 mg/24 h	Headache, somnolence, fatigue Dryness of the mouth Gastrointestinal disturbances	Zyrtec Alerlisin Virlix
	Levocetirizine		5 mg/24 h		Xazal Aralevo

Abbreviations: GM-CSF, granulocyte-macrophage colony stimulating factor; ICAM, intercellular adhesion molecule; IL, interleukin; LTC₄, leukotriene C₄; MCP1, monocyte chemoattractant protein-1; NF-kB, nuclear factor-kappa B; PAF, platelet activation factor; RANTES, regulated and normal T-cell expressed and secreted; TNF, tumor necrosis factor; VEGF, vascular endothelial growth factor.

^a Trade names of drugs available in Spain

Tricyclic Antidepressants

The tricyclic antidepressants such as amitriptyline and, in particular, doxepin, have been widely used in the treatment of CU for their potent H₁- and H₂-antihistamine effect. However, their use is limited by their sedative and anticholinergic effects, which are potentiated by the use of alcohol, and by the relative risk of cardiac arrhythmias secondary to prolongation of the QT interval. Administration at night is usually recommended because of their sedative effects, and they are particularly useful in patients with concomitant depression. Doxepin is used at doses of 10–30 mg for the treatment of CU.^{13,18}

Antileukotrienes

The most widely used antileukotriene is montelukast, a leukotriene-receptor antagonist that has been used in the treatment of asthma and urticaria. There is very little evidence of its efficacy in monotherapy.^{2,3,10,33,34} These drugs can be combined with antihistamines in treatment-resistant urticaria. Although the response to these drugs is not highly predictable, there are studies that suggest that montelukast may be effective in the treatment of autoimmune urticaria, delayed pressure urticaria, and in urticaria complicated by intolerance to acetylsalicylic acid or to food coloring agents, but it has no or almost no demonstrated efficacy in chronic idiopathic urticaria. Montelukast has been used to treat eosinophilic urticaria (eosinophilic infiltrate present on skin biopsy) as activated eosinophils induce the synthesis of eicosanoid mediators generated from arachidonic acid and leukotrienes, particularly LTC₄, LTD₄, and LTE₃. The leukotrienes act by attracting cells to sites of inflammation and thus intensifying the inflammatory response.

Corticosteroids

No controlled studies have been performed on the use of corticosteroids for the treatment of urticaria or angioedema, but they are generally accepted as effective (grade D recommendation). They should be prescribed in short cycles and in tapering regimens for the treatment of severe exacerbations of CU, particularly when the condition is associated with angioedema, due to the risk of secondary respiratory difficulty. They may also be administered when difficulty is experienced in controlling symptoms with antihistamines in monotherapy or when a more rapid clinical improvement is sought. Corticosteroids have also been used for the treatment of urticarial vasculitis. The minimum effective dose should be administered and prolonged treatment should be avoided in order to avoid their side effects. Topical corticosteroids should not be used in CU.²

Ciclosporin A

CsA is an inhibitor of calcineurin, a protein with phosphatase activity that permits nuclear factor of T cells to pass from the cytoplasm into the nucleus, with expression of the IL-2 gene that activates T cells and stimulates the secretion of interferon- γ and GM-CSF. CsA therefore acts by blocking

Table 4 Contraindications to Treatment With Ciclosporin A.

Absolute Contraindications	Relative Contraindications
Poorly controlled hypertension	< 18 years or > 65 years
Kidney failure	Drug and alcohol abuse
History of malignancy	Pregnancy or breastfeeding
Uncontrolled infection	Severe liver dysfunction
No possibility of follow-up	Primary or secondary immunodeficiency
	Diabetes mellitus
	Epilepsy

the synthesis of IL-2, giving rise to a state of cellular and humoral immunosuppression.^{35,36} The main side effects of CsA are neurotoxicity and systemic hypertension (Table 4). In the management of CU, CsA is indicated in patients with severe CU with a positive ASST and who have not responded to antihistamines. It is used at doses of 3–5 mg/kg/d for periods of at least 2 months. The optimal dose and duration of treatment have not yet been defined nor do we have criteria for predicting a response.³⁷ Responses have been observed in patients with chronic spontaneous urticaria (with no evidence of functional antibodies, thus ASST negative), although this is not as well documented in the literature and the effects of treatment are less predictable than in patients with chronic autoimmune urticaria.³⁸

Tacrolimus

Tacrolimus has been used successfully to treat corticosteroid-dependent CU at doses of 0.5–2 mg/kg/d in 2 daily doses. It acts by inhibiting T lymphocytes and reducing the release of inflammatory cytokines.³⁹

Mycophenolate Mofetil

Mycophenolate mofetil is an immunomodulator drug that acts by inhibiting DNA synthesis in lymphocytes. It is a reversible inhibitor of inosine monophosphate dehydrogenase (present exclusively in lymphocytes and involved in purine synthesis). In CU, mycophenolate mofetil inhibits the production of antibodies to the high-affinity IgE receptor or to IgE itself. It also reduces the expression of adhesion molecules on endothelial cells and inhibits lymphocyte migration towards the skin.⁴⁰ In both autoimmune and idiopathic CU, mycophenolate mofetil has been found to be effective in reducing pruritus, the duration of the episode, the number of wheals, and the number of episodes of urticaria or angioedema. Complete remission has been reported in some cases. Mycophenolate mofetil has been used at doses of 500 mg/12 h for 2 to 4 weeks. It is a safe drug with few side-effects, which are mainly gastrointestinal at the doses used for the treatment of CU, and they can improve with time.⁴¹

Cyclophosphamide

Good results have been reported with intravenous cyclophosphamide; some patients with corticosteroid-dependent urticaria have achieved complete remission.⁴²

Methotrexate

Methotrexate can be useful in some cases as a corticosteroid-saving drug in patients with corticosteroid-dependent CU. It is used at doses of 10-15 mg per week.⁴³ The response does not appear to be related to the presence or absence of antibodies in the serum. The response is thought to be more closely related to its anti-inflammatory than to its immunosuppressant effect and it is therefore as successful in the treatment of chronic idiopathic urticaria as in chronic autoimmune urticaria.

Tumor Necrosis Factor Inhibitors

Little has been published in the literature about the treatment of CU with TNF inhibitors. Magerl et al.⁴⁴ described the case of a patient with psoriasis and delayed pressure CU in which treatment with etanercept achieved a rapid and lasting improvement.

Phototherapy

Phototherapy reduces the number of cutaneous mast cells in the superficial dermis.⁴⁵ It has been used for the treatment of idiopathic CU and in symptomatic dermatographism. UV-A, UV-B, or narrowband UV-B can be used for periods of 1 to 3 months. Narrowband UV-B has achieved good results as adjuvant therapy in combination with antihistamines. Long-term efficacy (up to 3 months after of the end of treatment) has been observed in some cases.⁴⁶

Intravenous Immunoglobulin

The indications for intravenous immunoglobulin approved by the Food and Drug Administration are primary immunodeficiencies, secondary immunodeficiencies, Kawasaki disease, and idiopathic thrombocytopenic purpura.⁴⁷ In CU, intravenous immunoglobulin has been used mainly for chronic autoimmune urticaria refractory to other treatments. O'Donnell et al.⁴⁸ treated 10 patients with severe chronic autoimmune urticaria with intravenous immunoglobulin at doses of 400 mg/kg/d for 5 days, achieving a clinical improvement in 9 of them—in 3 of those patients there was a long-term improvement. A good response has also been reported in some patients with delayed pressure urticaria and solar urticaria.⁴⁹ The mechanism of action is not fully understood, but it has been suggested that intravenous immunoglobulin may contain anti-idiotypic antibodies that compete with endogenous IgG for the H₁ receptors, blocking histamine release. Saturation of the Fc receptors by immunoglobulin prevents IgE from binding to the cutaneous mast cells and thus inhibits histamine release and the appearance of wheals. It is not known why the effect

persists over time. The cost of treatment is high and it has an elevated morbidity. There are no controlled studies.

Plasmapheresis

Plasmapheresis is an extracorporeal blood purification technique that consists of the separation of the plasma from the cellular components of the blood with the aim of removing the pathogenic elements causing the disease; in the case of CU, these elements are the histamine-releasing antibodies. Plasmapheresis has been used in cases of treatment-resistant CU,⁵⁰ although no controlled clinical trials have been performed. The cost of plasmapheresis is high and there is potential morbidity. Recurrence is common. In monotherapy, plasmapheresis is not sufficient to prevent the re-accumulation of histamine-releasing antibodies and it must be used in combination with immunosuppressant drugs.

Omalizumab

Omalizumab is a humanized recombinant monoclonal antibody that binds specifically to the C3 ϵ domain of the IgE heavy chain, the site that binds to the high-affinity IgE receptors on the surface of mast cells and basophils. It is currently only authorized for use in severe allergic asthma.⁵¹

There are 2 types of IgE receptors⁵²: the FC ϵ RI receptor present on mast cells, basophils, monocytes, eosinophils, and Langerhans cells; and the low-affinity receptors (FC ϵ RII/CD23), involved in antigen presentation (FC ϵ RII on B lymphocytes) and in the regulation of IgE synthesis. Omalizumab reduces the levels of free circulating IgE and secondarily reduces the density of IgE receptors on basophils and cutaneous mast cells, preventing their antibody-induced activation and degranulation. IgE can modulate the level of expression of its own high-affinity and low-affinity receptors. When IgE binds to FC ϵ RI on mast cells and basophils, it determines the levels of expression of the surface receptors, such that a higher concentration of IgE will increase the density of its receptors (and, hence, mast cell and basophil reactivity), whilst a lower concentration will reduce receptor density. When IgE binds to FC ϵ RI, an interaction occurs between the C3 domain of IgE and the α -chain of the receptor.⁵²⁻⁵⁷ Omalizumab may also act by reducing the number of IgE antithyroperoxidase autoantibodies, producing an inhibition of mast-cell degranulation by reducing the density of IgE receptors on their surface (negative feedback).⁵⁷

It has been observed that omalizumab is not only successful in the treatment of chronic autoimmune urticaria, but that it may also have a role in chronic idiopathic urticaria (ASST negative disease with no histamine release by basophils *in vitro*). This effect may be due to a direct action on mast cells, eosinophils, or basophils, even in the absence of autoantibodies. Another possible explanation is that omalizumab may prevent the FC ϵ RI-dependent secretion of cytokines and chemokines through some as yet unknown stimulus. A good response has been observed in physical urticarias (solar urticaria, heat urticaria, cold urticaria, delayed pressure urticaria, and cholinergic urticaria), although we only have isolated case

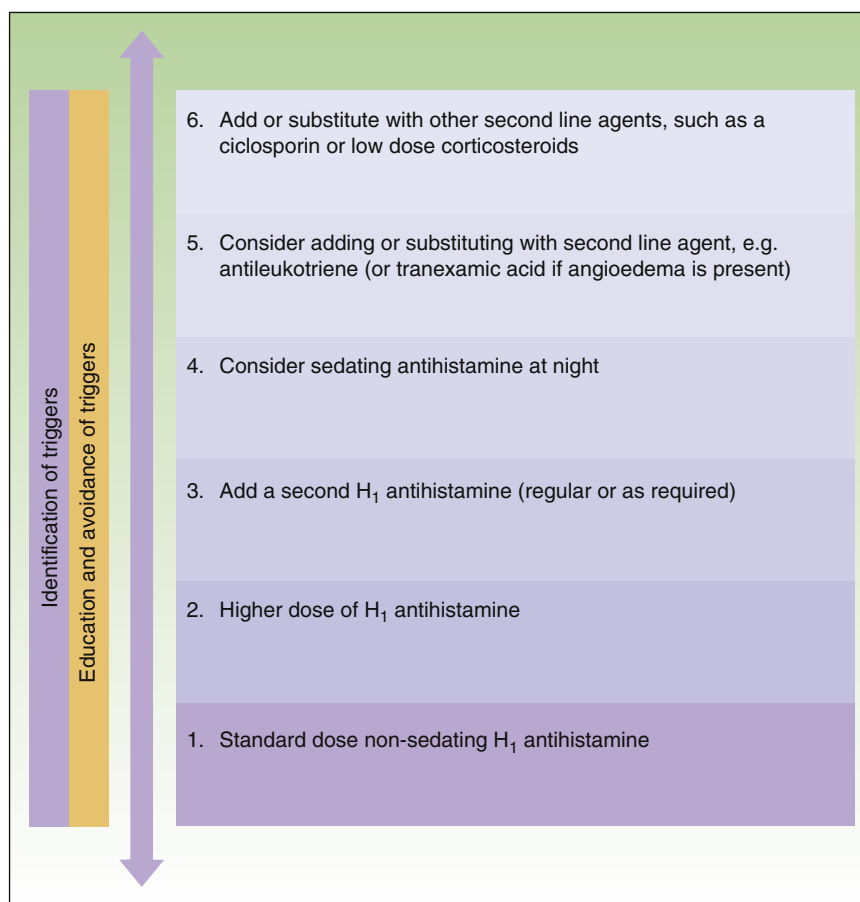


Figure 1 Treatment algorithm for chronic spontaneous urticaria based on the 2007 BSACI guidelines for the management of chronic urticaria and angioedema. Source: Standards of Care Committee, British Society for Allergy and Clinical Immunology, with permission.

reports and a larger number of studies are necessary to evaluate its potential efficacy.^{58–63}

In the treatment of severe allergic asthma, omalizumab is administered by subcutaneous injection at doses that vary between 75 mg and 375 mg, depending on body weight and IgE levels in the blood. In a recent study by Saini et al.,⁶⁴ a frank improvement in the urticaria activity score 7 (UAS7) with respect to baseline was observed 4 weeks after a single dose of 300 mg or 600 mg of omalizumab, and the treatment was more successful than placebo, with a rapid onset of effects (first week). However, no statistically significant difference with respect to placebo was observed with a dose of 75 mg. Taking into account that it is necessary to wait for up to 16 weeks to observe a response after the treatment of allergic asthma, it has been suggested that omalizumab could have an effect not only on IgE, but also a direct effect on mast cells.

In several studies it has been found that omalizumab reduces the UAS and the need for rescue medication and that it increases the therapeutic response and improves the quality of life of patients with CU.⁵² The side effects described are mostly mild (rhinopharyngitis, diarrhea, headache, local symptoms at the site of injection) although they can be more severe in occasional cases (anaphylaxis).

Other Treatments

Nifedipine

The results on the use of nifedipine in the treatment of urticaria are contradictory. It has been reported to be effective in reducing pruritus and wheal formation in patients with CU when combined with high-dose antihistamines.⁶⁵ However, in other studies, nifedipine has been found to have little effect on CU.¹¹ Nifedipine acts by modifying calcium entry into the cutaneous mast cells. It may be a drug to consider in patients with systemic hypertension, particularly in those taking ACE inhibitors.

Anticoagulation and Antifibrinolysis

In some patients with CU, thrombin levels have been found to be elevated due to activation of the coagulation cascade via the extrinsic pathway, and signs of fibrinolysis with elevated plasma D-dimer levels were also observed. This occurred in more severe cases of CU with a poorer response to first-line treatment with antihistamines.^{66–69} It has been suggested that thrombin could increase vascular

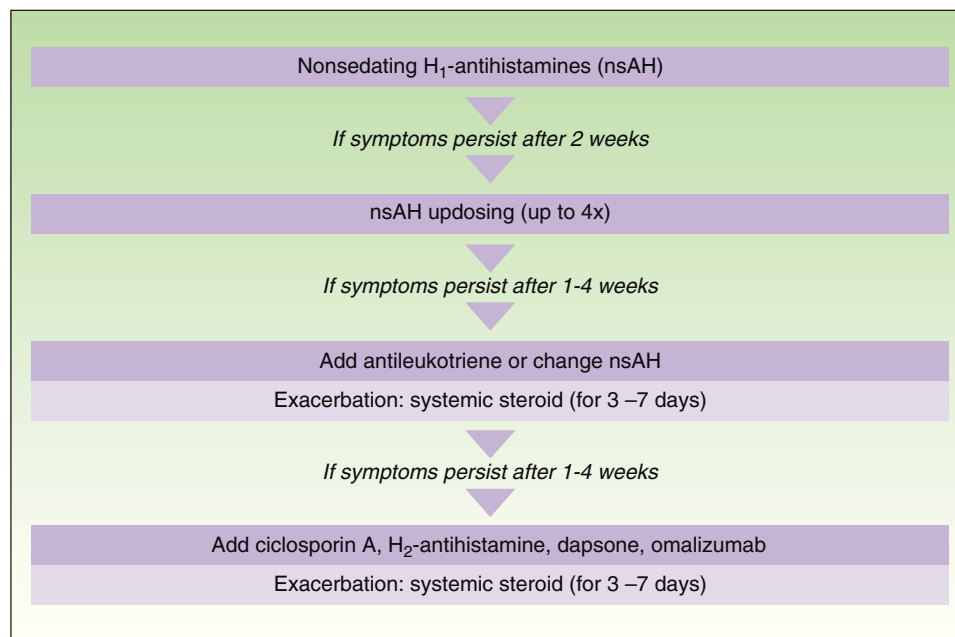


Figure 2 Treatment algorithm for chronic spontaneous urticaria based on the 2009 European guidelines of the European Academy of Allergology and Clinical Immunology, the Global Allergy and Asthma European Network, the European Dermatology Forum, and the World Allergy Organization. With the permission of the authors. In the 2012 update consensus, the recommendation for the use of dapsone and H₂-antihistamines was withdrawn. Increases in the dose of nonsedative H₁-antihistamines of up to 4 times the approved doses was recommended and omalizumab, ciclosporin A, and antileukotrienes were maintained for second-line treatment.

permeability, activating mast-cell degranulation and the complement cascade in the absence of C3. Activation of the coagulation cascade in these patients is associated with a poorer response to treatment with antihistamines at approved doses. D-dimer levels could serve as a marker to identify this group of patients with chronic idiopathic urticaria. In these patients, combined treatment with an anticoagulant (heparin) and an antifibrinolytic (tranexamic acid) could be useful, as this situation affects a subgroup of patients in whom we would be blocking a mechanism of activation of inflammation.⁷⁰

Dapsone

Dapsone (4-49-diaminodiphenylsulfone) is a sulfone derivative that has antimicrobial and anti-inflammatory effects and has been used for many years to treat a wide variety of skin diseases with neutrophilic dermal infiltrates, including urticarial vasculitis, Behçet disease, and pyoderma gangrenosum. Dapsone alone or combined with other treatments is considered a therapeutic option for the treatment of urticaria. Anecdotally, there have been occasional reports of an improvement in chronic idiopathic urticaria and delayed pressure urticaria.⁷¹

Colchicine

Colchicine has been widely used for the treatment of a heterogeneous group of skin diseases typically characterized by the presence of neutrophilic dermal infiltrates, including psoriasis, leukocytoclastic vasculitis, and urticarial vasculitis. Colchicine limits the chemotactic and phagocytic

activity of neutrophils and suppresses leukocyte function by increasing the levels of cyclic adenosine monophosphate in the cytoplasm and by inhibiting lysosome degranulation.^{72,73} The increased levels of cyclic adenosine monophosphate release prostaglandin E, which suppresses leukocyte function. Oka et al.⁷⁴ demonstrated that colchicine causes the depolymerization of microtubules crucial for mast-cell degranulation. The inhibitory effect of colchicine in urticaria could be due to a dual effect: chemotactic blockade of the neutrophils and reduced mast-cell degranulation. It has occasionally been used in patients with urticarial vasculitis.

Sulfasalazine

Sulfasalazine belongs to a group of antifolate drugs and has been used for many years in the treatment of inflammatory bowel diseases and rheumatoid arthritis. Its main side effects are liver toxicity, neurotoxicity, and myelotoxicity. The mechanism of action of sulfasalazine in CU is unknown. It may affect IgE-mediated histamine release and reduce the activity of prostaglandin synthetase. It could be useful as a corticosteroid-saving drug.⁷⁵ There are few controlled studies on its use in CU.

Hydroxychloroquine

Hydroxychloroquine has been used in the treatment of hypocomplementemic urticarial vasculitis syndrome.⁷⁶

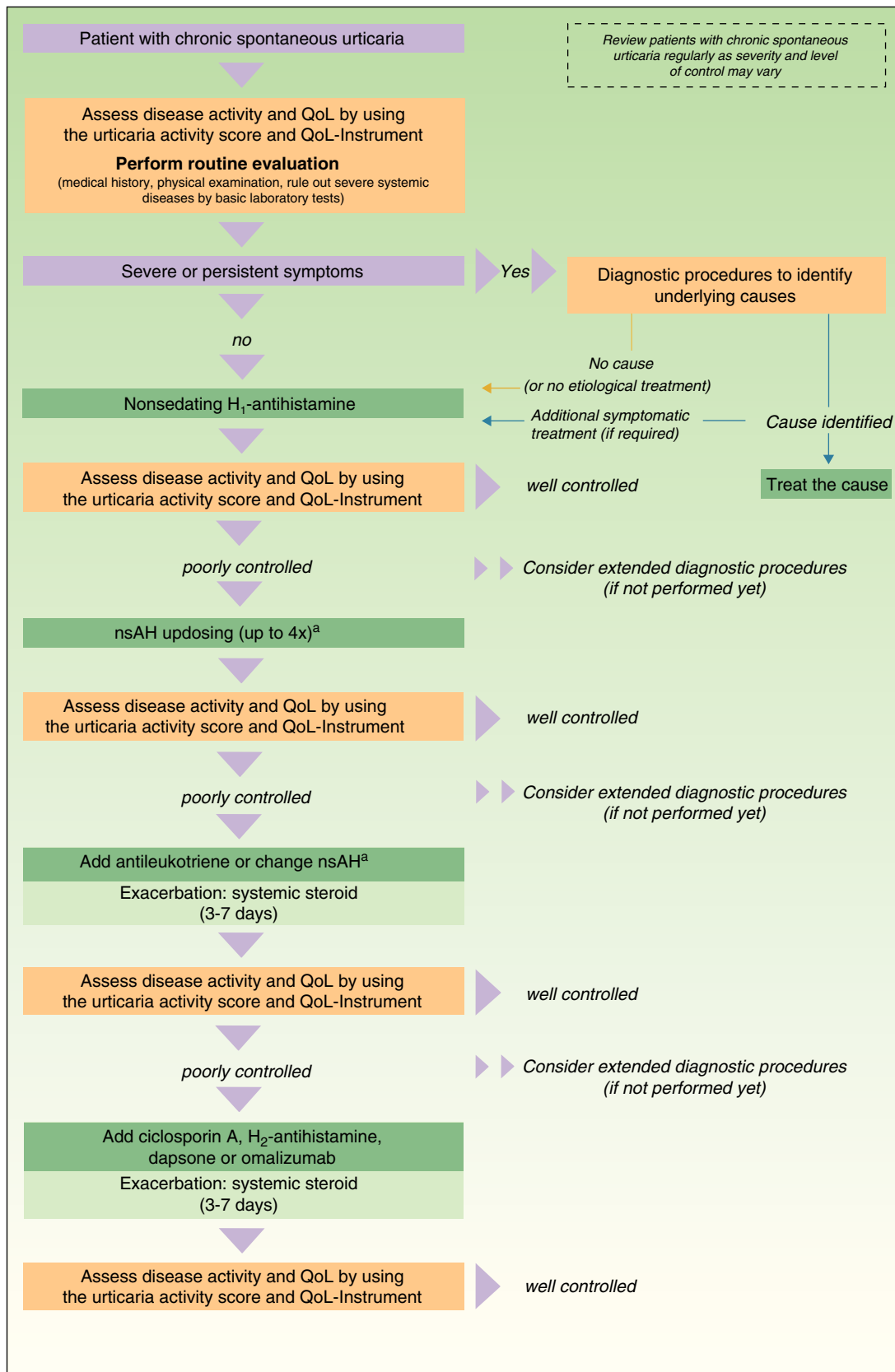


Figure 3 Algorithm for the management of patients with chronic spontaneous urticaria. Source: Maurer et al.,⁵ with the permission of the authors.

QoL indicates quality of life; nsAH, non-sedating antihistamine.

^a Based on the algorithm for the management of patients with chronic spontaneous urticaria. Source: Maurer et al.,⁵ with permission.

Recommendations of the European Guidelines

The management and treatment of patients with CU is complex. For this reason, consensus guidelines based on scientific evidence and on expert opinion have been drawn up for the management of this disease. The 2 existing guidelines for the management of CU are the "BSACI guidelines for the management of chronic urticaria and angio-oedema," drawn up by the British Society for Allergy and Clinical Immunology² (BSACI) and published in *Clinical and Experimental Allergy* in 2007, and the European guidelines of the EAACI/GA2LEN/EDF/WAO, published in *Allergy* in 2009.¹⁰ The European guidelines are the result of the consensus reached by a discussion panel at the Third International Consensus Meeting on Urticaria in 2008 by the Dermatology Section of the European Academy of Allergology and Clinical Immunology (EAACI), the Global Allergy and Asthma European Network (GA2LEN), the European Dermatology Forum (EDF), and the World Allergy Organization (WAO).

The main difference between the 2 guidelines in the treatment algorithm for CU is that the British guidelines continue to recommend the use of sedative antihistamines at night if non-sedative antihistamines have not been effective, even at high doses, whereas the European guidelines do not recommend these drugs in any case^{2,10} (Figs. 1 and 2).

In November 2012, in Berlin, at the fourth consensus meeting to update the guidelines for chronic spontaneous urticaria, certain changes were introduced into the management algorithm for CU. As the algorithm only included those treatment options supported by a high level of recommendation, the use of dapsone and of the H₂-antihistamines was withdrawn. In view of the failure of the use of the non-sedative H₁-antihistamines at the approved doses, an increase of up to 4 times that dose was recommended. Omalizumab, ciclosporin A, and the antileukotrienes continue to figure as second-line treatment. These drugs are used in addition to the H₁-antihistamines. However, reading of the entire guidelines is recommended as the use of other therapeutic options that do not figure in the algorithm is not rejected for certain patients (Fig. 3).

Ethical Disclosures

Protection of human and animal subjects. The authors declare that no experiments were performed on humans or animals for this investigation.

Confidentiality of data. The authors declare that no private patient data are disclosed in this article.

Right to privacy and informed consent. The authors declare that no private patient data are disclosed in this article.

Conflicts of Interest

The authors declare that they have no conflicts of interest.

References

- Zuberbier T, Asero R, Bindslev-Jensen C, Walter CG, Church MK, Gimenez-Arnau A, et al. EAACI/GA2LEN/EDF guideline: definition, classification and diagnosis of urticaria. *Allergy*. 2009;64:1417–26.
- Powel RJ, Du Toit GL, Siddique N, Leech SC, Dixon TA, Clark AT, et al., British Society for Allergy and Clinical Immunology (BSACI). BSACI guidelines for the management of chronic urticaria and angio-oedema. *Clin Exp Allergy*. 2007;37:631–50.
- Poonawalla T, Kelly B. Urticaria. A review. *Am J Clin Dermatol*. 2009;10:9–21.
- Kaplan AP. Chronic urticaria: pathogenesis and treatment. *J Allergy Clin Immunol*. 2004;114:465–74.
- Maurer M, Weller K, Bindsley-Jensen C, Giménez-Arnau A, Bousquet PJ, Bousquet J, et al. Unmet clinical needs in chronic urticaria. *J Allergy Clin Immunol*. 2002;109:114–8.
- Kikuchi Y, Kaplan AP. A role for C5a in augmenting IgG-dependent histamine release from basophils in chronic urticaria. *J Allergy Clin Immunol*. 2002;109:114–8.
- Gaig P, Olona M, Muñoz Lejarazu D, Caballero MT, Domínguez FJ, Echechipia S, et al. Epidemiology of urticaria in Spain. *Investig Allergol Clin Immunol*. 2004;14:214–20.
- O'Donnell BF, Lawlor F, Simpson J, Morgan M, Greaves MW. The impact of chronic urticaria on the quality of life. *Br J Dermatol*. 1997;136:197–201.
- Grob J, Revuz J, Ortonne JP, Auguier P, Lorette G. Comparative study of the impact of chronic urticaria, psoriasis and atopic dermatitis on the quality of life. *Br J Dermatol*. 2005;152:289–95.
- Zuberbier T, Asero R, Bindslev-Jensen C, Walter CG, Church MK, Gimenez-Arnau A, et al. EAACI/GA2LEN/EDF guideline: management of urticaria. *Allergy*. 2009;64:1427–43.
- Grattan C, Powell S, Humphreys F, British Association of Dermatologists. Management and diagnostic guidelines for urticaria and angio-oedema. *Br J Dermatol*. 2001;144:708–14.
- Phanuphak P, Schocket AL, Arroyave CM, Kohler PF. Skin histamine in chronic urticaria. *J Allergy Clin Immunol*. 1980;65:371–5.
- Jáuregui I, Ferrer M, Montoro J, Dávila I, Bartra J, del Cuvillo A, et al. Antihistamines in the treatment of chronic urticaria. *J Invest Allergol Clin Immunol*. 2007;17:41–52.
- Mullol J, Bousquet J, Bachert WG, Canonica A, Gimenez-Arnau A, Kowalski ML, et al. Rupatadine in allergic rhinitis and chronic urticaria. *Allergy*. 2008;63:5–28.
- Gimenez-Arnau A, Izquierdo I, Maurer M. The use of a responder analysis to identify clinically meaningful differences in chronic urticaria patients following placebo controlled treatment with rupatadine 10 and 20 mg. *J Eur Acad Dermatol Venereol*. 2009;23:1088–91.
- Kajiwara N, Sasaki T, Bradding P, Cruse G, Sagara H, Ohmori K, et al. Activation of human mast cells through the platelet-activating factor receptor. *J Allergy Clin Immunol*. 2010;125:1137–45.
- Krause K, Martínez-Escala E, Farré-Albadalejo M, Church MK, Abajian M, Giménez-Arnau A, et al. Intradermal injections of platelet-activating factor (PAF) result in wheal-and-flare type skin reactions but do not induce mast cell degranulation. *J Invest Dermatol*. 2011;131 suppl 2:S14.
- Lee EE, Maibach HI. Treatment of urticaria. An evidence-based evaluation of antihistamines. *Am J Clin Dermatol*. 2001;2:27–32.
- Breneman DL. Cetirizine versus hydroxyzine and placebo in chronic idiopathic urticaria. *Ann Pharmacother*. 1996;30:1075–9.
- Staevska M, Popov TA, Kralimarkova T, Lazarova C, Kraeva S, Popova D, et al. The effectiveness of levocetirizine and

- desloratadine in up to 4 times conventional doses in difficult-to-treat urticaria. *J Allergy Clin Immunol.* 2010;125:676–82.
21. Potter PC, Kapp A, Maurer M, Guillet G, Jian AM, Hauptmann P, et al. Comparison of the efficacy of levocetirizine 5 mg and desloratadine 5 mg in chronic idiopathic urticaria patients. *Allergy.* 2009;64:596–604.
 22. Gillman S, Gillard M, Benedetti MS. The concept of receptor occupancy to predict clinical efficacy: a comparison of second generation H1 antihistamines. *Allergy Asthma Proc.* 2009;30:366–76.
 23. Grattan CE, Humphreys F. Guidelines for evaluation and management of urticaria in adults and children. *Br J Dermatol.* 2007;157:1116–23.
 24. Spencer CM, Faulds D, Peters DH. Cetirizine. A reappraisal of its pharmacological properties and therapeutic use in selected allergic disorders. *Drug.* 1993;46:1055–80.
 25. Grant AJ, Riethuisen JM, Moulart B, DeVos C. A double-blind, randomized, single dose, crossover comparison of levocetirizine with ebastine, fexofenadine, loratadine, mizolastine and placebo: suppression of histamine-induced wheal-and-flare response during 24 hours in healthy male subjects. *Ann Allergy Asthma Immunol.* 2002;88:190–7.
 26. Bousquet J, Czarlewski W, Danzig MR. Antiallergic properties of loratadine: a review. *Adv Ther.* 1995;12:283–98.
 27. Henz BM. The pharmacologic profile of desloratadine: a review. *Allergy.* 2001;56 Suppl. 65:7–13.
 28. Ring J, Hein R, Gauger A. Desloratadine in the treatment of chronic idiopathic urticaria. *Allergy.* 2001;56:28–32.
 29. Sastre J. Ebastine in allergic rhinitis and chronic idiopathic urticaria. *Allergy.* 2008;63:1–20.
 30. Gimenez-Arnau A, Pujol RM, Ianosi S, Kaszuba A, Malbran A, Poop G, et al. Rupatadine Urticaria Study Group. Rupatadine in the treatment of chronic idiopathic urticaria: a double-blind, randomized, placebo-controlled multicentre study. *Allergy.* 2007;62:539–46.
 31. Metz M, Maurer M. Rupatadine for the treatment of allergic rhinitis and urticaria. *Expert Rev Clin Immunol.* 2011;7:15–20.
 32. Compalati E, Baena-Cagnani R, Penagos M, Badellino H, Braidó F, Gómez RM, et al. Systematic review on the efficacy of fexofenadine in seasonal allergic rhinitis: a meta-analysis of randomized, double-blind, placebo-controlled clinical trials. *Int Arch Allergy Immunol.* 2011;156:1–15.
 33. Scadding GW, Scadding GK. Recent advances in antileukotriene therapy. *Curr Opin Allergy Clin Immunol.* 2010;10:370–6.
 34. Kong-Sang W. Efficacy of leukotriene receptor antagonist with an anti-H1 receptor antagonist for treatment of chronic idiopathic urticaria. *J Dermatolog Treat.* 2009;20:194–7.
 35. Casolmo V, Spadero G, Patella V, Marone G. In vivo characterization of the anti-inflammatory effect of cyclosporine A on human basophils. *J Immunol.* 1993;151:5563–73.
 36. Stellato C, de Paulis A, Ciccarelli A, Cirillo R, Patella A, Casolaro V, et al. Anti-inflammatory effect of cyclosporin A on human skin mast cells. *J Invest Dermatol.* 1992;98:800–4.
 37. Di Gioacchino M, di Stefano F, Cavallucci E, Verna N, Ramondo S, Paolini F, et al. Treatment of chronic idiopathic urticaria and positive autologous serum skin test with cyclosporine: clinical and immunological evaluation. *Allergy Asthma Proc.* 2003;24:285–90.
 38. Grattan CE, O'Donnell BF, Francis DM, Niimi N, Barlow RJ, Seed PT, et al. Randomized double-blind study of cyclosporin in chronic 'idiopathic' urticaria. *Br J Dermatol.* 2000;143:365–72.
 39. Stanaland BE. Treatment of patients with chronic idiopathic urticaria. *Clin Rev Allergy Immunol.* 2002;23:233–41.
 40. Shahar E, Bergman R, Guttman-Yassky E, Pollack S. Treatment of severe chronic idiopathic urticaria with oral mycophenolate mofetil in patients not responding to antihistamines and/or corticosteroids. *Int J Dermatol.* 2006;45:1224–7.
 41. Zimmerman AB, Berger EM, Elmariah SB, Soter NA. The use of mycophenolate mofetil for the treatment of autoimmune and chronic idiopathic urticaria: Experience in 19 patients. *J Am Acad Dermatol.* 2011;66:767–70.
 42. Bernstein JA, Garramone SM, Lower EG. Successful treatment of autoimmune chronic idiopathic urticaria with intravenous cyclophosphamide. *Ann Allergy Asthma Immunol.* 2002;89:212–4.
 43. Perez A, Woods A, Grattan CEH. Methotrexate: a useful steroid-sparing agent in recalcitrant chronic urticaria. *Br J Dermatol.* 2010;162:191–4.
 44. Magerl M, Philipp S, Manasterski M, Friedrich M, Maurer M. Successful treatment of delayed pressure urticaria with anti-TNF- α . *J Allergy Clin Immunol.* 2007;119:752–4.
 45. Hannuksela M, Kokkonen EL. Ultraviolet light therapy in chronic urticaria. *Acta Derm Venereol.* 1985;65:449–50.
 46. Engin B, Ozdemir M, Balevi A, Mevliotoglu I. Treatment of chronic urticaria with narrowband ultraviolet B phototherapy: a randomized controlled trial. *Acta Derm Venereol.* 2008;88:247–51.
 47. Figueroa A, Altamirano L, Amores M, Bertotti A, Cueto A, Diaz Livadiotis G, et al. Inmunoglobulina endovenosa en enfermedades neuromusculares. Guías para su utilización. *Rev Neurol Arg.* 2006;31:32–46.
 48. O'Donnell BF, Barr RM, Black AK, Francis DM, Kermani F, Niimi N, et al. Intravenous immunoglobulin in autoimmune chronic urticaria. *Br J Dermatol.* 1998;138:101–6.
 49. Adamski H, Bedane C, Bonneville A, Thomas P, Peyron JL, Rouchouse B, et al. Solar urticaria treated with intravenous immunoglobulins. *J Am Acad Dermatol.* 2011;65:336–40.
 50. Grattan CE, Francis DM, Slater NG, Barlow RJ, Greaves MW. Plasmapheresis for severe, unremitting, chronic urticaria. *Lancet.* 1992;339:1078–80.
 51. Félix Toledo R, Martínez López R, Negro Álvarez JM, Ramírez Hernández M, Mérida Fernández C. Anti-IgE (omalizumab) in the treatment of allergic rhinitis. *Alergol inmunol Clin.* 2004;19:133–9.
 52. Kaplan AP, Joseph K, Mayjut RJ, Geba GP, Zeldin RK. Treatment of chronic autoimmune urticaria with omalizumab. *J Allergy Clin Immunol.* 2008;122:569–73.
 53. Grattan CE, Francis DM, Hide M, Greaves MW. Detection of circulating histamine releasing autoantibodies with functional properties of anti-IgE in chronic urticaria. *Clin Exp Allergy.* 1991;21:695–704.
 54. Gober LM, Sterba PM, Eckman JA, Saini SS. Effect of anti-IgE (omalizumab) in chronic idiopathic urticaria (CIU) patients. *J Allergy Clin Immunol.* 2008;121:S147.
 55. Magerl M, Staubach P, Altrichter S, Ardelean E, Krause K, Metz M, et al. Effective treatment of therapy-resistant chronic spontaneous urticaria with omalizumab. *J Allergy Clin Immunol.* 2010;126:665–6.
 56. Spector SL, Tan RA. Effect of omalizumab on patients with chronic urticaria. *Ann Allergy Asthma Immunol.* 2007;99:190–3.
 57. Maurer M. Efficacy and safety of omalizumab in patients with chronic urticaria who exhibit IgE against thyroperoxidase. *J Allergy Clin Immunol.* 2011;128:202–9.
 58. Metz M, Bergmann P, Zuberbier T, Maurer M. Successful treatment of cholinergic urticaria with anti-immunoglobulin E therapy. *Allergy.* 2008;63:247–9.
 59. Güzelbey O, Ardelean E, Magerl M, Zuvervier T, Maurer M, Metz M. Successful treatment of solar urticaria with anti-immunoglobulin E therapy. *Allergy.* 2008;63:1563–5.
 60. Waibel KJ, Reese DA, Hamilton RG, Devillez RL. Partial improvement of solar urticaria after omalizumab. *J Allergy Clin Immunol.* 2010;125:490–1.
 61. Bullerkotte U, Wiczorek D, Kapp A, Wedi B. Effective treatment of refractory severe heat urticaria with omalizumab. *Allergy.* 2010;65:931–2.

62. Bindslev-Jensen C, Skov PS. Efficacy of omalizumab in delayed pressure urticaria: a case report. *Allergy*. 2010;65:138–9.
63. Sabroe RA. Failure of omalizumab in cholinergic urticaria. *Clin Exp Dermatol*. 2009;35:127–9.
64. Saini S, Rosen KE, Hsieh HJ, Wong DA, Conner E, Kaplan A, et al. A randomized, placebo-controlled, dose-ranging study of single-dose omalizumab in patients with H1-antihistamine refractory chronic idiopathic urticaria. *J Allergy Clin Immunol*. 2011;128:567–73.
65. Bressler RB, Sowell K, Huston DP. Therapy of chronic idiopathic urticaria with nifedipine: demonstration of beneficial effect in a double-blinded, placebo-controlled, crossover trial. *J Allergy Clin Immunol*. 1989;83:756–63.
66. Asero R, Tedeschi A, Riboldi P, Cugno M. Plasma of patients with chronic urticaria shows signs of thrombin generation, and its intradermal injection causes wheal-and-flare reactions much more frequently than autologous serum. *J Allergy Clin Immunol*. 2006;117:1113–7.
67. Asero R, Tedeschi A, Coppola R, Griffini S, Paparella P, Riboldi P, et al. Activation of the tissue factor pathway of blood coagulation in patients with chronic urticaria. *J Allergy Clin Immunol*. 2007;119:705–10.
68. Asero R, Tedeschi A, Riboldi P, Griffini S, Bonanni E, Cugno M. Severe chronic urticaria is associated with elevated plasma levels of D-dimer. *Allergy*. 2008;63:176–80.
69. Takahagi S, Mihara S, Iwamoto K, Morioka S, Okabe T, Kameyoshi Y, et al. Coagulation/fibrinolysis and inflammation markers are associated with disease activity in patients with chronic urticaria. *Allergy*. 2010;65:649–56.
70. Asero R, Tedeschi A, Cugno M. Heparin and tranexamic acid therapy may be effective in treatment-resistant chronic urticaria with elevated D-Dimer: a pilot study. *Int Arch Allergy Immunol*. 2010;152:384–9.
71. Boehm I, Bauer R, Bieber T. Urticaria treated with dapson. *Allergy*. 1999;54:765–6.
72. Borstad GC, Bryant LR, Abel MP, Scroggie DA, Harris MD, Alloway JA. Colchicine for prophylaxis of acute flares when initiating allopurinol for chronic gouty arthritis. *J Rheumatol*. 2004;31:2429–32.
73. Sullivan TP, King LEJr, Boyd AS. Colchicine in dermatology. *J Am Acad Dermatol*. 1998;39:993–9.
74. Oka T, Hori M, Ozaki H. Microtubule disruption suppresses allergic response through the inhibition of calcium influx in the mast cell degranulation pathway. *J Immunol*. 2005;174:4584–9.
75. Hartmann K, Hani N, Hinrichs R, Hunzelmann N, Scharffetter-Kochanek K. Successful sulfasalazine treatment of severe chronic idiopathic urticaria associated with pressure urticaria. *Acta Derm Venereol*. 2000;81:71.
76. Lopez LR, Davis KC, Kohler PF, Schocket AL. The hypocomplementemic urticarial-vasculitis syndrome: therapeutic response to hydroxychloroquine. *J Allergy Clin Immunol*. 1984;73:600–3.