

the present case since our patient did not fulfill the criteria for any other condition and experienced chronic, relapsing annular neutrophilic lesions.

## References

1. Christensen OB, Holst R, Svensson A. Chronic recurrent annular neutrophilic dermatosis. An entity? *Acta Derm Venereol.* 1989;69:415–8.
2. Arnett FC, Edworthy SM, Bloch DA, McShane DJ, Fries JF, Cooper NS, et al. The American Rheumatism Association 1987 revised criteria for the classification of rheumatoid arthritis. *Arthritis Rheum.* 1988;31:315–24.
3. Garcia-Rio I, Perez-Gala S, Aragues M, Fernandez-Herrera J, Fraga J, Garcia-Diez A. Sweet's syndrome on the area of postmastectomy lymphoedema. *J Eur Acad Dermatol Venereol.* 2006;20:401–5.
4. Petit T, Frances C, Marinho E, Herson S, Chosidow O. Lymphoedema-area-restricted Sweet syndrome during G-CSF treatment. *Lancet.* 1996;347:690.
5. Sayah A, English JC 3rd. Rheumatoid arthritis: a review of the cutaneous manifestations. *J Am Acad Dermatol.* 2005;53:191–209, quiz 10-2.
6. Cabanillas M, Suarez-Amor O, Sanchez-Aguilar D, Pereiro MM, Toribio J. Chronic recurrent neutrophilic dermatosis: a possible variant in the spectrum of neutrophilic dermatoses. *Actas Dermosifiliogr.* 2008;99:61–3.
7. Koguchi H, Arita K, Yamane N, Shinkuma S, Shimizu H. Erythema annulare centrifugum-like neutrophilic dermatosis: effects of potassium iodide. *Acta Derm Venereol.* 2012;92:333–4.

J.M. Mir-Bonafé,<sup>a,\*</sup> J.C. Santos-Durán,<sup>b</sup> A. Santos-Briz,<sup>c</sup> E. Fernández-López<sup>b</sup>

<sup>a</sup> Department of Dermatology, Hospital Clinic, University of Barcelona, Spain

<sup>b</sup> Department of Dermatology, University Hospital of Salamanca, Paseo de San Vicente 58-182, 37007 Salamanca, Spain

<sup>c</sup> Department of Pathology, University Hospital of Salamanca, Paseo de San Vicente 58-182, 37007 Salamanca, Spain

\* Corresponding author.

E-mail address: [jmirbonafe@gmail.com](mailto:jmirbonafe@gmail.com) (J.M. Mir-Bonafé).

## Scarring Alopecia in Classic Adult Type I Pityriasis Rubra Pilaris<sup>☆</sup>



### Alopecia cicatricial en pitiriasis rubra pilaris tipo I clásica del adulto

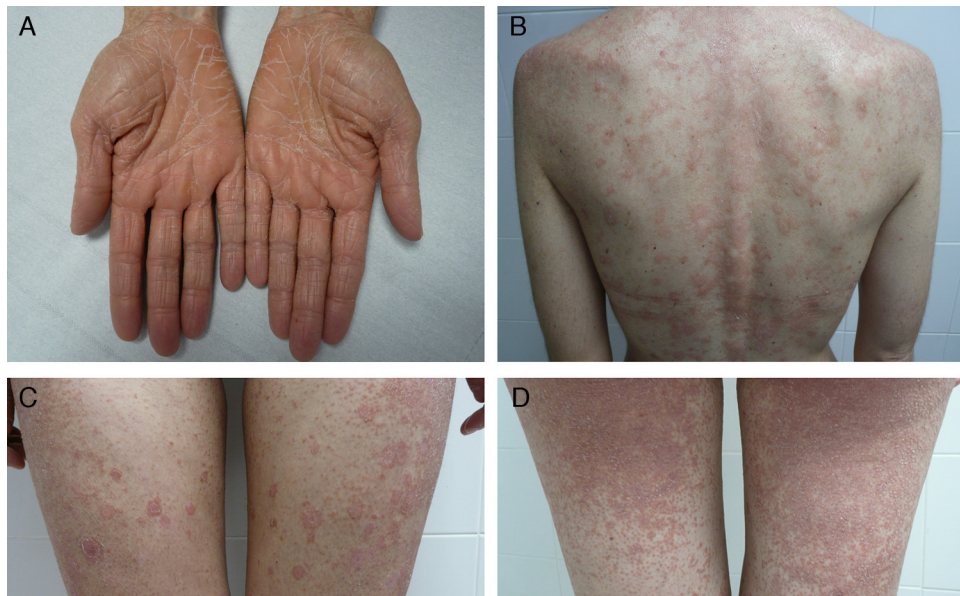Pityriasis rubra pilaris (PRP) is an inflammatory disease of unknown etiology<sup>1</sup> with an estimated incidence ranging from 1 in 5000 to 1 in 50 000 dermatology patients. The established Griffiths classification recognizes 5 groups (types I-V) according to clinical features and patient age.<sup>2</sup> More recently, Miralles et al.<sup>3</sup> added a sixth group after observing clinical differences in cases associated with human immunodeficiency virus (HIV) infection. Type I (classic adult PRP) is the most common subtype. Complete remission is achieved within 3 years of onset in 80% of cases,<sup>1</sup> whereas recurrence occurs in 20% of cases. Systemic retinoids, specifically acitretin, are the current first-line treatment.

We report for the first time a case of classic adult type I PRP associated at first recurrence with rapidly developing disseminated scarring alopecia of the scalp. The patient was a 41-year-old woman with no relevant past history who presented with a pruritic rash that had appeared 3 weeks earlier at the same time as an orange-hued waxy palmoplantar keratoderma (Fig. 1, A). The trunk and the proximal extrem-

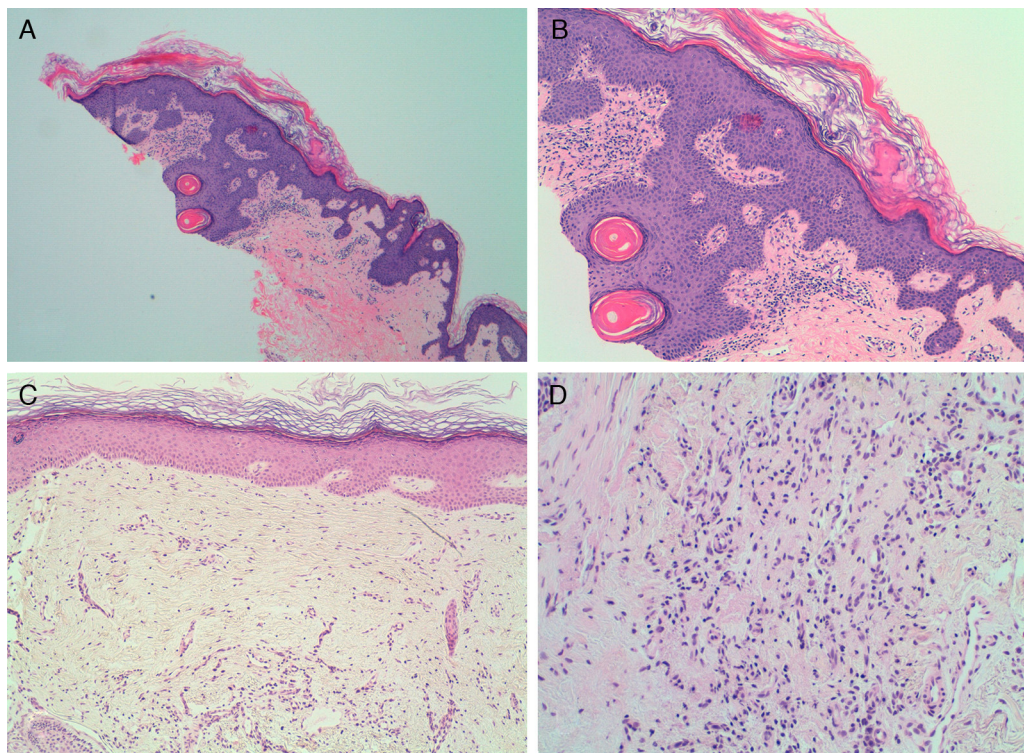
ities had orange-red lesions with some apparently healthy areas of skin (Fig. 1, B-D). Skin biopsy confirmed the suspected diagnosis of classic adult type I PRP. Findings included alternating hyperkeratosis and parakeratosis as well as psoriasiform acanthosis (Fig. 2, A and B). Treatment was started with 25 mg of oral acitretin daily. After 8 months of treatment the rash had cleared completely; we thus decided to discontinue treatment 2 months later. The patient returned after 10 lesion-free months complaining of a new crop of skin lesions similar to the original ones. This new bout occurred together with what appeared to be a severe form of scarring alopecia forming irregular patches on the scalp. The hairless patches were pearly and shiny, with fine scaling and perifollicular erythema. The clinical course was fulminant, and after 2 weeks the only scalp finding was atrophic alopecia patches with no erythema or scaling (Fig. 3). A biopsy specimen obtained from the periphery of one of the hairless patches and comprising some follicles and perifollicular erythema exhibited significant perifollicular stellate fibrosis replacing the follicles, with no signs of inflammatory infiltrate (Fig. 2, C and D). Direct immunofluorescence was negative. Blood tests showed no abnormalities; test results for antinuclear antibodies, cryoglobulins, and antineutrophil cytoplasmic antibodies were all negative, and hepatitis B and C, HIV, and syphilis were ruled out. The rash cleared after 4 months of oral acitretin treatment, but the scarring alopecia persisted without change. The patient has worn a wig since then and has had no further bouts of PRP. Her scarring alopecia could not be reversed and remains stable at the time of writing in 2013, after 3 years of follow-up from initial presentation.

The onset of scarring alopecia of the scalp in conjunction with a second bout of type I PRP suggested to us that alope-

<sup>☆</sup> Please cite this article as: Martín Callizo C. Alopecia cicatricial en pitiriasis rubra pilaris tipo I clásica del adulto. *Actas Dermosifiliogr.* 2014;105:955–957.

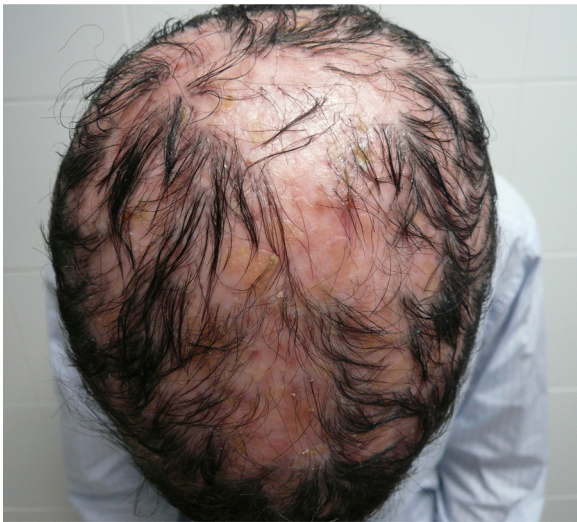

**Figure 1** First bout of type I pityriasis rubra pilaris. A, Waxy palmar keratoderma. B-D, Scaly, orange-red patches on the trunk and limbs with islands of sparing and marked follicular hyperkeratosis.



**Figure 2** A and B, Skin biopsy of a pityriasis rubra pilaris lesion showing hyperkeratosis alternating with parakeratosis. A, Hematoxylin-eosin, original magnification  $\times 4$ . B, Hematoxylin-eosin, original magnification  $\times 10$ . C and D, Scalp biopsy with stellate perifollicular dermal fibrosis. No perifollicular inflammatory infiltrate is seen. C, Hematoxylin-eosin, original magnification  $\times 10$ . D, Hematoxylin-eosin, original magnification  $\times 20$ .





**Figure 3** Second bout of type I pityriasis rubra pilaris. Large patches of scarring alopecia with follicular flaking and patchy perifollicular erythema that developed into atrophic pearly patches without erythema or scaling.

cia might have been induced by the follicular involvement characteristic of PRP.

Although fine scaling of the scalp and face is frequent in type I PRP,<sup>2</sup> and is sometimes accompanied by non-scarring alopecia,<sup>4</sup> an association of type I PRP with scarring alopecia has not been described before. In 1968, Bergeron and Stone<sup>5</sup> reported the case of a patient with PRP who developed acne conglobata, hidradenitis suppurativa, and dissecting cellulitis of the scalp. Acitretin-induced scarring alopecia has never before been reported,<sup>6</sup> and in any case, our patient was no longer taking acitretin at the onset of the second bout and of scarring alopecia. The follicular hyperkeratosis and perifollicular erythema of the scalp present during both bouts of type I PRP could have disturbed our patient's hair follicles enough to trigger fulminant scarring alopecia.

The clinical appearance of our patient's scarring alopecia is reminiscent of pseudopelade of Brocq in large, scattered patches. It is unclear whether pseudopelade is a disease in

itself or the final stage of other, primary forms of scarring alopecia. In the initial stage, our patient's condition resembled lichen planopilaris or cutaneous lupus erythematosus. Nevertheless, the absence of any perifollicular lymphocytic inflammatory infiltrate, the replacement of hair follicles with dermal fibrosis, and the negative direct immunofluorescence test results make lichen, lupus, and pseudopelade unlikely diagnoses.

We therefore consider this to be a case of scarring alopecia of an unusually fulminant course and severity associated with a bout of type I PRP, and with histologic findings that rule out a primary classic form of scarring alopecia. The alopecia underwent rapid clinical transformation into generalized pseudopelade in large patches, but the only histologic finding was fibrosis.

## References

1. Klein A, Landthaler M, Karrer S. Pityriasis rubra pilaris: a review of diagnosis and treatment. *Am J Clin Dermatol.* 2010;11:157–70.
2. Griffiths WA. Pityriasis rubra pilaris. *Clin Exp Dermatol.* 1980;5:105–12.
3. Miralles ES, Núñez M, de Las Heras ME, Pérez B, Moreno R, Ledo A. Pityriasis rubra pilaris and human immunodeficiency virus infection. *Br J Dermatol.* 1995;133:990–3.
4. Albert MR, Mackool BT. Pityriasis rubra pilaris. *Int J Dermatol.* 1999;38:1–11.
5. Bergeron JR, Stone OJ. Follicular occlusion triad in a follicular blocking disease (pityriasis rubra pilaris). *Dermatologica.* 1968;136:362–7.
6. Chave TA, Mortimer NJ, Hutchinson PE. Agranulocytosis and total scalp alopecia following acitretin. *Br J Dermatol.* 2003;148:1063–4.

C. Martín Callizo,<sup>a,\*</sup> J. Molinero Caturla,<sup>a</sup>  
J. Sánchez Sánchez,<sup>a</sup> R.M. Penín Mosquera<sup>b</sup>

<sup>a</sup> *Servicio de Dermatología, Hospital Universitari de Bellvitge, Barcelona, Spain*

<sup>b</sup> *Servicio de Anatomía Patológica, Hospital Universitari de Bellvitge, Barcelona, Spain*

\* Corresponding author.

*E-mail address:* [claramartincallizo@gmail.com](mailto:claramartincallizo@gmail.com)  
(C. Martín Callizo).

## Penile Paraffinoma<sup>☆</sup>



### Parafinoma de pene

Penile paraffinoma is a skin reaction that develops after the injection of paraffin or mineral oil into the penis in order to increase its size. The condition is relatively common in some eastern European and Asian countries and we believe immigration will cause its frequency in Spain to rise. The procedure is usually performed by nonmedically

qualified persons and under poor hygienic conditions. The skin reaction to the exogenous material typically develops months or years after the injection.<sup>1</sup>

We present the case of a 27-year-old man from Romania who consulted for ulcerated lesions on the penis. Although the patient initially omitted the fact, he later stated that for the previous 4 years until 2 months prior to consultation he had undergone repeated injections of a viscous material into the shaft of the penis in order to increase its size. He also stated that progressively enlarging ulcerated lesions had appeared on the penis and that they had worsened in appearance over the previous months. He had therefore

<sup>☆</sup> Please cite this article as: Gómez-Armayones S, Penín R, Marcoval J. Parafinoma de pene. *Actas Dermosifiliogr.* 2014;105:957–959