




ACTAS Derma-Sifiliográficas

Full English text available at
www.actasdermo.org



IMAGES IN DERMATOLOGY

Calciphylaxis and Ecthyma Gangrenosum in Chronic Kidney Disease: Clinical Similarities[☆]



Calcifilaxis y ectima gangrenoso en insuficiencia renal crónica: semejanzas clínicas

G. Blasco-Morente,^{*} C. Garrido-Colmenero, J.M. Latorre-Fuentes

Unidad de Gestión Clínica Dermatología Médico Quirúrgica y Venereología, Hospital Universitario Virgen de las Nieves, Granada, Spain

Received 22 January 2015; accepted 27 February 2015

Two patients on hemodialysis for chronic kidney failure developed fever. The first patient was a 53-year-old woman who was seen for a painful and indurated necrotic plaque that had developed 20 days earlier on the anterior aspect of the right thigh (Fig. 1A). The relevant findings in the laboratory tests were calcemia, 8.6 mg/dL, and parathyroid hormone, 569 pg/ml. On computed tomography there were areas of calcification in the subcutaneous cellular tissue beneath the lesion, and skin biopsy was compatible with calciphylaxis. Treatment was started with sodium thiosulfate 20 mg/48 h and meropenem 500 mg/12 h but the lesions did not improve and the patient died. The second patient was a man aged 56 years who was seen for an indurated, painful plaque on the lateral aspect of the thigh. The plaque had a central blister of serous fluid with a necrotic base (Fig. 1B). Histopathology revealed necrotizing panniculitis and *Pseudomonas aeruginosa* was cultured from the skin biopsy. The patient was diagnosed with ecthyma gangrenosum and the lesion healed after 10 days of treatment

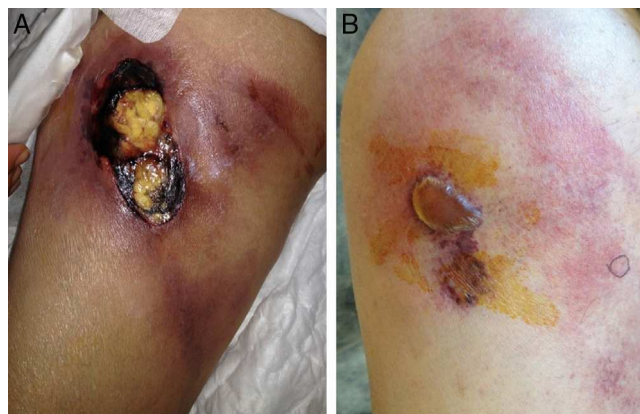

Figure 1 A, Indurated erythematous plaque with a central ulcer on the anterior aspect of the right thigh. B, Indurated erythematous plaque on the lateral aspect of the right thigh; there is a central blister of serous fluid with a necrotic base.

[☆] Please cite this article as: Blasco-Morente G, Garrido-Colmenero C, Latorre-Fuentes JM. Calcifilaxis y ectima gangrenoso en insuficiencia renal crónica: semejanzas clínicas. Actas Dermosifiliogr. 2015;106:510.

^{*} Corresponding author.

E-mail address: gonzaloblascomorente@gmail.com (G. Blasco-Morente).

with ciprofloxacin 250 mg/12 h. Calciphylaxis and ecthyma gangrenosum in patients with chronic kidney failure are rare conditions due, respectively, to secondary hypoparathyroidism and immunosuppression. Both conditions are painful and are usually associated with fever. The clinical manifestations are similar in the initial stages, and recognition is therefore important to avoid a delay in starting treatment.