




ACTAS Derma-Sifiliográficas

Full English text available at
www.actasdermo.org



IMAGES EN DERMATOLOGY

Long-Standing Presternal Plaque[☆]



Placa preesternal de larga evolución

G. Blasco-Morente,^{*} C. Garrido-Colmenero, I. Pérez-López, J. Espelt-Otero

Unidad de Gestión Clínica de Dermatología Médico Quirúrgica y Venereología, Hospital Universitario Virgen de las Nieves, Granada, Spain

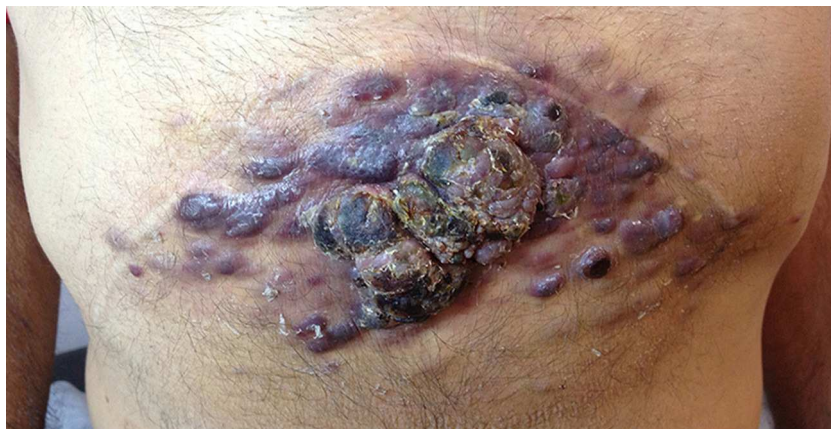

Figure 1 Presternal plaque of 15 x 30 cm formed by the coalescence of multiple erythematous-violaceous tumors with maximum individual diameters of 2-3 cm.

The patient was a 61-year-old man who had undergone liver transplant for alcoholic cirrhosis 3 years earlier and was on treatment with tacrolimus, 7 mg/d, and mycophenolate mofetil, 1.5 g/d. He was seen for a 2-year history of skin lesions that had arisen in the pre-sternal region and that produced occasional bleeding and caused discomfort due to friction with clothing. There were no systemic alterations. Physical examination revealed multiple erythematous-violaceous tumors (maximum diameters, 2-3 cms) that had coalesced into a large pre-sternal plaque. Some of the tumors had ulcerated and presented a central

bloodstained scab (Fig. 1). Histopathology findings on the skin biopsy were compatible with plaque-stage Kaposi sarcoma and immunohistochemistry confirmed the presence of human herpesvirus 8. Blood tests including complete blood count and biochemistry were normal, and serology for human immunodeficiency virus was negative. Thoracic and abdominal computed tomography showed no pathological findings. The diagnosis of Kaposi sarcoma was thus confirmed and radiotherapy treatment was administered, achieving a partial improvement of the clinical manifestations. Kaposi sarcoma is a multifocal systemic tumor associated with human herpesvirus 8 infection. It develops in 0.1% to 5% of transplant recipients. This variant is most common in renal transplant recipients, usually arising in the 2 first years after transplantation. Treatment is symptomatic combined, when possible, with a reduction in immunosuppressant therapy. During follow-up it is important to exclude systemic involvement, which typically affects the digestive tract.

[☆] Please cite this article as: Blasco-Morente G, Garrido-Colmenero C, Pérez-López I, Espelt-Otero J. Placa preesternal de larga evolución. Actas Dermosifiliogr. 2015;106:585.

^{*} Corresponding author.

E-mail address: gonzaloblascomorente@gmail.com (G. Blasco-Morente).