


# ACTAS Derma-Sifiliográficas

Full English text available at  
www.actasdermo.org



## CASE FOR DIAGNOSIS

### Can You Identify the Genodermatosis?★



¿Qué genodermatosis es?

#### Patient History

A 5-year-old boy from Colombia with no known family history of skin disease presented with asymptomatic lesions on the limbs, predominantly in acral regions and areas around the joints. His family reported slow, peripheral growth of the lesions over the past few months but were unable to specify exactly when the clinical signs first appeared. No other associated symptoms were present at any level.

#### Physical Examination

Physical examination revealed keratotic, lichenoid plaques with mild peripheral erythema affecting the hips, acral regions, and areas around the joints on all 4 limbs, especially on extensor surfaces (Fig. 1). The development of the boy was normal for his age.

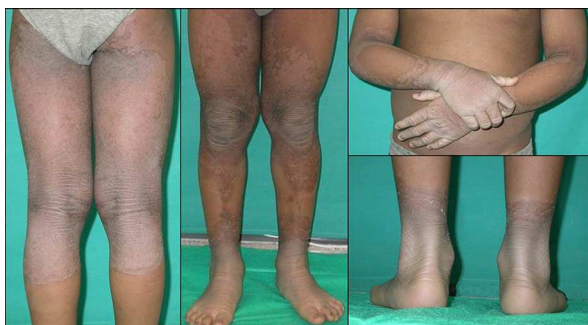

Figure 1

#### Histopathology

Histologic examination revealed hyperkeratosis with focal parakeratosis, hypergranulosis, and acanthosis with elongated rete ridges (Fig. 2).

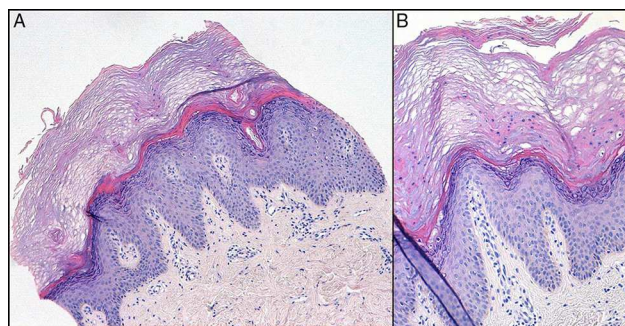


Figure 2 A, Hematoxylin-eosin, original magnification  $\times 100$ . B, Hematoxylin-eosin, original magnification  $\times 200$ .

What Is Your Diagnosis?

★ Please cite this article as: Santesteban Muruzábal R, Hervella Garcés M, Ros Martín C. ¿Qué genodermatosis es?. Actas Dermosifiliogr. 2014;106:667–668.

## Diagnosis

Progressive symmetric erythrokeratoderma (PSEK).

## Clinical Course and Treatment

Topical treatment was started with 20% urea cream and systemic treatment was started with oral acitretin at a dose of 0.5 mg/kg/d. Patient tolerance was good. Over several months, the lesions clearly involuted until they were limited to the acral regions of the limbs and the flexures, with a minimal effective dose of 0.3 mg/kg/d. Periodic blood tests were carried out at follow-up visits, and no abnormalities caused by the treatment were observed. Adherence to treatment has been erratic over several years of follow-up at our dermatology clinic; periods of evident exacerbation have coincided with the voluntary withdrawal of the medication. The patient, now 14 years old, continues to receive treatment with acitretin at a minimum effective dose of 0.3 mg/kg/d (Fig. 3).

## Comment

Erythrokeratodermas are a clinically and genetically heterogeneous group of skin diseases characterized by well-defined erythematous-keratotic plaques.<sup>1-3</sup> There are various subtypes, the most important of which are PSEK and erythrokeratoderma variabilis.<sup>4-6</sup> PSEK is a rare genodermatosis that has been associated with a mutation in the *loricrin* gene on chromosome 1q21,<sup>1,4,5</sup> although it is genetically heterogeneous.<sup>2</sup> In most cases, PSEK is hereditary, with autosomal dominant inheritance, incomplete penetrance, and variable expressivity,<sup>1,2,6</sup> although sporadic cases<sup>4,6</sup> and cases with a recessive inheritance pattern<sup>2</sup> have also been reported.

Clinically, PSEK is characterized by the appearance of large, erythematous, orange-colored, well-defined, symmetrical plaques that in some cases can have a keratotic or verrucous appearance, usually located on the buttocks, cheeks, and limbs.<sup>2,6</sup> Palmoplantar involvement has been

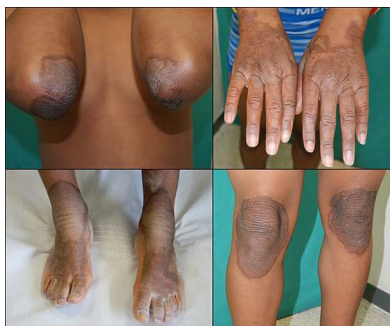

Figure 3

reported in up to 50% of cases.<sup>4,6</sup> The lesions usually appear in the first years of life and spread slowly or remain stable during the following years; spontaneous improvement sometimes occurs, usually during puberty.<sup>1,6</sup>

Histologic findings are nonspecific, with foci of parakeratosis and marked acanthosis.<sup>1,4</sup> Perinuclear vacuolization can be observed in the granular cell layer.<sup>4</sup>

PSEK is treated symptomatically. Topical treatments—including emollients and keratolytic agents—are reserved for the mildest cases.<sup>1,4</sup> For severe cases, systemic treatment—oral retinoids, such as acitretin at a dose of 0.5 mg/kg/d—is usually added. Psoralen-UV-A phototherapy has also been used, with variable clinical responses.<sup>1,4</sup>

We have presented a new case of PSEK, a rare entity. The case is unusual because it is sporadic, autosomal dominant inheritance being more common in this disease.

## Conflicts of Interest

The authors declare that they have no conflicts of interest.

## References

1. Bilgin I, Bozdogan KE, Uysal S, Ermete M. Progressive symmetrical erythrokeratoderma - response to topical calcipotriol. *J Dermatol Case Rep.* 2011;5:50-2.
2. Akman A, Masse M, Mihci E, Richard G, Christiano AM, Balle BJ, et al. Progressive symmetrical erythrokeratoderma: Report of a Turkish family and evaluation for *loricrin* and *connexin* gene mutations. *Clin Exp Dermatol.* 2008;33:582-4.
3. Guo BR, Sun LD, Cui Y, Yang S, Zhang XJ. Progressive symmetrical erythrokeratoderma: Report of two Chinese families and evaluation for mutations in the *loricrin*, *connexin 30.3* and *connexin 31* genes. *Clin Exp Dermatol.* 2013;38:925-7.
4. Álvarez-Vieitez A, Torrelo A, Medeiro IG, Zambrano A. Symmetric progressive erythrokeratoderma. *Actas Dermosifiliogr.* 1999;90:633-5.
5. Ishida-Yamamoto A, McGrath JA, Lam H, Iizuka H, Friedman RA, Christiano AM. The molecular pathology of progressive symmetric erythrokeratoderma: A frameshift mutation in the *loricrin* gene and perturbations in the cornified cell envelope. *Am J Hum Genet.* 1997;61:581-9.
6. Rodero J, Torrelo A, Medeiro IG, Zambrano A. Generalized progressive symmetric erythrokeratoderma. *Actas Dermosifiliogr.* 2001;92:207-9.

R. Santesteban Muruzábal,\* M. Hervella Garcés,  
C. Ros Martín

*Servicio de Dermatología, Hospital de Navarra, Complejo Hospitalario de Navarra, Pamplona, Navarre, Spain*

\* Corresponding author.

E-mail address: [raquel.santesteban@hotmail.com](mailto:raquel.santesteban@hotmail.com)  
(R. Santesteban Muruzábal).