

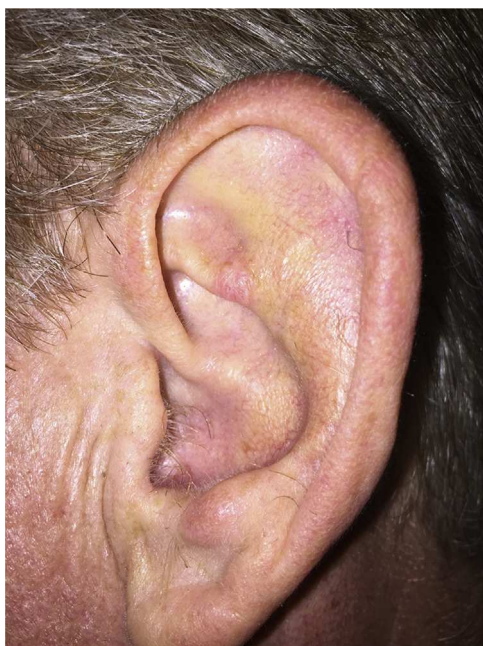

Figure 3 Resolved lesion 1 year after the patient started using a hands-free device.

patient, the use of a hands-free device to avoid recurrent trauma in the region was sufficient to cure the lesion.

We have presented a case of CN antihelicis caused by work-related mobile telephone use for many hours a day. Although this etiology is not reported frequently in the literature, physicians should take into account the widespread use of mobile telephones when trying to determine the cause of this dermatosis and prescribe treatment.

References

1. Thompson LD. Chondrodermatitis nodularis helicis. *Ear Nose Throat J.* 2007;86:734–5.
2. Chan HP, Neuhaus IM, Maibach HI. Chondrodermatitis nodularis chronica helicis in monozygotic twins. *Clin Exp Dermatol.* 2008;34:358–9.
3. Upile T, Patel NN, Jerjes W, Singh NU, Sandison A, Michaels L. Advances in the understanding of chondrodermatitis nodularis chronica helicis: The perichondrial vasculitis theory. *Clin Otolaryngol.* 2009;34:147–50.
4. Wagner G, Liefelth J, Sachse MM. Clinical appearance, differential diagnoses and therapeutical options of chondrodermatitis nodularis chronica helicis Winkler. *J Dtsch Dermatol Ges.* 2011;9:287–91.
5. Gilaberte Y, Frias MP, Pérez-Lorenz JB. Chondrodermatitis nodularis helicis successfully treated with photodynamic therapy. *Arch Dermatol.* 2010;146:1080–2.
6. Garrido Colmenero C, Martínez García E, Blasco Morente G, Tercedor Sánchez J. Nitroglycerin patch for the treatment of chondrodermatitis nodularis helicis: A new therapeutic option. *Dermatol Ther.* 2014;27:278–80.
7. Yélamos O, Dalmau J, Puig L. Chondrodermatitis nodularis helicis tratada con éxito con nitroglicerina al 2% en gel. *Actas Dermosifiliogr.* 2013;104:531–2.
8. Rex J, Ribera M, Bielsa I, Mangas C, Xifra A, Ferrándiz C. Narrow elliptical skin excision and cartilage shaving for treatment of chondrodermatitis nodularis. *Dermatol Surg.* 2006;32:400–4.

A. Ortiz,* P. Martín, J. Domínguez, J. Conejo-Mir

Unidad de Gestión Clínica de Dermatología, Hospital Universitario Virgen del Rocío, Seville, Spain

*Corresponding author.

E-mail address: ale.ortizprieto@hotmail.com (A. Ortiz).

Alopecia and Hirsutism in a Postmenopausal Woman as the Presenting Complaint of Ovarian Hilus (Leydig) Cell Tumor[☆]



Alopecia e hirsutismo en una mujer posmenopáusica como forma de presentación de un tumor de células de Leydig hiliar del ovario

To the Editor:

Female androgenetic alopecia is one of the main causes of hair loss, and affects 50% of women in their lifetime.¹ Alopecia and hirsutism as a manifestation of hyperandrogenism in postmenopausal women can have various causes, ranging

from normal physiological changes to an ovarian or adrenal tumor. Recommended tests in any woman presenting with alopecia are a detailed clinical history, physical examination, general blood tests (including complete blood count and thyroid stimulating hormone and ferritin levels) and a hormone study with measurement of dehydroepiandrosterone sulfate and total and free testosterone levels.

We present the case of a 65-year-old woman who presented with a 1-year history of hair loss and black facial hair. There was no past history of alopecia, hirsutism, or hyperandrogenism. Her history was remarkable for cardiovascular risk factors (hypertension, dyslipidemia, and diabetes mellitus), and she was also being monitored by the endocrinology department for euthyroid goiter. The physical examination showed frontoparietal hair loss in a triangular-shaped pattern (Fig. 1 A) and diffuse thinning on the crown (Fig. 1 B). These findings were consistent with male-pattern female hair loss grade II in the Ebling classification system. The patient also had hirsutism (Ferriman-Gallwey score 9), located predominantly on the face and sides of the neck but also in the chin area (Fig. 2). Examination of the external genitalia revealed an enlarged clitoris. There were no other signs of virilization, such as voice deepening or increased muscle bulk.

[☆] Please cite this article as: Berbegal L, Albares MP, De-Leon FJ, Negueruela G. Alopecia e hirsutismo en una mujer posmenopáusica como forma de presentación de un tumor de células de Leydig hiliar del ovario. *Actas Dermosifiliogr.* 2015;106:676–678.

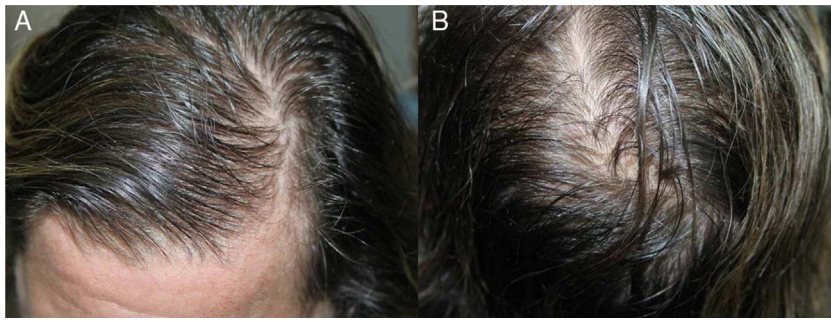

Figure 1 A, Triangular-shaped frontoparietal hairline recession. B, Hair thinning on the crown.

Considering the physical findings, we requested blood tests with complete blood count, biochemistry, erythrocyte sedimentation rate, thyroid hormones, and iron profile. The results were all within normal ranges. A hormone study showed hyperandrogenism, with elevated testosterone levels (4.06 ng/mL; normal range, 0.20-0.80 ng/mL). The tests also showed a level of 28 nmol/L for sex hormone binding globulin (normal range, 11-124 nmol/L) and a free testosterone index of 45 (normal range, 1.6-6). Free testosterone is the biologically active fraction of testosterone. Androstenedione, dehydroepiandrosterone sulfate, and 17-hydroxyprogesterone levels were all within normal limits. Estradiol levels were high due to peripheral aromatization of testosterone.

The results suggested an ovarian tumor and we ordered a vaginal ultrasound, which revealed no alterations. The patient was referred to the endocrinology department for further testing, including tumor marker and imaging tests. Prolactin and cortisol tests were normal, as were the results for all tumor markers analyzed except carcinoembryonic antigen, with a level of 14.5 ng/mL (normal range, 0-5 ng/mL). An abdominal computed tomography scan showed images consistent with a left adrenal tumor (Fig. 3). Magnetic resonance imaging of the pelvis showed no signs of an ovarian tumor. With these findings, it was decided to perform a left adrenalectomy, but the patient continued to show high testosterone levels (4.06 ng/mL; normal range, 0.20-0.80) and a high free testosterone index (42.6; nor-

mal range, 1.6-6) after the operation. Finally, given the strong suspicion of hyperandrogenism of ovarian origin, we performed a bilateral adnexectomy.

The histologic study confirmed a diagnosis of Leydig cell tumor, hilar type, in the right ovary. At the time of writing, 2 months after the adnexectomy, the patient's testosterone levels have returned to normal and there are evident improvements in her hirsutism and alopecia.

Alopecia and hirsutism can be the presenting manifestation of a tumor,² as shown by the case reported herein. Hilar Leydig cell tumors of the ovary are very rare and account for just 0.5% of all ovarian tumors. Accordingly, very few cases have been described in the literature. Although benign, these tumors frequently cause virilization, with increased androgen production,³⁻⁵ and they are also associated with an increased risk of thromboembolism.⁶ Leydig tumor cells in the ovary can be very small and may go undetected in imaging studies. This is why adnexectomy is frequently per-

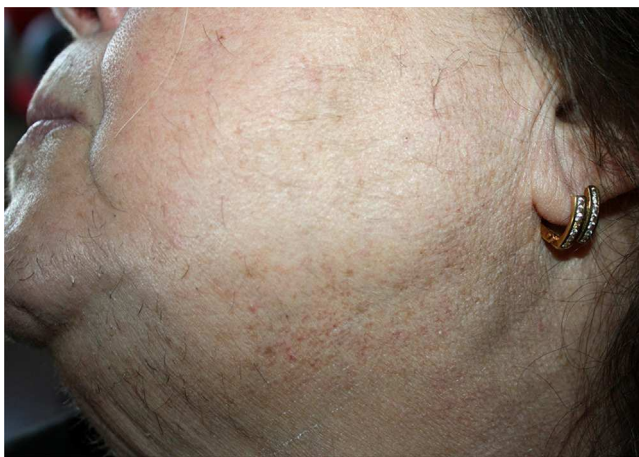

Figure 2 Hirsutism affecting the chin and sides of the face and neck.

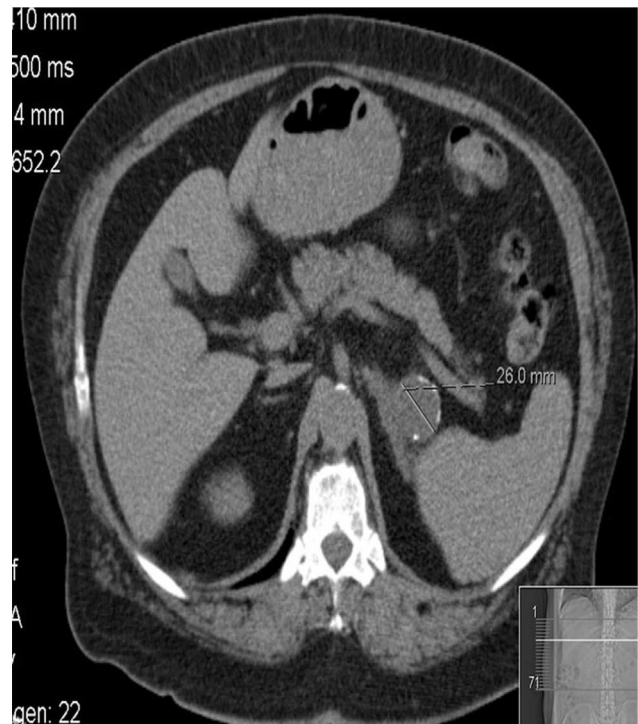


Figure 3 Left adrenal nodule measuring 2.6 cm.

formed as part of a diagnosis of exclusion.⁷ Adnexectomy of just the affected ovary is an option in premenopausal women. The ovary to be removed is identified during surgery by measuring testosterone levels in the ovarian veins.⁸

Hyperandrogenism, particularly with signs of virilization, is very uncommon in postmenopausal women and tends to be due to tumors (mainly of ovarian or adrenal origin).⁹ Other causes that should be ruled out, however, are drugs, pituitary disorders, and the ectopic production of hormones by tumors. The severity of the hyperandrogenism, the patient's age, and the speed with which signs and symptoms appear are all important diagnostic clues.

References

- Rivera R, Guerra-Tapia A. Manejo de las mujeres posmenopáusicas en la alopecia androgenética. *Actas Dermosifiliogr.* 2008;99:257–61.
- Yuste M, Unamuno P. Alertas cutáneas en malignidades sistémicas. *Actas Dermosifiliogr.* 2013;104:543–53.
- Bajocchi G, Mancini N, Angeletti G, Celleno R, Fratini D, Gilardi G. Pure Leydig cell tumour (hilus cell) of the ovary: A rare cause of virilization after menopause. *Gynecol Obstet Invest.* 1997;44:141–4.
- Bancos I, Prawius H. Leydig cell tumor of the ovary postmenopausal woman presenting with virilization. *The Endocrinologist.* 2008;18:146–9.
- Sanz OA, Martinez PR, Guarch RT, Goñi MJ, Alcazar JL. Bilateral Leydig cell tumour of the ovary: A rare cause of virilization in postmenopausal patient. *Maturitas.* 2007;57:214–6.
- Kozan P, Chalasan S, Handelsman DJ, Pike AH, Crawford BA. A Leydig cell tumor of the ovary resulting in extreme hyperandrogenism, erythrocytosis, and recurrent pulmonary embolism. *J Clin Endocrinol Metab.* 2014;99:12–7.
- Marcelino M, Nobre E, Conceição J, Lopes L, Vilar H, França Martins M, et al. A rare case of hyperandrogenism: Bilateral Leydig cell tumor of the ovary. *Acta Med Port.* 2010;23:113–8.
- Regnier C, Bennet A, Malet D, Guez T, Plantavid M, Rochaix P, et al. Intraoperative testosterone assay for virilizing ovarian tumor topographic assessment: Report of a Leydig cell tumor of the ovary in a premenopausal woman with an adrenal incidentaloma. *J Clin Endocrinol Metab.* 2002;87:3074–7.
- Salman P, Cuello M, Kolbach M, Gejman R, Arteaga E. Hiperandrogenismo avanzado en una mujer posmenopáusica. Caso clínico. *Rev Med Chile.* 2011;139:1066–70.

L. Berbegal,^{a,*} M.P. Albares,^a F.J. De-Leon,^a G. Negueruela^b

^a Servicio de Dermatología, Hospital General Universitario de Alicante, Alicante, Spain

^b Servicio de Endocrinología, Hospital General Universitario de Alicante, Alicante, Spain

* Corresponding author.

E-mail address: lauraberbegal@gmail.com (L. Berbegal).

Diagnostic Value of Color Doppler Ultrasound for Cutaneous Odontogenic Sinus Tract[☆]



Utilidad de la ecografía doppler color para el diagnóstico de fistulas dentocutáneas

The patient was a 32-year-old man with no past history of interest. He was seen in dermatology outpatients for a tumor in the form of a cutaneous horn sunken into the skin over the left horizontal ramus of the mandible (Fig. 1). Examination revealed no alterations of the oral cavity. The patient stated that the region was tender. He had applied topical treatment with 2% mupirocin ointment without improvement. B mode skin ultrasound (Esaote, Genoa, Italy) using an 18 MHz probe revealed a slightly tortuous, relatively well-defined, hypoechoic linear structure that extended to the surface of the cortical bone of the mandible (Fig. 2). Doppler study showed blood vessels in the area around the tract, suggestive of inflammation, and a poorly defined hypoechoic outline in B mode (Fig. 3). With a diagnosis of cutaneous odontogenic sinus, the patient was referred to the maxillofacial surgery department, where the study was completed with orthopan-

tomography. This x-ray study revealed a radiolucent image that surrounded the apex of the posterior root of the left first molar (Fig. 4). Conservative treatment was performed with endodontia and restoration with an amalgam filling, leading to resolution of the cutaneous sinus in 20 days.

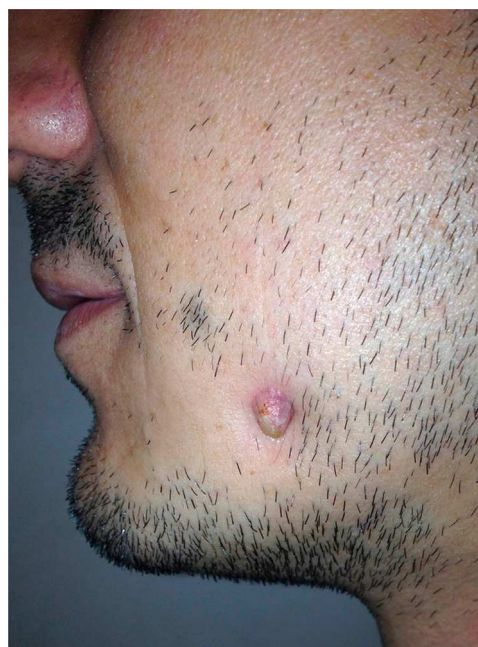

Figure 1 Cutaneous horn sunken into the skin over the left horizontal ramus of the mandible.

[☆] Please cite this article as: Garrido Colmenero C, Blasco Morente G, Latorre Fuentes JM, Ruiz Villaverde R. Utilidad de la ecografía doppler color para el diagnóstico de fistulas dentocutáneas. *Actas Dermosifiliogr.* 2015;106:678–680.