

Erythema Multiforme Contact Dermatitis After Accidental Exposure to Acrylate-based Printing Inks[☆]



Eritema multiforme de contacto tras exposición accidental a acrilatos en tintas de impresión

To the Editor:

Acrylates are well recognized as allergens. People working in the graphic arts field are exposed to acrylate-based printing inks and are therefore at high risk for occupational allergic contact dermatitis to acrylates.¹ The most commonly used acrylic monomers in the printing process are 2-hydroxyethyl acrylate, 2-hydroxypropyl acrylate, 2-hydroxypropyl methacrylate, 2-hydroxyethyl methacrylate, and 2-ethyl acrylate.²

We present the case of a 26-year-old printing worker whose forearms came into contact with waste ink that spilled from a container. He was not exposed to sunlight or UV light and washed the affected area after the spill. Three days later, he began to experience intense pruritus, and vesicles began to appear on the wrists and forearms. The intensity of the lesions increased during the following days, with the appearance of multiple targetoid erythematous-edematous macules in the neighboring areas of the forearms and arms (Fig. 1) and on the face, trunk, and extremities at some distance from the ink splashes (Fig. 2). The patient had no history of skin disease, infection, or ingestion of medication during the previous months.

Analysis of a biopsy specimen revealed vacuolar degeneration of the basement membrane, necrotic keratinocytes in the epidermis, exocytosis, and a predominantly perivascular, lymphocytic inflammatory dermal infiltrate with no spongiosis.

The suspected diagnosis was erythema multiforme contact dermatitis. Oral prednisone was prescribed, and the lesions improved gradually until they had completely resolved 2 weeks later leaving only scaling. A few hours after

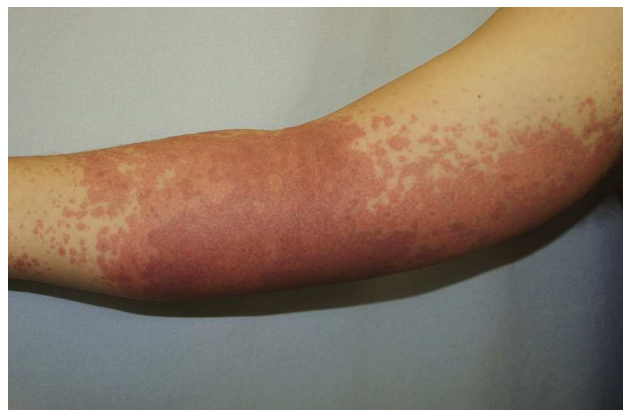

Figure 1 Targetoid erythematous macules on the forearm.

returning to work, he experienced a new outbreak, albeit of lesser intensity. The patient remains asymptomatic 7 months after being moved from his job.

Patch tests were performed using the standard series of the Spanish Contact Dermatitis and Skin Allergy Research Group (GEIDAC) and the Marti Tor meth(acrylate) series. Positive reactions were recorded for 2-hydroxyethyl methacrylate 1% petrolatum (pet), 2-hydroxyethyl acrylate 0.1% pet, 2-hydroxypropyl methacrylate 2% pet, ethyl acrylate 0.1% pet, and tetrahydrofurfuryl methacrylate 2% pet. No further positive reactions were recorded (Table 1). Although we did not have access to the ink that caused the initial reaction (SR238, Sartomer), the technical specifications of the product showed that it contained hexamethylene diacrylate. Therefore, diagnosis was confirmed as erythema multiforme contact dermatitis, probably caused by sensitization to hexamethylene diacrylate, with cross-reaction to other acrylates.

Erythema multiforme contact dermatitis is an uncommon condition that is caused by contact with vegetable allergens, metals, tropical woods, cosmetics, and chemicals.³ It is the most common noneczematous clinical presentation of allergic contact dermatitis. The initial lesions are eczematous in appearance and are found in the area of direct contact with the allergen. During the following days, targetoid

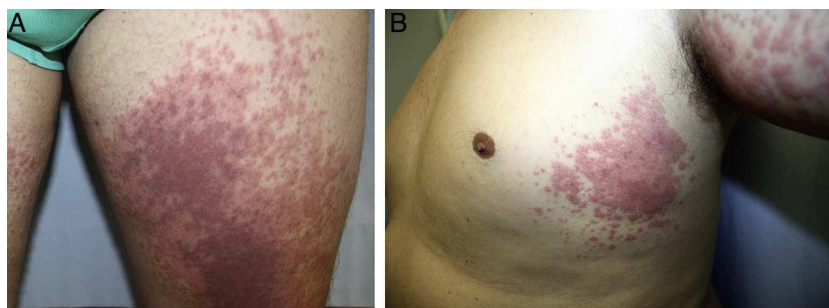


Figure 2 A and B, Similar lesions on both thighs and the trunk (areas not exposed to direct contact with ink).

[☆] Please cite this article as: Córdoba S, Puente N, Calderón A, Borbujo JM. Eritema multiforme de contacto tras exposición accidental a acrilatos en tintas de impresión. *Actas Dermosifiliogr.* 2015;106:684–685.

Table 1 Patch Test Results.

	48 h	96 h
GEIDAC ^a standard series	—	—
MartiTor (meth)acrylate series		
2-hydroxyethyl methacrylate 1% pet	—	+
2-hydroxyethyl acrylate 0.1% pet	++	++
2-hydroxypropyl methacrylate 2% pet	+	++
Bisphenol A methacrylate 2% pet	—	—
Butyl acrylate 0.1% pet	—	—
Ethylene glycol dimethacrylate 2% pet	—	—
Methyl methacrylate 2% pet	—	—
Triethylene glycol dimethacrylate 2% pet	—	—
Ethyl acrylate 0.1% pet	+	++
Ethyl cyanoacrylate 10% pet	—	—
Ethyl methacrylate 2% pet	—	—
Tetrahydrofurfuryl methacrylate 2% pet	+	+

Abbreviation: Pet, petrolatum.

^a Spanish Contact Dermatitis and Skin Allergy Research Group.

toid, erythematous-vesicular, or urticarial lesions appear on the periphery of and at a distance from the area of the original contact. Histopathology findings are nonspecific. Spongiosis and exocytosis are common findings, although vacuolar degeneration of the basement membrane or epidermal necrolysis is more unusual.³

Acrylate-induced allergic contact dermatitis usually manifests as eczematous dermatitis on the hands or fingertip dermatitis in patients who handle acrylates in the workplace.⁴⁻⁶ To date, only 1 case of acrylate-induced erythema multiforme contact dermatitis has been reported. The patient developed large blisters with skin detachment indicative of progress to toxic epidermal necrolysis.

We present a case of acrylate-induced allergic contact dermatitis after accidental workplace exposure to printing ink. The case is interesting because of the curious nature of the presentation. We wish to highlight the importance

of protective measures in industries where workers are required to handle acrylates. Workers should be aware that they are handling potent sensitizers that can lead to occupational disability.

Conflicts of Interest

The authors declare that they have no conflicts of interest.

References

1. Rycroft R. Occupational contact dermatitis. In: Rycroft R, Menné T, Frosch P, editors. *Textbook of contact dermatitis*. 2nd edn. Berlin: Springer-Verlag; 1999. p. 343–400.
2. Morgan VA, Fewings JM. 1,6-hexanediol diacrylate: A rapid and potent sensitizer in the printing industry. *Australas J Dermatol*. 2000;41:190–2.
3. Ido T, Kiyohara T, Takahashi H, Yamaguchi Y, Tani D, Kumakiri M. Toxic epidermal necrolysis following allergic contact dermatitis caused by occupational exposure to ultraviolet-cured inks. *Acta Derm Venereol*. 2012;92:313–5.
4. Pérez-Formoso JL, de Anca-Fernández J, Maraví-Cecilia R, Díaz-Torrez JM. Dermatitis de contacto a acrilatos en una industria de fabricación de ascensores. A propósito de 8 casos. *Actas Dermosifiliogr*. 2010;10:336–40.
5. Romaguera C, Vilaplana J, Llagostera M, Grimalt R. Dermatitis de contacto profesional por Threebond®. Cuatro casos en la misma empresa. *Actas Dermosifiliogr*. 2011;102:468–9.
6. Roche E, de la Cuadra J, Alegre V. Sensibilización a acrilatos por uñas artificiales. Revisión de 15 casos. *Actas Dermosifiliogr*. 2008;99:788–94.

S. Córdoba,* N. Puente, A. Calderón, J.M. Borbujo
Servicio de Dermatología, Hospital Universitario de Fuenlabrada, Madrid, Spain

*Corresponding author.

E-mail address: scordoba.hflr@salud.madrid.org (S. Córdoba).

Diffuse Systemic Large B-Cell Lymphoma With Secondary Skin Involvement[☆]



Linfoma B difuso de células grandes sistémico con afectación cutánea secundaria

To the Editor:

Diffuse large B-cell lymphoma (DLBCL) is the most common type of systemic lymphoma and accounts for 40% of all

new cases of this disease. Prognosis has improved considerably since the introduction of rituximab, which combined with chemotherapy is associated with a cure rate of up to 50%¹; R-CHOP is the regimen of choice. Secondary cutaneous involvement is uncommon in DLBCL, although it has been observed in up to 20% of cases in some series.²

We present the case of an 81-year-old man in good health who presented with an indurated, erythematous-violaceous plaque-like lesion with a diameter of 7 × 4 cm on the right leg (Fig. 1). The plaque had appeared 3 weeks earlier.

A biopsy was performed to investigate the suspected diagnosis of primary cutaneous lymphoma, with results showing a diffuse, dense infiltration of large, highly pleomorphic atypical basophilic cells in the dermis (Fig. 2). Immunohistochemical stains were positive for B-cell markers (CD20, CD79a), negative for T-cell markers (CD3, CD5), and strongly positive for Bcl-2. Less intense staining was observed for Bcl-6 and MUM-1, and the results were negative

[☆] Please cite this article as: Lloret-Ruiz C, Molés-Poveda P, Barrado-Solís N, Gimeno-Carpio E. Linfoma B difuso de células grandes sistémico con afectación cutánea secundaria. *Actas Dermosifiliogr*. 2015;106:685–687.