

of vascular origin. The most important differential diagnoses are angiosarcoma, which expresses endothelial markers such as CD31 and CD34, and chronic expansive hematoma, which presents as an encapsulated tumor filled with blood and neovasculature.

What was interesting about this case, apart from the rarity of the condition, was the ease with which a giant vascular eccrine spiradenoma could be mistaken for a lesion of vascular origin.

## References

1. Cotton DWK, Slater DN, Rooney N, Goepel JR, Mills PM. Giant vascular eccrine spiradenomas: A report of two cases with histology, immunohistology and electron microscopy. *Histopathology*. 1986;10:1093–9.
2. Hey A, Grouls V, Röckelein G. Vascular eccrine giant spiradenoma-A case report with histology and immunohistology of a rare variant of benign sweat gland tumors. *Z Hautkr*. 1988;3:444–7.
3. Senol M, Ozcan A, Sasmaz S, Ozen S, Ciralik H. Giant vascular eccrine spiradenoma. *Int J Dermatol*. 1998;37:221–3.
4. Ko JY, Lee CW, Moon SH, Song KW, Park CK. Giant eccrine spiradenoma: Report of a case with immunohistochemical study. *J Korean Med Sci*. 2006;21:172–6.
5. Yamakoshi T, Makino T, Watanabe H, Furuichi M, Matsui K, Shimizu T. A case of giant vascular eccrine spiradenoma with unusual clinical features. *Clin Exp Dermatol*. 2009;34:e250–1.
6. Kim MH, Cho E, Lee JD, Cho SH. Giant vascular eccrine spiradenoma. *Ann Dermatol*. 2011;19:197–200.
7. Tremezaygues LL, Pfohler C, Vogt T, Muller CS. Differential considerations of skin tumors with florid vascularisation: Report of a solitary giant vascular eccrine spiradenoma. *BMJ*. 2011, <http://dx.doi.org/10.1136/bcr.05.2011.4187>.
8. Hatano A, Kobayashi T, Fukuzumi S, Shirakashi Y, Nishimura C, Gomi H, et al. Giant vascular eccrine spiradenoma mimicking calcifying epithelioma. *J Dermatol*. 2013;40:853–4.
9. Nakamura Y, Teramoto Y, Yamada K, Yamamoto A. Giant vascular eccrine spiradenoma mimicking chronic expanding hematoma. *J Dtsch Dermatol Ges*. 2014;10:908–10.
10. Krishnan K, Thomas A. Giant vascular eccrine spiradenoma with unusual clinical presentation: A case report. *Open J Pathol*. 2014;4:21–4.

E. Jorquera Barquero,<sup>a,\*</sup> C. Lara Bohórquez,<sup>b</sup>  
I. de Alba Rioja<sup>a</sup>

<sup>a</sup> Servicio Dermatología M-Q y Venereología, Complejo hospitalario de Huelva, Huelva, Spain

<sup>b</sup> Servicio de Anatomía Patológica, Complejo hospitalario de Huelva, Huelva, Spain

\* Corresponding author.

E-mail address: [jorroc@aedv.es](mailto:jorroc@aedv.es) (E. Jorquera Barquero).

## Refractory Hailey-Hailey Disease That Responded Well to Photodynamic Therapy<sup>☆</sup>



### Enfermedad de Hailey-Hailey recalcitrante con buena respuesta a terapia fotodinámica

To the Editor:

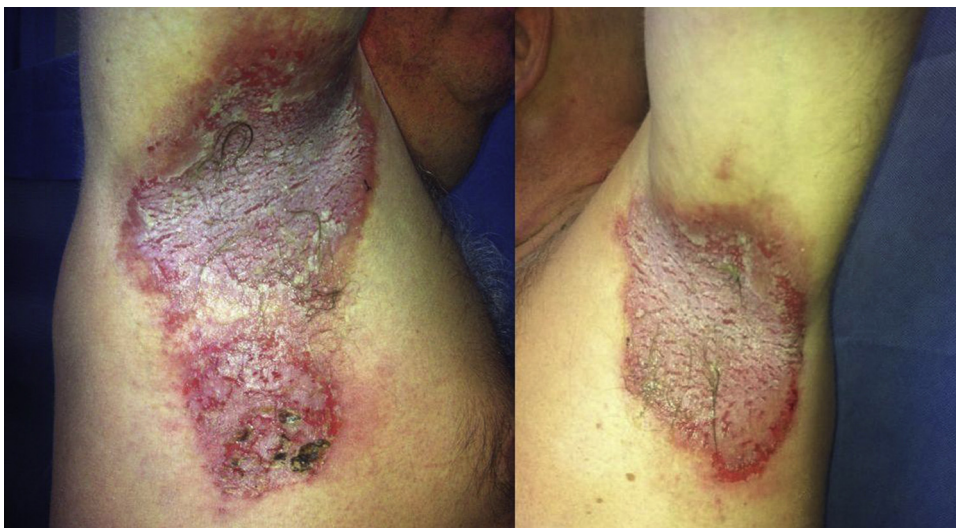Hailey-Hailey disease or familial benign pemphigus is a rare hereditary skin disease. This chronic and recurrent condition can cause severe discomfort and be difficult to control with conventional treatments. Photodynamic therapy (PDT) could offer an alternative in cases in which other treatment options have failed.

The patient was a 56-year-old male who for 30 years had experienced several outbreaks a year of stinging, itching, and burning lesions located on the neck and armpits. The lesions interfered with his daily activities and had a negative impact on his quality of life. Physical examination revealed bright, well-defined, highly exudative, eroded, and erythematous plaques with some surface crusts located in both armpits and on the lateral aspects of the neck (Fig. 1). Histological study of a biopsied sample from one of the lesions demonstrated an epidermis with erosions

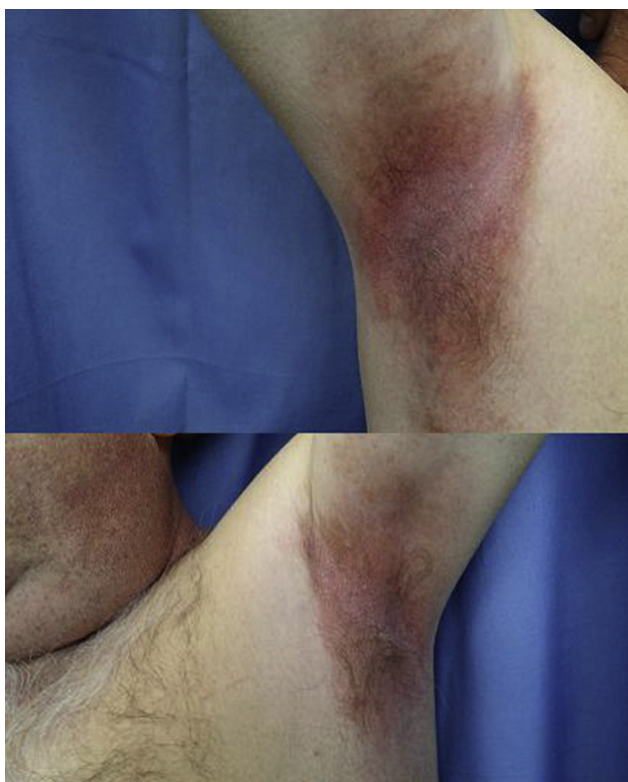
and intraepidermal blisters, marked acantholysis, and the typical appearance of a dilapidated brick wall. The patient had been diagnosed with Hailey-Hailey disease and had received multiple treatments with astringents such as copper and zinc sulfate (1:1000), topical and systemic steroids, topical vitamin D derivatives, topical tacrolimus, and acitretin. Response to treatment had always been partial with a disease-free interval between flares lasting only a few weeks. These shortcomings represented an important limitation for the patient. He agreed to undergo a single session of PDT to see what the response would be and to assess the tolerability of the treatment. First, both underarms were cleaned with physiological saline solution and methyl aminolevulinate (MAL) cream was applied under occlusion for 3 hours. The underarms were then irradiated with a red light (Aktilite at 37 J/cm<sup>2</sup>) for 7.5 minutes. During the period of exposure, the patient experienced a slight sensation of pain and burning, which was well tolerated. The response on follow-up at 2 weeks was excellent: the erosions had healed, the exudate and erythema had disappeared, and the patient reported an improvement in his quality of life (Fig. 2). Six months later, the patient is still free of lesions and has not undergone any other treatment.

Hailey-Hailey disease or familial benign pemphigus is an autosomal dominant genodermatosis caused by a mutation in the *ATP2C1* gene. It is characterized by the appearance of

<sup>☆</sup> Please cite this article as: Lobato-Berezo A, Imbernón-Moya A, Aguilar-Martínez A. Enfermedad de Hailey-Hailey recalcitrante con buena respuesta a terapia fotodinámica. *Actas Dermosifiliogr*. 2015;106:852–854.



**Figure 1** Erythematous, erosive, and highly exudative plaques with surface crusts in the axillas.



**Figure 2** Resolution of axillary lesions following a single photodynamic therapy session.

vesicles, blisters, and erosions in flexural areas, including the neck and axillas as well as the inframammary and inguinal folds. Typically, patients experience recurrent flares and, occasionally, spontaneous remission. Among the best known precipitating factors are exposure to UV light, sweat, friction, stress, skin infections, and pregnancy.<sup>1</sup>

Many treatments have been used to control the disease with varying results. Medical treatments include topical and

systemic corticosteroids, topical and systemic antibiotics, topical vitamin D analogs, topical 5-fluorouracil, dapsone, psoralen and UV-A light therapy, systemic retinoids, ciclosporin, methotrexate, and oral glycopyrrolate.<sup>2,3</sup> A number of invasive treatments have been attempted, including infiltration with botulinum toxin,<sup>4</sup> carbon dioxide laser,<sup>5,6</sup> erbium: yttrium aluminium garnet laser, and dermabrasion.

In the literature, we found only 2 articles (referring to 5 patients) on Hailey-Hailey disease treated with PDT (Table 1). The age of the 5 patients ranged from 28 to 51 years and all but one were women. The time elapsed since diagnosis ranged from 8 months to 24 years, and all 5 patients had undergone prior treatment with topical corticosteroids and a topical vitamin D analog or an antibiotic. Two of the patients had a complete response followed by a disease-free interval of 19 and 25 months, respectively; a further 2 patients showed partial improvement of their lesions, and the remaining patient did not improve.<sup>7,8</sup> In the cases reported by Ruiz-Rodríguez et al.<sup>7</sup> PDT was well tolerated because lidocaine 1% was administered in the treatment site as a local anesthetic. By contrast, the 3 patients reported by Fernández-Guarino et al.<sup>8</sup> experienced pain, erythema and/or edema during and after treatment and none of them wished to undergo another PDT session. Topical anesthetics could interfere with the effectiveness of PDT treatment because they have an alkaline pH that destabilizes the aminolevulinic acid.<sup>8</sup> It remains unclear why patients with Hailey-Hailey disease improve with PDT, but the good response is thought to be due to intracellular accumulation of protoporphyrin IX in epidermal keratinocytes, which interferes with structures such as mitochondria, lysosomes, and endoplasmic reticulum.<sup>7</sup>

Providing it is tolerated, PDT may represent an alternative treatment option in cases of Hailey-Hailey disease refractory to first-line therapies, since durable remissions can be achieved that can improve the patient's quality of life.

**Table 1** Cases of Hailey-Hailey Disease Treated with Photodynamic Therapy.

Reference	Age	Sex	Duration of Disease	Site Affected	Prior Treatments	Disease-Free Interval After PDT
Ruiz-Rodríguez et al., 2002 <sup>7</sup>	45	♀	4 y	Axillas, groin	Topical and systemic corticosteroids, topical and systemic antibiotics, dermabrasion	Complete response, 19 mo
	51	♀	24 y	Groin, vulva	Topical and systemic corticosteroids, topical and systemic antibiotics	Complete response, 25 mo
Fernández Guarino et al., 2008 <sup>8</sup>	45	♀	3 y	Axillas	Topical corticosteroids and vitamin D analogs	No response
	40	♂	2 y	Perianal	Corticosteroids, vitamin D analogs, topical immunomodulator	Partial response, 6 mo
	28	♀	8 mo	Vulva	Corticosteroids, vitamin D analogs, topical immunomodulator	Partial response
Lobato-Berezo, 2015	56	♂	30 y	Axillas, neck	Copper and zinc sulfate, topical and systemic corticosteroids, vitamin D analogs, topical tacrolimus, acitretin	Complete response, 6 mo

## References

- Mauzo SH, Sulit DJ. Hailey-Hailey disease exacerbated by multiple pregnancies: Case report and review of the literature. *Dermatol Online J.* 2014;20.
- Nanda KB, Saldanha CS, Jacintha M, Kamath G. Hailey-Hailey disease responding to thalidomide. *Indian J Dermatol.* 2014;59:190–2.
- Kaniszevska M, Rovner R, Arshanapalli A, Tung R. Oral glycopyrrolate for the treatment of Hailey-Hailey Disease. *JAMA Dermatol.* 2015.
- Ho D, Jagdeo J. Successful botulinum toxin (onabotulinum-toxina) treatment of Hailey-Hailey disease. *J Drugs Dermatol.* 2015;14:68–70.
- Campuzano-García AE, Torres-Alvarez B, Hernández-Blanco D, Castanedo-Cázares JP. Hailey-Hailey disease improved by fractional CO<sub>2</sub> laser. *J Cosmet Laser Ther.* 2015;13:1–3.
- Pretel-Irazabal M, Lera-Imbuluzqueta JM, España-Alonso A. Carbon dioxide laser treatment in Hailey-Hailey disease: A series of 8 patients. *Actas Dermosifiliogr.* 2013;104:325–33.
- Ruiz-Rodríguez R, Alvarez JG, Jaén P, Acevedo A, Córdoba S. Photodynamic therapy with 5-aminolevulinic acid for recalcitrant familial benign pemphigus (Hailey-Hailey disease). *J Am Acad Dermatol.* 2002;47:740–2.
- Fernández Guarino M, Ryan AM, Harto A, Pérez-García B, Arrázola JM, Jaén P. Experience with photodynamic therapy in Hailey-Hailey disease. *J Dermatolog Treat.* 2008;19:288–90.

A. Lobato-Berezo,\* A. Imbernón-Moya, A. Aguilar-Martínez

*Departamento de Dermatología, Hospital Universitario Severo Ochoa, Leganés, Madrid, Spain*

\* Corresponding author.

*E-mail address: allobe@hotmail.es (A. Lobato-Berezo).*

## Mast Cells and Scarring Alopecia: Is There a Clear Pathophysiological Relationship?☆



### Mastocitos y alopecia cicatricial: ¿hay una clara relación fisiopatológica?

*To the Editor:*

Frontal fibrosing alopecia is a subtype of scarring (or cicatricial) alopecia that is histologically characterized by the

presence of a predominant lymphocytic infiltrate.<sup>1</sup> The presence of unexpectedly large numbers of mast cells is a rare finding that has been reported only infrequently in the literature. A recent case described in our unit prompted us to reflect on the pathophysiological role of mast cells in frontal fibrosing alopecia and other varieties of the disorder.

A 48-year-old woman who experienced early menopause at age 42 years consulted for asymptomatic progressive alopecia. She had not undergone any previous treatment. Physical examination revealed recession of the frontal and temporal hairline (Fig. 1, A) with no desquamation, erythema, or perilesional hyperkeratosis (Fig. 1, B). There was no variation in the length or thickness of the hair shaft, nor was there any decrease in hair follicle density in the healthy area. The skin had a parchment-like appearance, and some intact hair follicles were present in the hair-loss band. Alopecia was noted in the distal third of the

☆ Please cite this article as: Almodovar-Real A, Diaz-Martinez MA, Ruiz-Villaverde R, Naranjo-Sintes R. Mastocitos y alopecia cicatricial: ¿hay una clara relación fisiopatológica?. *Actas Dermosifiliogr.* 2015;106:854–857.