

2. Lee HH, Song IH, Friedrich M, Gauliard A, Detert J, Röwert J, et al. Cutaneous side-effects in patients with rheumatic diseases during application of tumour necrosis factor-alpha-antagonists. *Br J Dermatol.* 2007;156:486–91.
  3. Roé E, Puig L, Corella F, García-Navarro X, Alomar A. Cutaneous adverse effects of biological therapies for psoriasis. *Eur J Dermatol.* 2008;18:693–9.
  4. Newell EL, Jain S, Stephens C, Martland G. Infliximab-induced pityriasis lichenoides chronica in a patient with psoriasis. *J Eur Acad Dermatol Venereol.* 2009;23:230–1.
  5. Said BB, Kanitakis J, Graber I, Nicolas JF, Saurin JC, Berard F. Pityriasis lichenoides chronica induced by adalimumab therapy for Crohn's disease: Report of 2 cases successfully treated with methotrexate. *Inflamm Bowel Dis.* 2009;16:912–3.
  6. López-Ferrer A, Puig L, Moreno G, Camps-Fresneda A, Palou J, Alomar A. Pityriasis lichenoides chronica induced by infliximab, with response to methotrexate. *Eur J Dermatol.* 2010;20:511–2.
  7. Echeverri AF, Vidal A, Cañas CA, Agualimpia A, Tobón GJ, Bonilla-Abadía F. Etanercept-induced pityriasis lichenoides chronica in a patient with rheumatoid arthritis. *Case Rep Dermatol Med.* 2015;2015:168063.
  8. Bowers S, Warshaw EM. Pityriasis lichenoides and its subtypes. *J Am Acad Dermatol.* 2006;55:557–72.
  9. Tsianakas A, Hoeger PH. Transition of pityriasis lichenoides et varioliformis acuta to febrile ulceronecrotic Mucha-Habermann disease is associated with elevated serum tumour necrosis factor-alpha. *Br J Dermatol.* 2005;152:794–9.
  10. Nikkels AF, Gillard P, Pierard GE. Etanercept in therapy multiresistant overlapping pityriasis lichenoides. *J Drugs Dermatol.* 2008;7:990–2.
  11. Navarro R, Daudén E. Reacciones psoriasiformes paradójicas durante el tratamiento con terapia anti-factor de necrosis tumoral. *Manejo clínico. Actas Dermosifiliogr.* 2014;105:752–61.
- C. Martínez-Peinado,<sup>a,\*</sup> M. Galán-Gutiérrez,<sup>a</sup>  
R. Ruiz-Villaverde,<sup>b</sup> R. Solorzano-Mariscal<sup>c</sup>
- <sup>a</sup> *Unidad de Gestión Clínica de CMA-Dermatología Médico Quirúrgica y Venereología, Complejo Hospitalario de Jaén, Jaén, Spain*  
<sup>b</sup> *Unidad de Gestión Clínica de Dermatología Médico Quirúrgica y Venereología, Hospital Universitario Virgen de las Nieves, Granada, Spain*  
<sup>c</sup> *Servicio de Anatomía Patológica, Complejo Hospitalario de Jaén, Jaén, Spain*
- \* Corresponding author.  
E-mail address: [carpeinado@hotmail.es](mailto:carpeinado@hotmail.es)  
(C. Martínez-Peinado).

## Erythema Multiforme Associated With Phenytoin and Cranial Radiation Therapy (EMPACT Syndrome) in a Patient With Lung Cancer<sup>☆</sup>



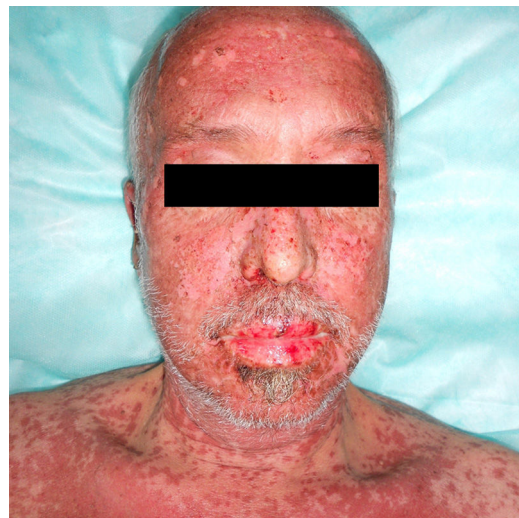
### Síndrome Erythema Multiforme associated with Phenytoin And Cranial radiation Therapy (EMPACT) en paciente con neoplasia pulmonar

To the Editor

Erythema multiforme associated with phenytoin and cranial radiation therapy (EMPACT syndrome) was first described by Ahmed et al.<sup>1</sup> in 2004 in a series of patients with dermatosis secondary to cranial radiation therapy and phenytoin treatment. Stevens-Johnson syndrome (SJS) and toxic epidermal necrolysis (TEN) are acute bullous dermatoses caused mainly by the use of drugs such as phenytoin.

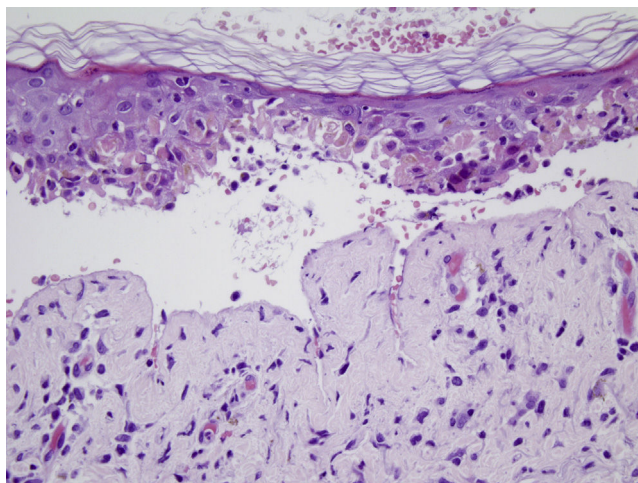
A 54-year-old man diagnosed with pulmonary adenocarcinoma (T3-4N2M1) with a single intracranial metastasis underwent cranial radiation therapy with a total dose of 30 Gy (fractional dose = 300 cGy). The radiation therapy was completed 1 week before the onset of the skin condition. The patient had been receiving phenytoin as a prophylactic anticonvulsant and oral dexamethasone for

5 weeks. Physical examination revealed small, atypical, target-shaped, erythematous-edematous lesions with a tendency to coalesce on the face, neck, trunk, and root of the upper limbs, occupying 35% of the body, with skin detachment in the affected areas. Marked conjunctival injection and intense involvement of the oral mucosa, with labial edema and erosive lesions, were also present (Fig. 1). Biopsy of a lesion in the supraclavicular region revealed an intense interface lesion in both the epidermis and the follicular epithelium, with abundant necrotic keratinocytes (isolated or in groups), a moderate lymphocytic inflammatory response, and areas of epidermal detachment with



**Figure 1** Erythematous-edematous plaques with areas of skin detachment and erosive semimucosal lesions on the lips.

<sup>☆</sup> Please cite this article as: Vilas-Sueiro A, Vázquez-Osorio I, Suárez-Peñaranda JM, Sánchez-Aguilar D. Síndrome Erythema Multiforme associated with Phenytoin And Cranial radiation Therapy (EMPACT) en paciente con neoplasia pulmonar. *Actas Dermosifiliogr.* 2016;107:169–170.



**Figure 2** Skin detachment and epidermal necrosis with dyskeratotic keratinocytes and lymphocytic inflammatory infiltrate (hematoxylin-eosin, original magnification  $\times 10$ ).

partial necrosis of the detached epidermis (Fig. 2). As therapeutic management, treatment with phenytoin was suspended and substituted by levetiracetam, and adjuvant therapy was also started. The lesions responded well, remaining stable in relation to the neoplastic disease.

Prophylactic use of anticonvulsants is routine in patients who undergo cranial radiation therapy. As in the case of our patient, phenytoin is usually the drug of choice, although other drugs, such as carbamazepine, levetiracetam, and lamotrigine are occasionally used.

Although skin reactions occur after ingestion of phenytoin in 19% of cases, severe cutaneous manifestations such as SJS and TEN are rare.<sup>1,2</sup> Although these conditions are unusual, it is very important that they be taken into account in order to avoid potentially life-threatening complications.

In recent years, the association of cranial radiation therapy and phenytoin has been shown to increase the risk of skin lesions known as the EMPACT syndrome.<sup>3</sup> However, severe SJS-type or TEN-type cutaneous-mucosal manifestations, such as those seen in our patient, only occur in a small percentage of cases and can be life-threatening.<sup>4</sup> This complication presents as erythematous-edematous macules and papules that are initially limited to the irradiated area, later progressing to epidermal detachment in larger areas (Nikolsky sign) with considerable involvement of the oral and ocular mucosae.<sup>5</sup> In our patient, oral mucosal involvement was the first manifestation—an indication of the variability of the first manifestations.

The pathogenesis is unknown, although it has been suggested that radiation therapy could induce a deficit of epoxide hydroxylase, an enzyme responsible for eliminating toxic metabolites of phenytoin.<sup>6</sup> More controversial is the possibility of a type IV hypersensitivity reaction to phenytoin

and its metabolites, exacerbated by the action of the radiation therapy and the deficient metabolism of the toxic products of the drug.<sup>5,7</sup>

The use of levetiracetam or gabapentin as alternative drugs—either initially or as a substitute for phenytoin—should therefore be considered because the degradation of these drugs does not take place via the same metabolic pathway.

In conclusion, we present a case of the EMPACT syndrome with unusually severe cutaneous and mucosal involvement. Prophylactic use of anticonvulsants should be considered on a case-by-case basis. If anticonvulsant use is essential, the appearance of cutaneous-mucosal lesions should be monitored closely and the drug should be suspended when the first suspicious symptom appears.

## References

- Ahmed I, Reichenberg J, Lucas A, Shehan JM. Erythema multiforme associated with phenytoin and cranial radiation therapy: A report of three patients and review of the literature. *Int J Dermatol.* 2004;43:67–73.
- Ridgway HB, Miech DJ. Erythema multiforme (Stevens-Johnson syndrome) following deep radiation therapy. *Cutis.* 1993;51:463–4.
- Bilgili SG, Calka O, Karadag AS, Burakgazi AZ. EMPACT syndrome. *Cutan Ocul Toxicol.* 2011;30:328–30.
- Fidan E, Fidan M, Ozdemir F, Kavgaci H, Aydin F. Phenytoin- and cranial radiotherapy-induced toxic epidermal necrolysis treated with combination therapy: Systemic steroid and intravenous immunoglobulin. *Med Oncol.* 2012;29:686–9.
- Vern-Gross TZ, Kowal-Vern A. Erythema multiforme, Stevens Johnson syndrome, and toxic epidermal necrolysis syndrome in patients undergoing radiation therapy: A literature review. *Am J Clin Oncol.* 2014;37:506–13.
- Fernández FA, Pintor E, Quesada R, Garcés FJ. Toxic epidermal necrolysis induced by phenytoin and whole brain radiotherapy [Article in Spanish]. *Actas Dermosifiliogr.* 2007;98:483–5.
- Ahmed I, Biswas A, Krishnamurthy S, Julka PK. Toxic epidermal necrolysis in a patient receiving concurrent phenytoin and whole brain and thoracic radiotherapy. *Saudi Med J.* 2014;35:1393–5.

A. Vilas-Sueiro,<sup>a,\*</sup> I. Vázquez-Osorio,<sup>b</sup>  
J.M. Suárez-Peñaranda,<sup>c</sup> D. Sánchez-Aguilar<sup>b</sup>

<sup>a</sup> *Servicio de Dermatología, Complejo Hospitalario Universitario de Ferrol, Ferrol, La Coruña, Spain*

<sup>b</sup> *Servicio de Dermatología, Complejo Hospitalario Universitario de Santiago, Santiago de Compostela, La Coruña, Spain*

<sup>c</sup> *Servicio de Anatomía Patológica, Complejo Hospitalario Universitario de Santiago, Santiago de Compostela, La Coruña, Spain*

\* Corresponding author.

E-mail address: [avilassueiro@gmail.com](mailto:avilassueiro@gmail.com) (A. Vilas-Sueiro).