

- Dermoscopic features.
- Photographs of the lesions prior to the surgical excision of suspicious skin lesions (essential).

In conclusion, the objective of this article has been to present the guideline used in our center for the initial clinical evaluation of nevi or suspected melanoma in the hope that it will help dermatologists evaluating patients with such lesions. Finally, it is essential that we undertake patient education regarding periodic self-examination, the clinical characteristics of melanoma (ABCDE rule and ugly duckling sign), and appropriate measures of photoprotection.^{1-3,10}

References

1. Mayer JE, Swetter SM, Fu T, Geller AC. Screening, early detection, education, and trends for melanoma: Current status (2007-2013) and future directions: Part I. Epidemiology, high-risk groups, clinical strategies, and diagnostic technology. *J Am Acad Dermatol*. 2014;71, 599.e1-599.e12.
2. Ballester I, Oliver V, Bañuls J, Moragón M, Valcuende F, Botella-Estrada R, et al. Multicenter case-control study of risk factors for cutaneous melanoma in Valencia, Spain. *Actas Dermosifiliogr*. 2012;103:790-7.
3. Paek SC, Sober AJ, Tsao H, Mihm MCJr, Johnson TM. Cutaneous Melanoma. In: Wolff K, Goldsmith LA, Katz SI, Gilchrist BA, Paller AS, Leffell DJ, editors. *Fitzpatrick's Dermatology in General Medicine*. 7.ª ed. McGraw-Hill; 2008. p. 1134-43.
4. Australian Cancer Network and New Zealand Guidelines Group. Clinical practice guidelines for the management of melanoma in Australia and New Zealand.
5. National Comprehensive Cancer Network. NCCN Clinical Practice Guidelines in Oncology (NCCN Guidelines).
6. Garbe C, Peris K, Hauschild A, Saiag P, Middleton M, Spatz A, et al. Diagnosis and treatment of melanoma. European consensus-based interdisciplinary guideline. Update 2012. *Eur J Cancer*. 2012;48:2375-90.
7. Dummer R, Hauschild A, Guggenheim M, Keilholz U, Pentheroudakis G. Cutaneous melanoma: ESMO Clinical Practice Guidelines for diagnosis, treatment and follow-up. *Ann Oncol*. 2012;23:86-91.
8. Pflugfelder A, Kochs C, Blum A, Capellaro M, Czeschik C, Dettenborn T, et al., German Dermatological Society; Dermatologic Cooperative Oncology Group. Malignant melanoma S3-guideline "diagnosis, therapy and follow-up of melanoma" [Article in English, German]. *J Dtsch Dermatol Ges*. 2013;11 Suppl 6:S1-116.
9. Bichakjian CK, Halpern AC, Johnson TM, Foote Hood A, Grichnik JM, Swetter SM, et al., American Academy of Dermatology. Guidelines of care for the management of primary cutaneous melanoma. American Academy of Dermatology. *J Am Acad Dermatol*. 2011;65:1032-47.
10. Mangas C, Paradelo C, Puig S, Gallardo F, Marcoval J, Azon A, et al. Initial evaluation, diagnosis, staging, treatment, and follow-up of patients with primary cutaneous malignant melanoma. Consensus statement of the Network of Catalan and Balearic Melanoma Centers [Article in Spanish]. *Actas Dermosifiliogr*. 2010;101:129-42.

A. Imbernón-Moya,^{a,*} S. Podlipnik,^b J. Malveyh,^b S. Puig^b

^a *Servicio de Dermatología, Hospital Severo Ochoa, Leganés, Madrid, Spain*

^b *Servicio de Dermatología, Hospital Clínic de Barcelona, Barcelona, Spain*

* Corresponding author.

E-mail address: adrian_imber88@hotmail.com

(A. Imbernón-Moya).

Bednar Tumor (Pigmented Dermatofibrosarcoma Protuberans)[☆]



Tumor de Bednar (dermatofibrosarcoma protuberans pigmentado)

To the Editor:

Dermatofibrosarcoma protuberans (DFSP) is a dermal connective tissue tumor with low malignancy due to its slow growth and locally aggressive nature. It can be classified into several variants according to morphologic features, although there are no major differences in terms of prognosis. The pigmented variant of DFSP, also known as Bednar tumor,^{1,2} is rare and is characterized by the presence of fibroblasts interlaced with melanin-containing dendritic cells. As with other variants of DFSP, fibrosarcomatous changes may occur; these are characterized by CD34 negativity, scarce melanin pigmentation, and increased cell prolifer-

ation and pleomorphism.^{3,4} This transformation tends to occur in recurrent DFSP and is associated with poor prognosis and an increased risk of metastasis, although the real risk is low.

The identification of the translocation t(17;22)(q22;q13) and the detection of the COL1A1-PDGFB fusion protein in DFSP led to the synthesis of tyrosine kinase inhibitors, such as imatinib as an alternative treatment for unresectable locally advanced disease or metastatic disease⁵ and sunitinib for nonresponders to imatinib.⁶

We report the case of a 93-year-old man with a pigmented stain, part of which contained a firm nodular lesion of 1.5 cm, located in the left preauricular region (Fig. 1). On observing that the lesion had grown, and based on a clinical suspicion of melanoma on lentigo maligna, the decision was taken to completely excise it. The histopathologic study showed focal atrophy of the epidermis, without ulceration, and a dense proliferation of monomorphic spindle cells with variable pleomorphism throughout the dermis and extending into the subcutaneous tissue (Fig. 2). The spindle cells presented areas with a histiocytic/xanthomatous appearance, abundant melanic pigmentation, and isolated mitotic figures (Fig. 3A). In the immunohistochemical study, the tumor cells showed diffuse positive staining for vimentin, focal staining for CD34 and CD68, and negative staining for

[☆] Please cite this article as: Añón-Requena MJ, Pico-Valimaña M, Muñoz-Arias G. Tumor de Bednar (dermatofibrosarcoma protuberans pigmentado). *Actas Dermosifiliogr*. 2016;107:618-620.

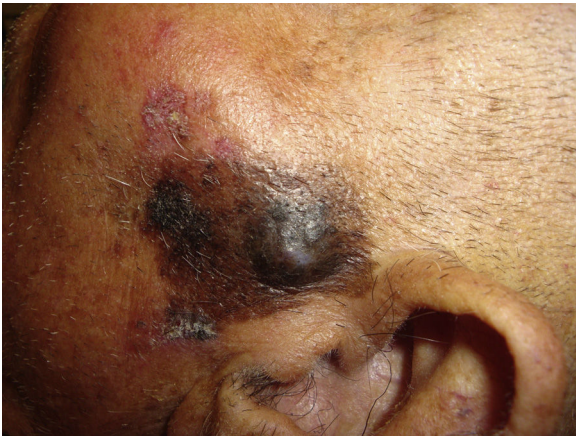


Figure 1 Clinical image: pigmented nodular skin lesion in the left preauricular region.

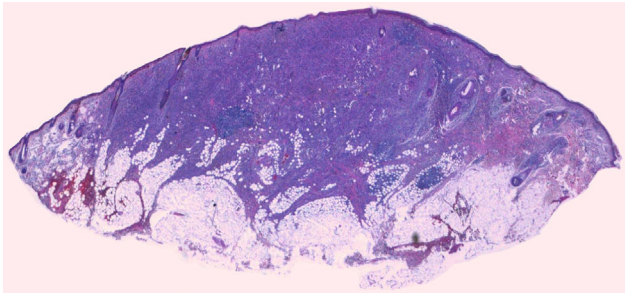


Figure 2 Histopathology: panoramic view of dermal tumor invading the subcutaneous tissue (hematoxylin-eosin, original magnification $\times 10$).

pan cytokeratin, actin, desmin, S100 protein, Melan-A, and HMB-45. Positive staining for S100 protein, corresponding to the dendritic cell component, was also observed in dispersed cells (Fig. 3B). Based on the above results, a diagnosis of pigmented DFSP (Bednar tumor) was established.

Pigmented DFSP was described in 1957 by Bednar⁷ under the name of storiform neurofibroma, but it is currently considered to be a pigmented variant of DFSP with distinctive dendritic cells and melanin pigmentation. Its histogenesis is unclear, and it remains to be elucidated whether it is derived from an undifferentiated mesenchymal cell with the capacity to differentiate itself into a fibroblast or a histiocyte or whether, considering the presence of dendritic cells, it has a neuroectodermal origin. On occasions, onset seems to be associated with local trauma such as burns, vaccine scars, or insect bites.⁸ The differential diagnosis includes pigmented neurofibroma, cutaneous leiomyosarcoma, spindle cell squamous cell carcinoma, spindle cell melanoma, and atypical fibroxanthoma, among others. Immunohistochemistry and special techniques are essential for differentiating between these entities. The first step is to distinguish between pigmented dendritic cells (which appear brown under typical hematoxylin-eosin staining) and hemosiderin-containing macrophages. Perls stain stains the iron present in blood blue, permitting the identification of hemosiderin secondary to old bleeding. Once hemosiderin-containing macrophages have been ruled out, spindle cell proliferations with dispersed pigmented cells must be investigated by immunohistochemistry. Diffuse expression of vimentin and focal positivity for S100 protein are consistent with pigmented neurofibroma; positive staining for actin and desmin indicate a possible diagnosis of leiomyosarcoma; cytokeratin positivity suggests squamous cell carcinoma; and the expression of S100, Melan-A, and HMB-45 would indicate a possible diagnosis of melanoma. Atypical fibroxanthoma is

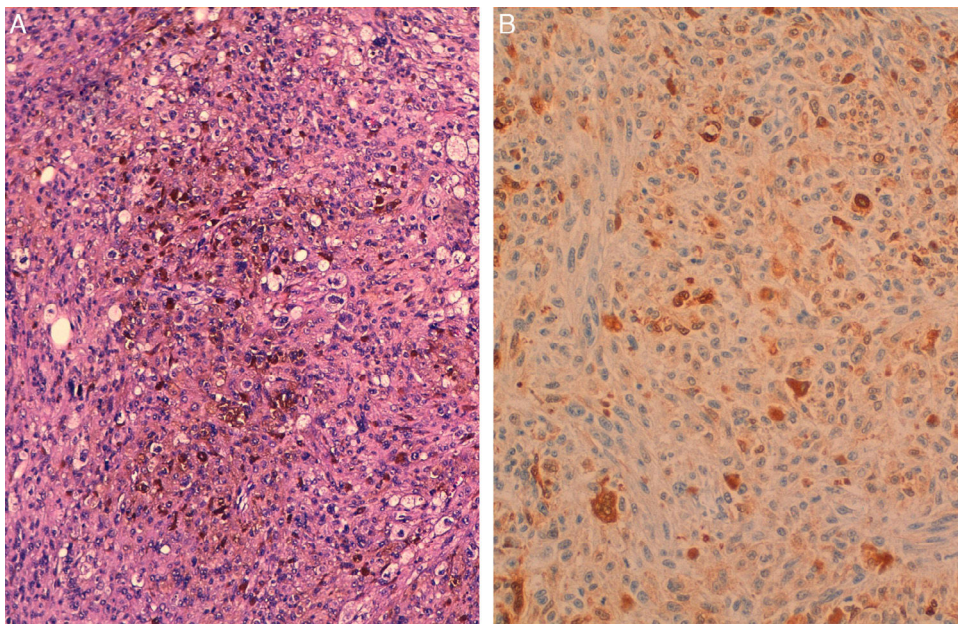


Figure 3 Histopathology: A, Proliferation of spindle cells and melanin-containing dendritic cells (hematoxylin-eosin, original magnification $\times 100$). B, Melanin-containing dendritic cells and positive staining for S100 protein (S100, original magnification $\times 200$).

contemplated when negative results are obtained for the above markers and the other entities in the differential diagnosis have been ruled out, although this tumor typically presents xanthomatous cells with vesicular nuclei and it may express CD10. When Bednar tumor is diagnosed, it is important to remember that these tumors are locally aggressive and invasive and tend to recur locally, but metastasis is rare and delayed. In conclusion, histopathology combined with immunohistochemistry or molecular biology is essential for the correct diagnosis and treatment of Bednar tumor.

Conflicts of Interest

The authors declare that they have no conflicts of interest.

References

1. Dupree WB, Langloss JM, Weiss SW. Pigmented dermatofibrosarcoma protuberans (Bednar tumor): A pathologic, ultrastructural, and immunohistochemical study. *Am J Surg Pathol.* 1985;9:630–9.
2. Yagi Y, Ueda K, Maruyama S, Noborio R. Bednar tumor: A Report of two cases. *J Dermatol.* 2004;31:484–7.
3. Suehara Y, Yazawa Y, Hitachi K. Metastatic Bednar tumor (pigmented dermatofibrosarcoma protuberans) with fibrosarcomatous change: A case report. *J Orthop Sci.* 2004;9:662–5.
4. McAllister J, Recht B, Hoffman T, Uma S. CD34+ pigmented fibrous proliferations: The morphologic overlap between pigmented dermatofibromas and Bednar tumors. *Am J Dermatopathol.* 2008;30:484–7.
5. Llombart B, Sanmartín O, López-Guerrero JA, Monteagudo C, Serra C, Requena C, et al. Dermatofibrosarcoma protuberans: Clinical, pathological, and genetic (COL1A1-PDGFB) study with therapeutic implications. *Histopathology.* 2009;54:860–72.
6. Fu Y, Kang H, Zhao H, Hu J, Zhang H, Li X, et al. Sunitinib for patients with locally advanced or distantly metastatic dermatofibrosarcoma protuberans but resistant to imatinib. *Int J Clin Exp Med.* 2015;8:8288–94.
7. Bednar B. Storiform neurofibromas of the skin, pigmented and nonpigmented. *Cancer.* 1957;10:368–76.
8. Morais P, Schettini A, Chirano C, Nakamura G. Bednar tumor (pigmented dermatofibrosarcoma protuberans): A case report. *An Bras Dermatol.* 2005;80:273–6.

M.J. Añón-Requena,^{a,*} M. Pico-Valimaña,^b
G. Muñoz-Arias^a

^a *Unidad de Gestión Clínica, Intercentros de Anatomía Patológica Bahía de Cádiz, Hospital Universitario Puerto Real, Cádiz, Spain*

^b *Sección de Dermatología, Unidad de Gestión Clínica Bloque Quirúrgico, Hospital Universitario Puerto Real, Cádiz, Spain*

* Corresponding author.

E-mail address: mjareq@gmail.com (M.J. Añón-Requena).

Localized Lipoatrophy in a Boy After an Intramuscular Injection of Penicillin[☆]



Lipoatrofia localizada en un niño tras administración de penicilina intramuscular

To the Editor:

Localized lipoatrophy is characterized by the loss of subcutaneous fat in a particular area of the body. In children, the condition is mainly related to subcutaneous or intramuscular injections of drugs or vaccines. Localized lipoatrophy is usually diagnosed clinically, although histopathologic examination can be necessary in some cases to rule out other causes such as connective tissue diseases and neoplasms.

We present the case of a healthy 8-year-old boy who was referred to our dermatology department for assessment of an asymptomatic lesion on his left thigh that had appeared 4 years earlier. A few weeks before the lesion appeared, the patient was diagnosed with streptococcal pharyngoamygdalitis and received treatment with an intramuscular injection of benzathine penicillin (600 000 IU) on the lateral aspect of the left thigh. The lesion grew in

proportion to the boy as he grew taller and gained weight. The boy had no personal or family history of autoimmune disease or history of trauma at the site of the lesion.

Physical examination revealed a 9 × 7 cm depressed plaque of similar color to the adjacent skin on the anterolateral aspect of the left thigh. The lesion was covered with normal skin (Fig. 1). No similar lesions were detected at other sites. No loss of strength or sensitivity was observed in the lower left limb.

Blood tests were carried out, including complete blood count, kidney and liver function, cholesterol, triglycerides, lipase, complement, rheumatoid factor, antistreptolysin O, and antinuclear antibodies. No significant abnormalities were found. The patient tested negative for *Borrelia burgdorferi*.

Ultrasound examination of the lesion revealed a complete loss of subcutaneous tissue alongside adjacent healthy skin. No muscular abnormalities were observed (Fig. 2). The parents declined to allow a biopsy of the lesion.

Treatment with medium-strength topical corticosteroids and topical calcineurin inhibitors was started. No improvement was seen after 2 months of treatment. The lesion has remained stable for 2 years of follow-up and no similar lesions have appeared at other sites.

Localized lipoatrophy can be classified as primary (or idiopathic) or as secondary to minor repetitive trauma injuries, injections of various drugs (penicillin, amikacin, methotrexate, corticosteroids, insulin)^{1–5} and vaccines,⁶ connective tissue diseases (lupus erythematosus, morphea, dermatomyositis), or malignant neoplasms.

[☆] Please cite this article as: Vázquez-Osorio I, Rodríguez-Vidal A, Rosón E, Alonso-González J, Vázquez-Veiga H. Lipoatrofia localizada en un niño tras administración de penicilina intramuscular. *Actas Dermosifiliogr.* 2016;107:620–622.