

The considerable stability of gold means that it is difficult to find it in its ionic form at concentrations sufficiently high to cause reactions, although concentrations may be sufficiently high to cause sensitization.⁹

References

1. Chen J, Lampel H. Gold contact allergy. *Dermatitis*. 2015;26:69–77.
2. Boonchai W, Iamtharachai P. Risk factors for common contact allergens and patch test results using a modified European baseline series in patients tested during between 2000 and 2009 at Siriraj Hospital. *Asian Pac J Allergy Immunol*. 2013;32:60–5.
3. Mehta V, Balachandran C. Persistent nodular contact dermatitis to gold: Case report of two cases. *Indian J Dermatol Venereol Leprol*. 2010;76:397.
4. Möller H. Contact allergy to gold as a model for clinical-experimental research. *Contact Dermatitis*. 2010;62:193–200.
5. Thyssen J, Menné T. Metal allergy-A review on exposures, penetration, genetics, prevalence, and clinical implications. *Chem Res Toxicol*. 2010;23:309–18.
6. Andersen K, Jensen C. Long-lasting patch reactions to gold sodium thiosulfate occurs frequently in healthy volunteers. *Contact Dermatitis*. 2007;56:214–7.
7. Lee A, Eun H, Kim H, Moon K, Lee C, Kim G, et al. Multicenter study of the frequency of contact allergy to gold. *Contact Dermatitis*. 2001;45:214–6.
8. Fowler J. Gold allergy in North America. *Am J Contact Dermat*. 2001;12:3–5.
9. Bruze M, Conde-Salazar L, Goossens A, Kanerva L, White I. Thoughts on sensitizers in a standard patch test series. *Contact Dermatitis*. 1999;41:241–50.

M. Arteaga-Henríquez,* I. Latour-Álvarez, E. García-Peris, N. Pérez-Robayna

Servicio de Dermatología, Hospital Universitario de Canarias, San Cristóbal de La Laguna, Tenerife, España

*Corresponding author.

E-mail address: mariaarteagah@gmail.com

(M. Arteaga-Henríquez).

1578-2190/

© 2016 Elsevier España, S.L.U. and AEDV. All rights reserved.

Isotretinoin-Induced Elkonyxis[☆]



Elconixis por isotretinoína

To the Editor:

Elkonyxis is a change in the nails characterized by marked fragility of the dorsal nail plate, irregular defects, loss of substance, or depressions that are larger than the pitting typical of psoriasis.^{1–3} The clinical appearance thus varies from an irregular roughness of the nail plate to perforation. Elkonyxis has only rarely been described in the medical literature. We present a case of elkonyxis secondary to treatment with isotretinoin.

The patient was a 17-year-old male with no past personal or family history of interest. He had moderate inflammatory acne that had recurred after several cycles of treatment with minocycline and he was therefore started on treatment with isotretinoin at a dose of 40 mg/d. The clinical course was unremarkable, with progressive improvement in his acne, minimal xerotic changes in the skin, and mild cheilitis. Laboratory tests showed no relevant alterations. During the third month of follow-up, the patient asked us to look at what he considered to be fragile nails, which he had first noticed a month after starting treatment. He denied trauma, manual labor, concurrent pathologic disorders, or other drugs. He also denied any previous nail changes or any past personal or familial history of psoriasis.

On inspection, the nail plates of all the fingernails presented various degrees of deformity, with irregular depressions, a rough surface, and brittleness (Figures 1 and 2). Some pitting, leukonychia, and oil spots were also visible. Mild desquamating periungual hyperkeratosis was observed and there was partial loss of the cuticle of the first nail of the right hand. No changes were observed in the toenails. The patient was offered the possibility of isotretinoin dose reduction or withdrawal, but he declined. Treatment was completed successfully and 4 months later the nails had recovered a normal appearance.

Elkonyxis is a rare nail disorder that has been reported in association with diseases such as peritonitis,⁴ psoriasis, syphilis, and reactive arthritis, or induced by trauma^{2,3} or by retinoids.^{1,5} The etiology and pathogenesis are unclear, but alterations of keratinization of inflammatory, traumatic, or pharmacological origin have been proposed. These changes occur in the nail matrix or in the proximal nail fold, giving

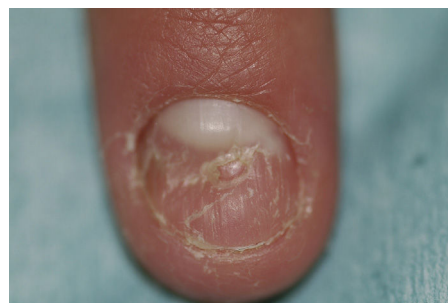


Figure 1 Brittle appearance of the nail of the left index finger, with a central depression larger than that seen in pitting.

[☆] Please cite this article as: Allegue F, González-Vilas D, Zulaica A. Elkonyxis por isotretinoína. *Actas Dermosifiliogr*. 2017;108:166–167.

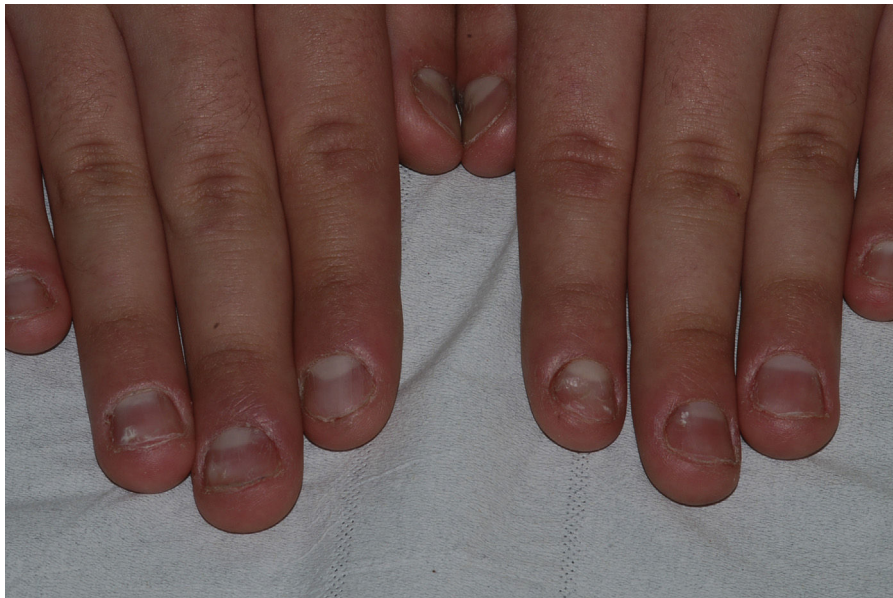

Figure 2 Rough and brittle surface of all the nail plates, although less evident in the fifth fingers. Oil spots and pinpoint leukonychia are visible.

rise to irregularities in the nail plate.³ The few histopathological studies reported show inflammation and granulation tissue.^{2,3}

Elkonyxis affects the proximal dorsal nail plate, over the lunula, and advances distally as the nail grows. The width and depth of the defect are directly proportional to the extent of damage to the matrix.² It is not rare to find other associated nail abnormalities, such as leukonychia,⁴ median canaliform dystrophy,⁵ or washboard nail.²

Isotretinoin is a retinoid whose therapeutic effects and undesirable cutaneous, mucosal and adnexal side effects go hand in hand and are related to the drug's action on keratinization. Our patient had no previous nail or periungual changes. The alterations appeared during treatment and disappeared after its completion. In view of the chronologic correlation, the causative role of isotretinoin would appear clear, though obviously, given the nature of the treatment, we did not attempt reintroduction. Previous reports of the association between this nail disorder and isotretinoin and another retinoid, etretinate,^{1,5} support this hypothesis, although we cannot exclude a chance association because isotretinoin is a very widely used drug and only very few cases have been published. As with other side effects of the retinoids, elkonyxis is a dose-dependent effect.¹

In contrast to the case published by Yung et al.,¹ in which loss of the cuticles was reported, in our patient only partial loss of the cuticle of the right thumbnail was observed. Cuticle loss was also absent in other reports of elkonyxis secondary to trauma.

We have presented a case of elkonyxis occurring as a side effect of treatment with isotretinoin, and draw attention to this rare nail alteration, as few descriptions of this condition have been published.

References

1. Yung A, Johnson P, Goodfield MJ. Isotretinoin-induced elkonyxis. *Br J Dermatol.* 2005;153:671–2.
2. Lee YB, Cheon MS, Eun YS, Park HJ, Cho BK. Elkonyxis in association with washboard nail and 20-nail dystrophy. *Int J Dermatol.* 2014;53:e11–3.
3. Kim M, Jung HY, Kang JH, Cho BK, Park HJ. Elkonyxis associated with habit-tic deformity: Two case reports. *J Dermatol.* 2014;41:772–3.
4. Caputo R, Gelmetti C, Cambiaghi S. Severe self-healing nail dystrophy in a patient on peritoneal dialysis. *Dermatology.* 1997;195:274–5.
5. Alli N, Dogan S. Short-term isotretinoin-induced elkonyxis and median nail dystrophy. *Cutan Ocul Toxicol.* 2016;35:85–6.

F. Allegue,* D. González-Vilas, A. Zulaica

Servicio de Dermatología, Hospital do Meixoeiro EOXI, Vigo, Pontevedra, Spain

*Corresponding author.

E-mail addresses: fallegue@mundo-r.com, francisco.allegue.rodriguez@sergas.es (F. Allegue).

1578-2190/

© 2016 Elsevier España, S.L.U. and AEDV. All rights reserved.