

## References

- Leitenberger JJ, Cayce RL, Haley RW, Adams-Huet B, Bergstresser PR, Jacobe HT. Distinct autoimmune syndromes in morphea: A review of 245 adult and pediatric cases. *Arch Dermatol*. 2009;145:545–50.
- Burns DA, Sarkany I. Generalized morphea with bullous lesions and psoriasis. *Br J Dermatol*. 1976;95 Suppl 14:33–4.
- Bilen N, Apaydin R, Erçin C, Harova G, Ba F, Bayramgiirler D. Coexistence of morphea and psoriasis responding to acitretin treatment. *J Eur Acad Dermatol Venereol*. 1999;13:113–7.
- Saleh Z, Arayssi T, Saleh Z, Ghosn S. Superficial morphea: 20-year follow-up in a patient with concomitant psoriasis vulgaris. *J Cutan Pathol*. 2009;36:1105–8.
- Walls AC, Qureshi AA. Psoriasis and concomitant fibrosing disorders: Lichen sclerosis, morphea, and systemic sclerosis. *J Am Acad Dermatol*. 2010;67:1079–83.
- Stewart FA, Gavino AC, Elewski BE. New side effect of TNF-alpha inhibitors: Morphea. *Skinmed*. 2013;11:59–60.
- Shevliakov LV, Koncha AI. Combination of focal scleroderma and psoriasis. *Vestn Dermatol Venerol*. 1987;7:70 [Article in Russian].
- Aounallah A, Zaraq I, El Euch D, Chelly I, Haouet S, Mokni M, et al. Lipomembranous panniculitis associated with venous insufficiency, morphea, and psoriasis. *Skinmed*. 2016;14:127–9, eCollection 2016.
- Cuesta-Montero L, Belinchón I. Conectivopatías y psoriasis. *Actas Dermosifiliogr*. 2011;102:487–97.
- Akdis M, Palomares O, van de Veen W, van Splunter M, Akdis CA. Th17 and Th22 cells: A confusion of antimicrobial response with tissue inflammation versus protection. *J Allergy Clin Immunol*. 2012;129:1438–49.
- Bezalel SA, Strober BE, Ferenczi K. Interferon beta-1a-induced morphea. *JAAD Case Rep*. 2015;1:15–7.

O. Corral Magaña, J. Escalas Taberner,\*  
M.M. Escudero Góngora, A. Giacaman Contreras  
*Servicio de Dermatología, Hospital Universitario Son Espases, Palma de Mallorca, Islas Baleares, Spain*

\* Corresponding author.

E-mail address: [jetpalma@hotmail.com](mailto:jetpalma@hotmail.com)

(J. Escalas Taberner).

1578-2190/

© 2016 Elsevier España, S.L.U. and AEDV. All rights reserved.

## Chondrocutaneous Graft for Reconstruction of the Ala Nasi<sup>☆</sup>



### Reconstrucción del ala nasal mediante injerto condrocútáneo

To the Editor:

The external nose is a sun-exposed area with a high incidence of skin tumors. These tumors are treated surgically in the majority of cases. The nasal ala, composed of mucosa, cartilage, and skin, is an anatomically complex structure and its reconstruction is thus also complex.<sup>1</sup> During reconstruction of defects of the ala we must take into account the size and thickness of the defect, the color and texture of the surrounding skin, symmetry with the contralateral ala, and the condition of the perilesional tissues. We must also evaluate the characteristics of possible donor sites and the patient's past history. The main objective is to preserve the valve function and the cosmetic appearance of the external nose.

We describe the case of a 77-year-old woman with a complex past history. She presented biopsy-confirmed recurrence of basal cell carcinoma on the right nasal ala.

The tumor recurrence (Fig. 1A) was treated using Mohs micrographic surgery (Fig. 1B), with complete excision being achieved in a single stage. This surgery left a full-thickness

defect of the nasal ala measuring  $0.8 \times 1$  cm, affecting the free border of the ala.

To repair the defect we decided to use a composite chondrocutaneous graft from the base of the helix. In this situation, the ideal donor site is the auricle of the ear not only for color and texture, but also because the anterior region of the helix permits simple graft extraction and direct closure.<sup>2</sup> The graft obtained presents cartilage between 2 skin surfaces. The cartilage provides mechanical stability and form to the graft and to the nasal ala, preventing collapse of the graft with respiratory movements.<sup>3</sup> Additionally, the cartilage prevents scar retraction and secondarily preserves valve function.

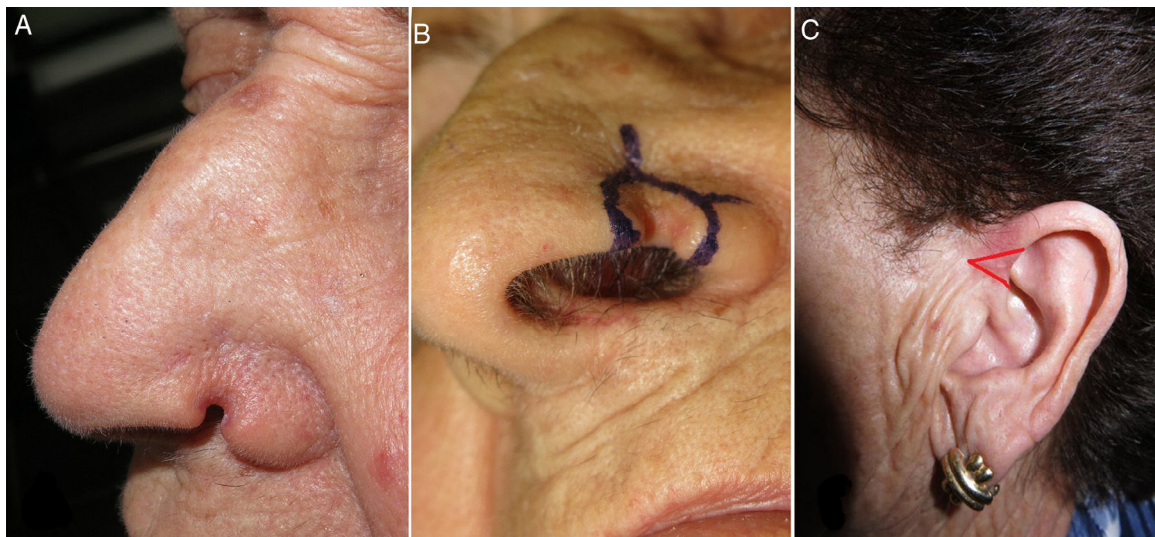
In our patient, we first designed and excised a V-shaped en bloc graft from the base of the helix, 1 mm larger than the defect (Fig. 1C).<sup>4</sup> The resulting defect in the helix was closed using interrupted sutures (Fig. 2B).

To fix the graft to the receptor site, we first sutured the tissue to the internal surface of the nasal ala using an absorbable 5/0 suture. The graft was then immobilized using a nasal pack. Finally, the skin of the external surface was sutured with 5/0 silk (Fig. 2A).<sup>3</sup>

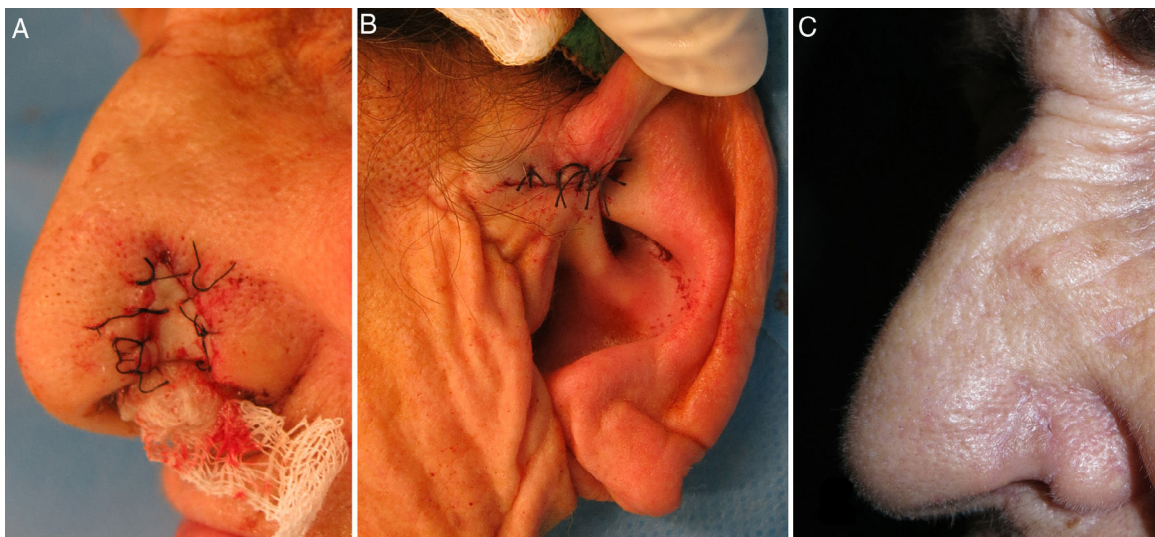
The use of a composite graft from the auricle of the ear to reconstruct the external nose was first described by König<sup>5</sup> in 1902. Its main advantages are that surgery can be performed in a single stage, with an en bloc graft, allowing the procedure to be completed in a single operation.

Factors that can reduce chondrocutaneous graft survival include smoking, alteration of the vascular supply by previous radiotherapy, the presence of scars, diabetes, and severe arteriosclerosis. Large grafts have high metabolic demands, reducing their likelihood of survival. Previous reports have therefore recommended a maximum diameter of 10 mm for chondrocutaneous grafts.<sup>3,4,6</sup> However, good results have been reported with grafts up to  $10 \times 18$  mm.<sup>7</sup>

<sup>☆</sup> Please cite this article as: Kueder-Pajares T, Prada-García C, Sanchez-Sambucety P, Rodriguez-Prieto MA. Reconstrucción del ala nasal mediante injerto condrocútáneo. *Actas Dermosifiliogr*. 2017;108:488–490.



**Figure 1** A, Recurrence of the basal cell carcinoma. Photograph taken preoperatively in outpatients. B, First stage of Mohs micrographic surgery. C, Design of the graft at the base of the helix.



**Figure 2** A and B, Postoperative appearance. C, Ten weeks after surgery.

Ideally, the center of the graft should be at no more than 5 mm from the blood supply.

Complications that can arise after extraction of the graft include asymmetry or contracture of the auricle of the ear, deformity, and a hypertrophic or hypo- or hyperpigmented scar.

This chondrocutaneous graft makes it possible to perform reconstruction of the 3 layers of the nasal ala in a single operation, preserving function and cosmetic appearance (Fig. 2 C). It is a good option for defects with a diameter up to 1 cm.

### Conflicts of Interest

The authors declare that they have no conflicts of interest.

### References

1. Driscoll BP, Baker SR. Reconstruction of nasal alar defects. *Arch Facial Plast Surg.* 2001;3:91–9.
2. Singh DJ, Bartlett SP. Aesthetic management of the ear as a donor site. *Plast Reconstr Surg.* 2007;120:899–909.
3. Brown JB, Cannon B. Composite Free Grafts of Two Surfaces of Skin and Cartilage from the Ear. *Ann Surg.* 1946;124:1101–7.
4. Maves MD, Yessenow RS. The use of composite auricular grafts in nasal reconstruction. *J Dermatol Surg Oncol.* 1988;14:994–9.
5. Lehman JA Jr, Garrett WS Jr, Musgrave RH. Earlobe composite grafts for the correction of nasal defects. *Plast Reconstr Surg.* 1971;47:12–6.
6. Son D, et al. A new mechanism associated with compositae graft success. *J Plast Reconstr Aesthet Surg.* 2010;63:1900–9.

T. Kueder-Pajares,<sup>a,\*</sup> C. Prada-García,<sup>b</sup>  
P. Sanchez-Sambucety,<sup>b</sup> M.A. Rodriguez-Prieto<sup>b</sup>

<sup>a</sup> *Servicio de Dermatología y Venereología, Hospital Clínico Universitario de Valladolid, Valladolid, Spain*

<sup>b</sup> *Servicio de Dermatología y Venereología, Complejo Asistencial Universitario de León, León, Spain*

\* Corresponding author.

*E-mail address:* [Tkueder@hotmail.com](mailto:Tkueder@hotmail.com) (T. Kueder-Pajares).  
1578-2190/

© 2016 Elsevier España, S.L.U. and AEDV. All rights reserved.