

Melanomas Arising on Tattoos: A Casual Association with Practical Implications[☆]



Melanomas sobre tatuajes: una asociación casual con implicaciones prácticas

To the Editor:

A 35-year-old man came to the clinic after noticing changes in a pigmented lesion on his right arm, where he had had a tattoo some 2 years previously. When the tattoo was placed, the tattooist avoided a pre-existing nevus, although during recent months this had grown until it reached the tattoo and came to the patient's attention (Fig. 1 A and B). Clinical suspicion led us to remove the lesion. Histopathology showed it to be a superficial melanoma (Breslow depth, 0.35 mm) that had developed from a dysplastic nevus (Fig 1 C and D).

Another patient (82 years) was referred by his family doctor with a suspected melanoma, which took the form of a pigmented lesion on a tattoo on the left arm that was

observed during an examination for other reasons. The tattoo was more than 60 years old and the patient had not noticed the lesion for which he was referred, namely, an asymmetrical pigmented macule with irregular borders and various colors, with areas suggestive of regression (Fig. 2 A). Histopathology confirmed the lesion to be a superficial, partially regressing melanoma (Breslow depth, 0.4 mm) with no associated lesions.

A possible pathogenic association between tattoos and melanoma has been the subject of speculation in the literature, with potential causes including local trauma, the carcinogenic potential of the ink, and even a possible increase in absorption of ultraviolet radiation.¹ However, this finding is now considered a mere coincidence.¹⁻³ In recent years, we have seen a marked increase in the popularity of permanent tattoos in Spain, especially among young people. The estimated prevalence of tattoos in Europe is 10%, which increases to 25% in adults aged 20-35 years.³ However, cases of melanoma on tattoos are still rare,² as demonstrated by the fact that only 28 cases have been reported in the literature to date (30 counting the 2 cases reported here).¹⁻¹⁰ Together with the lack of cases of

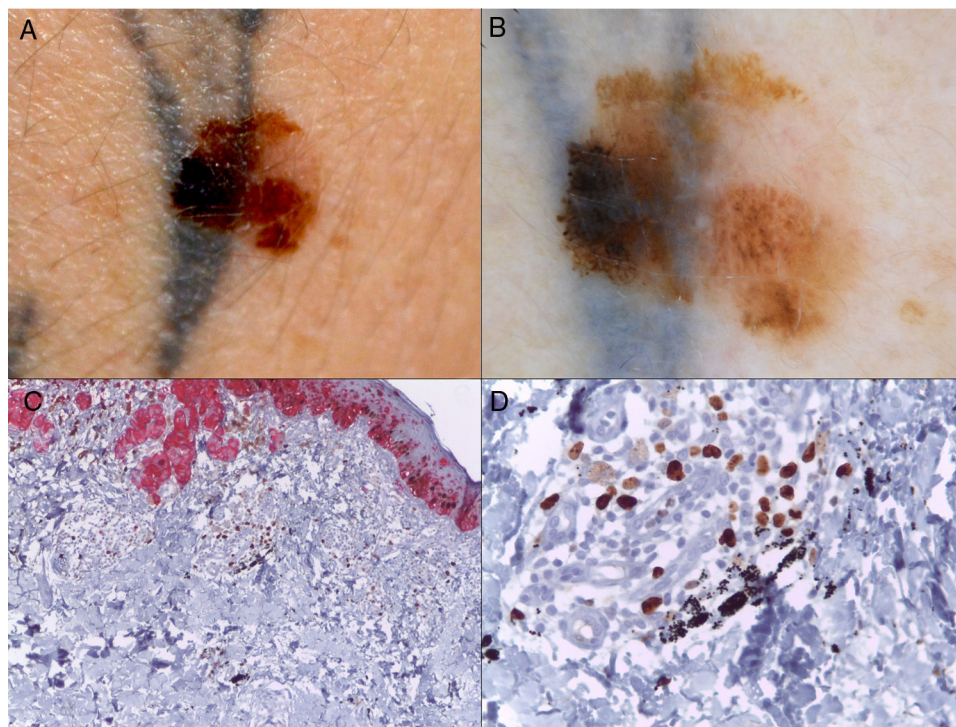


Figure 1 A, Melanoma over a recent tattoo on the right arm. B, Dermoscopic image showing striking asymmetry of colors and highlighting the presence of an atypical pigment network, pseudopods, and irregularly distributed globules and spots. C, Histopathology based on HMB45-Ki67 immunohistochemistry showing the presence of nests of neoplastic cells in the dermis (red), as well as black granules of tattoo ink inside macrophages and free in the dermis (HMB45-Ki67, original magnification $\times 4$). D, Detail of the black granules of tattoo ink (HMB45-Ki67, original magnification $\times 40$).

[☆] Please cite this article as: Armengot-Carbó M, Barrado-Solís N, Martínez-Lahuerta C, Gimeno-Carpio E. Melanomas sobre tatuajes: una asociación casual con implicaciones prácticas. *Actas Dermosifiliogr.* 2017;108:678-680.

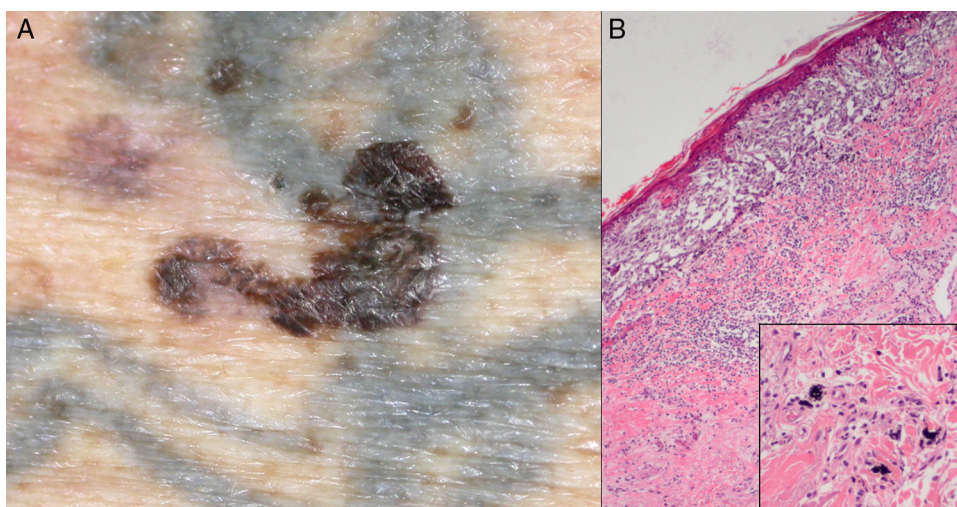


Figure 2 A, Melanoma on the left arm over a tattoo that is more than 60 years old. B, Histopathology of the melanoma, in which tattoo ink is visible (hematoxylin-eosin, original magnification $\times 4$). The inset shows a more detailed image (original magnification $\times 40$).

multiple melanoma over a single tattoo, this supports the notion that the association between tattoos and melanoma is merely casual.¹⁻³ Nevertheless, the finding of melanoma on a tattoo has several relevant implications.

On the one hand, the presence of a tattoo usually masks pigmented lesions and hampers early diagnosis of a potential melanoma on the part of both the patient and the dermatologist, thus leading to a delay in diagnosis.¹⁻⁸ It is essential to raise awareness among the population in general and among tattooists in particular that a tattoo should never be placed over pre-existing pigmented lesions.^{1,6} Similarly, when examining a patient with tattoos, the dermatologist should pay special attention to tattooed skin in order to avoid overlooking a hidden suspicious lesion.^{2,8} Of note, in the first patient we report and in 2 cases in the literature,^{9,10} the cosmetic alteration in the tattooed image caused by the melanoma made it easy for the patient to notice it, thus making for earlier detection than if the lesion had appeared at another site. Although these cases are exceptions to what we report above, there is no doubt that if tattooists adopted the practice of leaving an area of healthy skin around pre-existing nevi, any changes these could subsequently undergo would be more easily detected.⁹

On the other hand, there is a risk that if a tattoo is placed on a pigmented lesion, this may already be a melanoma, and multiple metastatic deposits could be seeded during placement, as occurred in a recently published case,⁷ thus highlighting the importance of avoiding previously pigmented lesions. Therefore, in specific cases with a risk of melanoma (patients with atypical nevus syndrome, multiple nevi, or a family history of melanoma), the individual should undergo a dermatological assessment before having the tattoo.³

Finally, before a tattoo is eliminated by laser, the tattooed skin should be carefully examined—both clinically and dermoscopically⁴—to detect potentially hidden pigmented lesions and avoid applying laser therapy over the areas affected (since this can alter their characteristics and lead to subsequent diagnostic errors). Alternatively, the lesions

should be removed before laser therapy if they are suspected of being melanomas. Therefore, laser removal of tattoos should only be performed by dermatologists.⁴

In conclusion, we present 2 new cases of melanoma on a tattoo. Although the association appears to be casual, it has several implications: the need for close attention during examination of the tattooed skin, the importance of raising awareness among tattooists and users that pigmented lesions should not be tattooed, and the importance of the fact that laser removal of a tattoo should always be performed by a dermatologist.

Conflicts of Interest

The authors declare that they have no conflicts of interest.

Acknowledgments

We are grateful to Dr. Josefa San Juan and to Dr. José Ferrando from the Histopathology Department of Hospital Arnau de Vilanova, Valencia, Spain for providing us with access to the sections in the second case.

References

1. Nolan KA, Kling M, Birge M, Kling A, Fishman S, Phelps R. Melanoma arising in a tattoo: Case report and review of the literature. *Cutis*. 2013;92:227-30.
2. Kluger N, Saarinen K. Melanoma on a tattoo. *Presse Med*. 2015;44:473-5.
3. Kluger N, Koskenmies S, Jeskanen L, Övermark M, Saksela O. Melanoma on tattoos: Two Finnish cases. *Acta Derm Venereol*. 2014;94:325-6.
4. Pohl L, Kaiser K, Raulin C. Pitfalls and recommendations in cases of laser removal of decorative tattoos with pigmented lesions: Case report and review of the literature. *JAMA Dermatol*. 2013;149:1087-9.

5. Varga E, Korom I, Varga J, Kohán J, Kemény L, Oláh J. Melanoma and melanocytic nevi in decorative tattoos: Three case reports. *J Cutan Pathol*. 2011;38:994–8.
6. Anthony EP, Godbolt A, Tang F, McMeniman EK. Malignant melanoma disguised in a tattoo. *Australas J Dermatol*. 2015;56:232–3.
7. Joyce CW, Duff G, McKenna D, Regan PJ. Malignant melanoma arising in red tattoo ink. *Arch Plast Surg*. 2015;42:475–7.
8. Tchernev G, Chokoeva AA. Melanoma in a Chinese dragon tattoo. *Lancet*. 2015, [http://dx.doi.org/10.1016/S0140-6736\(15\)01038-7](http://dx.doi.org/10.1016/S0140-6736(15)01038-7).
9. Caccavale S, Moscarella E, de Fata Salvatore G, Piccolo V, Russo T, Argenziano G. When a melanoma is uncovered by a tattoo. *Int J Dermatol*. 2016;55:79–80.
10. Deinlein T, Arzberger E, Scarfi F, Fink Puches R, Hofmann-Wellenhof R, Zalaudek I. A dangerous fruit of Belladonna. *J Am Acad Dermatol*. 2016;75:e93–4.

M. Armengot-Carbó,^{a,*} N. Barrado-Solís,^a
C. Martínez-Lahuerta,^b E. Gimeno-Carpio^c

^a Servicio de Dermatología, Hospital General Universitario de Castellón, Castellón de la Plana, Spain

^b Servicio de Anatomía Patológica, Hospital General Universitario de Castellón, Castellón de la Plana, Spain

^c Servicio de Dermatología, Hospital Arnau de Vilanova, Valencia, Spain

* Corresponding author.

E-mail address: miquelarmengot@gmail.com

(M. Armengot-Carbó).

1578-2190/

© 2017 Elsevier España, S.L.U. and AEDV. All rights reserved.

Cerebral Cavernous Malformation: When the Key to Diagnosis Is on the Skin[☆]



Cavernomatosis cerebral múltiple: cuando la clave del diagnóstico está en la piel

To the Editor:

Multiple cerebral cavernous malformations (MCCMs) is characterized by the presence of multiple vascular malformations in the central nervous system. It can also affect the retina and the skin. The disease usually presents sporadically; of the patients that present the familial form, the majority show autosomal dominant inheritance.¹ We describe 2 families with familial MCCMs diagnosed because of skin lesions detected in 2 children of 12 and 13 years of age.

Our first patient was a 12-year-old boy with no past history of interest. He was seen for asymptomatic skin lesions of vascular appearance that had been present for a year. Physical examination revealed 2 reddish papules similar to cherry angiomas on the neck and right leg (Fig. 1A), 3 reddish-pink macules with a dotted dermoscopic pattern on the trunk and left leg (Fig. 1B), an erythematous macule on the trunk, with a reticulated vascular dermoscopic pattern (Fig. 1C), and 2 small, violaceous angiokeratoma-like papules on the trunk and left leg (Fig. 1D). The initial family history was negative, but a targeted medical history revealed the presence of cerebrovascular lesions in the maternal grandmother, diagnosed on magnetic resonance imaging (MRI) performed 5 years earlier for sudden onset hearing loss. Skin

examination of the grandmother revealed multiple reddish, cherry angioma-type papules on the trunk. The medical history and physical examination of the other family members only detected 2 bluish nodular lesions suggestive of venous malformations on the right arm of the patient's mother. Given the family history, MRIs of the patient and his mother were requested, observing the presence of cerebral cavernous malformations in both of them. Genetic analysis was performed on the 3 affected family members, revealing the c.268C > T mutation, a substitution of arginine that gives rise to a stop codon at position 90 of exon 6 of gene *KRIT1* (*CCM1*) (Molecular Genetics Laboratory, Hôpital Lariboisière, Paris, France), which confirmed the diagnosis of MCCMs.

The second patient was a 13 year-old boy with no past history of interest. He presented a lesion that had arisen on his knee some months earlier. The clinical manifestations, dermoscopy, and histology were suggestive of angiokeratoma (Fig. 2, A-C). The medical history revealed that the father had been diagnosed with MCCMs. The patient's MRI revealed MCCMs (Fig. 2D). The genetic analysis showed a pattern of deletion of exons 1, 2, and 3 of gene *KRIT1* (*CCM1*) (Genetics Department, Fundación Jiménez Díaz, Madrid, Spain).

MCCMs can arise sporadically (80%) or be familial (20%).² The familial form has an autosomal dominant pattern of inheritance with variable clinical penetrance. To date, 3 responsible genes have been identified—*CCM1* (*KRIT1*), *CCM2* (*MGC4607*), and *CCM3* (*PDCD10*)—with more than 100 different mutations.³ The *KRIT1* gene, detected in both our families, is the most common mutation in patients with skin lesions.^{4,5} The etiology and pathogenic mechanism are unknown, although it has been observed that the 3 proteins coded by the responsible genes (*KRIT1*, *MGC4607*, and *PDCD10*) are implicated in angiogenesis and in vascular remodeling.⁶

In MCCMs, the cerebral lesions remain asymptomatic in up to 40% of patients.⁷ Clinical manifestations include epileptic crises, headaches, and focal neurological deficits, due either to hemorrhage or to the compression of adjacent

[☆] Please cite this article as: Escudero-Góngora MM, Bauzá A, Giacaman A, Martín-Santiago A. Cavernomatosis cerebral múltiple: cuando la clave del diagnóstico está en la piel. *Actas Dermosifiliogr*. 2017;108:680–683.