

erogeneity of the disease.⁷ Drug-induced and idiopathic forms are traditionally recognized. The drug-related form, occurring most commonly with vancomycin, followed by phenytoin,^{4,8,9} develops between 1 and 30 days after starting treatment. The possibility of a tumor-related form (particularly with hematologic tumors) has also been suggested. The form similar to TEN is perhaps the most striking mode of clinical presentation of LAD, as it is most commonly associated with erythroderma, a positive Nikolsky sign, and palmoplantar and mucosal involvement; vancomycin also the most frequently implicated drug.⁷

The treatment of choice is dapsone, though corticosteroids, azathioprine, methotrexate, ciclosporin, and immunoglobulins are occasionally used.^{2,3,10} The treatment of LAD that presents as TEN is no different from that of other forms of LAD, although the greater extension and severity of the skin lesions requires greater attention to physical measures. Withdrawal of the suspected drug, when there is one, is the first and sometimes only step. On other occasions it is necessary to resort to systemic corticosteroids. The prognosis will also depend on the patient's basal situation and comorbid conditions.^{2,3,7} The use of immunoglobulins in LAD, as in other blistering diseases,¹⁰ is reserved for severe and refractory cases.

In summary, LAD is a heterogeneous entity that, among its numerous forms of presentation, can mimic TEN.^{4,5,7,9} It is important to include LAD in the differential diagnosis of vesiculobullous dermatoses and of TEN, making it advisable routinely to perform not only histological study in these cases but also immunofluorescence.

Conflicts of Interest

The authors declare that they have no conflicts of interest.

References

1. Lings K, Bygum A. Linear IgA bullous dermatosis: A retrospective study of 23 patients in Denmark. *Acta Derm Venereol.* 2015;95:466–71.

2. Chaudhari S, Mobini N. Linear IgA bullous dermatosis: A rare clinicopathologic entity with an unusual presentation. *J Clin Aesthet Dermatol.* 2015;8:43–6.
3. Souza BC, Fregonesi NCFP, Tebcherani AJ, Sanchez APG, Aoki V, Fernandes JC. Linear IgA bullous dermatosis: Report of an exuberant case. *An Bras Dermatol.* 2013;88 Suppl 6: S67–70.
4. Waldman MA, Black RD, Callen JP. Vancomycin-induced linear IgA bullous disease presenting as toxic epidermal necrolysis. *Clin Exp Dermatol.* 2004;29:633–6.
5. Schroeder D, Saada D, Rafea M, Ingen-Housz-Oro S, Valeyrie-Allanore L, Sigal ML. Dermatose à IgA linéaire induite par le verapamil: présentation inhabituelle à type de nécrolyse épidermique toxique. *Ann Dermatol Venerol.* 2011;138: 302–6.
6. Antiga E, Caproni M, Fabbri P. Linear immunoglobulin A bullous dermatosis: Need for an agreement on diagnostic criteria. *Dermatology.* 2013;226:329–32.
7. Kakar R, Paugh H, Jaworsky C. Linear IgA bullous disease presenting as toxic epidermal necrolysis: A case report and review of the literature. *Dermatology.* 2013;227: 209–13.
8. Kang MJ, Kim HO, Park YM. Vancomycin-induced linear IgA bullous dermatosis: A case report and review of the literature. *Ann Dermatol.* 2008;20:102–6.
9. Tran D, Kossard S, Shumack S. Phenytoin-induced linear IgA dermatosis mimicking toxic epidermal necrolysis. *Australas J Dermatol.* 2003;44:284–6.
10. Czernik A, Toosi S, Bystryn JC, Grando SA. Intravenous immunoglobulin in the treatment of autoimmune bullous dermatoses: An update. *Autoimmunity.* 2012;45:111–8.

J. Ruiz-Rivero,* I. Hernández-Aragüés, A. Pulido-Pérez, R. Suárez-Fernández

*Servicio de Dermatología y Venereología
Médico-Quirúrgica, Hospital General Universitario
Gregorio Marañón, Madrid, Spain*

* Corresponding author.

E-mail address: juncalrr@gmail.com (J. Ruiz-Rivero).

1578-2190/

© 2017 Elsevier España, S.L.U. and AEDV. All rights reserved.

Lichen Striatus in Childhood: Is It Associated With Atopic Dermatitis?[☆]



Liquen estriado en la infancia. ¿Una entidad relacionada con la dermatitis atópica?

To the Editor:

Lichen striatus (LS) is an uncommon asymptomatic acquired dermatosis that mainly affects children.

The diagnosis is usually clinical, as the histologic findings are variable and depend on the phase of the disease. It presents with flat-topped, desquamating erythematous papules with a linear distribution along the Blaschko lines (Fig. 1).

A possible association with atopic dermatitis has been suggested.^{1–5} We designed this retrospective study in order to describe the characteristics of children with this disease and to determine whether a higher prevalence of atopic dermatitis existed in our population.

We present a case series of children diagnosed with LS at our centre in Valencia, Spain, from January 2008 to the present time, including all patients under 18 years old with compatible clinical manifestations.

Socio-demographic, clinical, histological, and therapeutic variables were analyzed, as well any relationship with possible triggering factors, including in particular atopic

[☆] Please cite this article as: García-Briz MI, Santos-Alarcón S, Fuertes-Prosper MD, Mateu-Puchades A. Liquen estriado en la infancia. ¿Una entidad relacionada con la dermatitis atópica? *Actas Dermosifiliogr.* 2017;108:882–884.

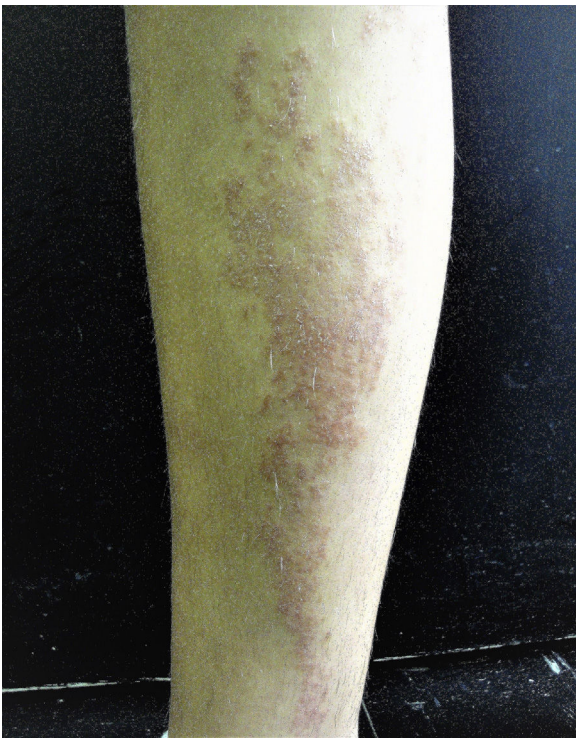

Figure 1 Clinical photograph of a patient with lichen striatus.

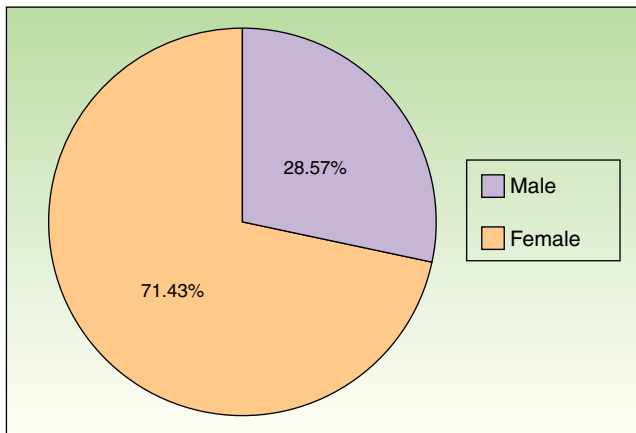


Figure 2 Distribution of patients according to sex.

dermatitis, diagnosed in accordance with the Hanifin and Rajka criteria.

A total of 35 patients were included in the study. The mean age was 5 years and there was a predominance of female (Fig. 2).

Only 3 diagnostic biopsies were required in cases with atypical clinical manifestations. In the other patients, the characteristics of the lesions were consistent with LS and there was no need to perform an invasive procedure for confirmation.

The lesions were mostly asymptomatic (85.7%). When symptomatic, the most common complaint was pruritus (14.3%).

The site most frequently affected was the lower limbs (57.2%). None of the children presented associated onychodystrophy.

The majority of the lesions were managed with emollients and photoprotection (73.5%). Topical corticosteroids were used in the remaining patients.

Sixteen patients were lost to follow-up. None of those children were subsequently referred back to our department by their pediatrician or primary care physician for further follow-up. A complete response was achieved in all the other children except one who presented a partial improvement.

With regard to possible related factors, the medical histories of 2 patients revealed that the lesions appeared after a previous diagnosis of infection.

Nine patients presented a previous diagnosis of atopic dermatitis made by a specialist. In 5 patients, manifestations of atopy were found in the medical history (most frequently pityriasis alba) and in 1 patient a family history was found in first-degree relatives.

With respect to other related diseases, 9 children presented bronchial hyperreactivity (25.7%) and 3 patients had been diagnosed with some form of allergy.

Lichen striatus is an uncommon, asymptomatic acquired dermatosis that mainly affects children, with a predominance in female.^{1,2,6}

The lesions do not usually produce symptoms, but when they are present, the most common is pruritus.⁶

This disease tends to resolve spontaneously in 6 to 24 months. In some cases a transitory residual hypopigmentation can remain. It is therefore useful to explain to patients and their parents that this is a benign condition, and to individualize therapeutic management.

Several authors have proposed seasonal changes as possible triggering stimuli, though there is no general agreement. Some of them report an increase in incidence of LS in summer,^{3,7} while others report the increase in autumn and winter.¹ This observation has given rise to the association with infectious diseases as a triggering factor,⁸ nevertheless no relationship was found in our patients. In the series of 115 patients with LS studied by Patrizi et al.,¹ only 3 children presented prodromal symptoms suggestive of viral infection. Because of that, this theory cannot be confirmed despite studying a larger number of patients.

Retrospective studies have highlighted the relationship between atopic dermatitis and LS,¹⁻⁵ considering that the immune changes present in atopic dermatitis could be a predisposing factors for the induction of LS. Other authors, such as Happle,⁹ suggest that this disease should be included in the list of acquired disorders with a nevoid distribution/pattern and postulate that it could represent a mosaic form of atopic dermatitis.

Our series supports the findings of previous studies with a larger number of patients, in which atopic dermatitis could be considered to be a predisposing factors for LS.¹

However, the results reported in the literature are based on retrospective studies, and prospective studies with a larger number of patients are needed to investigate the association of LS with triggering factors and concomitant diseases.

Conflicts of Interest

The authors declare that they have no conflicts of interest.

References

1. Patrizi A, Neri I, Fiorentini C, Bonci A, Ricci G. Lichen striatus: Clinical and laboratory features of 115 children. *Pediatr Dermatol.* 2004;21:197–204.
2. Taniguchi K, Parolin L, Giraldo S, Carvalho VO, De Oliveira C, Favre H. Lichen striatus: Description of 89 cases in children. *Pediatr Dermatol.* 2004;21:440–3.
3. Peramiqel L, Baselga E, Krauel J, Palou J, Alomar A. Liquen estriado sistematizado bilateral. *Actas Dermosifiliogr.* 2004;95:126–8.
4. Toda K, Okamoto H, Horito T. Lichen striatus. *Int J Dermatol.* 1986;25:584–5.
5. Di Iernia V, Ricci G, Bonci A, Patrizi A. Lichen striatus and atopy. *Int J Dermatol.* 1991;30:453–4.
6. Ramos C, Bravo F. Liquen estriado. *Folia dermatol. Peru.* 2009;20:121–4.
7. Kennedy D, Rogers M. Lichen striatus. *Pediatr Dermatol.* 1996;13:95–9.
8. Hafner C, Landthaler M, Vogt T. Lichen striatus (blaschitis) following varicella infection. *J Eur Acad Dermatol Venereol.* 2006;20:1345–7.
9. Happle R. *Mosaicism in Human Skin.* Berlin Heidelberg: Springer-Verlag; 2014. p. 194.

M.I. García-Briz,* S. Santos-Alarcón, M.D. Fuertes-Prosper, A. Mateu-Puchades

Servicio de Dermatología, Hospital Universitario Doctor Peset, Valencia, España

* Corresponding author.

E-mail address: mariwelchy@gmail.com (M.I. García-Briz). 1578-2190/

© 2017 Elsevier España, S.L.U. and AEDV. All rights reserved.

Primary Mucinous Carcinoma of the Skin: A Case Report[☆]



Carcinoma mucinoso primario cutáneo: presentación de un caso

To the Editor:

Primary cutaneous mucinous carcinoma (PCMC) is a rare neoplasm of the adnexa of the skin, with around 150 cases published in the literature.^{1,2} Clinically, it usually presents in adults as a solitary, asymptomatic, erythematous nodule, papule, or cyst of variable size, typically occurring on the face or scalp or in the axilla.² It had been thought to arise from the eccrine sweat glands,^{2,3} but apocrine differentiation has recently been shown in some cases.¹ In general, PCMCs are slow-growing tumors and have an indolent behavior.² However, late recurrence and metastases have been reported, probably related to incomplete excision of the tumor.³ Histologically, it is indistinguishable from metastatic mucinous adenocarcinomas from other organs,¹ particularly from the breast, which can make diagnosis difficult. We present a case of this rare entity and review the literature, discussing the main recommendations and the immunohistochemical reactions useful to reach a correct diagnosis.

Case Description

The patient was a 68-year-old man with no past history of interest. He was seen for a mobile nodular lesion

that had been present for 2 years in the left axilla. The lesion was not adherent to deeper planes and measured 1.5 cm in diameter. The clinical diagnosis was epidermal cyst. Macroscopically, the sample consisted of a number of reddish fragments of soft tissue, including areas with a gelatinous appearance, with an overall diameter of 3 cm. Histologically, there were fragments of skin with abundant eccrine and apocrine glands that were diffusely infiltrated by lakes of mucin (Fig. 1A). These lakes contained cords and solid nests of cuboidal and round epithelial cells that, in some areas, formed glandular structures, with scattered cribriform lumina (Fig. 1B). The cells presented cytologic atypia and occasional mitotic figures. Periodic acid Schiff stain revealed an abundant quantity of mucin (Fig. 1C). Immunohistochemistry was positive for CK7 (Fig. 1D), CK19, epithelial membrane antigen, GATA3, estrogen receptors (ER), progesterone receptors (PR), and p63 (in isolated small cells) (Fig. 1F); the study was negative for CK20 (Fig. 1E), CK5/6, CD15, and mammaglobin. The pathologic diagnosis based on these findings was mucinous carcinoma. Subsequently the patient underwent complete clinical evaluation, including positron emission tomography (PET) in which no increased uptake was observed in other organs. In cases such as ours, it cannot be ruled out that the tumor may have arisen in a focus of ectopic breast tissue in the axilla; however, as no remnant of healthy breast tissue was observed in the surgical sample, we made a definitive diagnosis of PCMC.

Discussion

PCMC is a rare entity that was first described in 1952 by Lenox et al.² It usually shows an indolent clinical course and is typically present for several years before diagnosis; it is often misdiagnosed clinically as an epidermal cyst, sebaceous carcinoma, cystic basal cell carcinoma, squamous cell carcinoma, neuroma, or pilomatixoma.² Late recurrence and metastases due to incomplete excision of the tumor³ and lymphovascular invasion have been reported.⁴ Apparently,

[☆] Please cite this article as: Areán-Cuns C, Córdoba-Iturriagoitia A, Aguiar-Losada B, Yanguas-Bayona I. Carcinoma mucinoso primario cutáneo: presentación de un caso. *Actas Dermosifiliogr.* 2017;108:884–886.