

their series of 25 patients, Zeng YP et al.<sup>1</sup> found a periadnexal infiltrate in 12 patients and a perineural infiltrate in 5, more common than previously reported in LA.

It should be noted that LA can occasionally be confused with mycosis fungoides (MF), and some authors even defend a relationship between the 2 diseases, suggesting that LA may have the capacity to progress to MF.<sup>7</sup>

The diagnosis is clinical and pathological and the differential diagnosis should include other pigmented purpuric dermatoses, mycosis fungoides, lichen striatus, blaschkitis, traumatic contusions, contact dermatitis, and Langerhans histiocytosis.<sup>1,8</sup>

The prognosis of the disease is variable and unpredictable; most commonly there is spontaneous resolution with subsequent recurrences.<sup>3,4,9</sup> A number of therapeutic alternatives have been proposed, including topical corticosteroids, phototherapy, and calcineurin inhibitors, although there is still no truly effective option.<sup>4</sup>

We have presented a case of segmental LA in a patient with a high skin phototype, a factor that altered the color of the lesion, giving it a more pigmented appearance than usual and masking the characteristic golden-yellow halo. Dermoscopy and histology enabled us to reach a correct diagnosis. Neonatal LA has been reported in the literature,<sup>10</sup> but we have found no other cases of congenital LA. In our patient, the lesion observed when he was 9 years old was at the same site as the lesion described in the first neonatal examination. In addition, the patient's parents described it as the same lesion. This would all support its congenital nature, though this cannot be confirmed, as no dermatologic follow-up was performed on this patient after birth.

**Conflicts of Interest**

The authors declare that they have no conflicts of interest.

**References**

1. Zeng YP, Fang K, Ma DL. Lichen aureus: Clinicopathological features in a Chinese series. *Eur J Dermatol.* 2016;26:290–4.
2. Tortelly VD, Silva RS, Mota AN, Piñeiro-Maceira J. Agminate lichen aureus. *An Bras Dermatol.* 2013;88 Suppl 1:S143–5.
3. Mahajan VK, Chauhan P. Lichen aureus. *Indian J Pediatr.* 2014;81:420–1.
4. Hazan C, Fangman B, Cohen D. Lichen aureus. *Dermatol Online J.* 2007;13:23.
5. Zaballos P, Puig S, Malveyh J. Dermoscopy of pigmented purpuric dermatoses (lichen aureus): A useful tool for clinical diagnosis. *Arch Dermatol.* 2004;140:1290–1.
6. Gelmetti C, Cerri D, Grimalt R. Lichen aureus in childhood. *Pediatr Dermatol.* 1991;8:280–3.
7. Aung PP, Burns SJ, Bhawan J. Lichen aureus: An unusual histopathological presentation: A case report and a review of literature. *Am J Dermatopathol.* 2014;36:e1–4.
8. Zhao YK, Luo DQ, Sarkar R, Xie WL. Segmental lichen aureus in a young woman with spontaneous improvement. *J Dtsch Dermatol Ges.* 2014;12:260–2.
9. Sarkissian L, Villani AP, Kanitakis J. *Dermpath & clinic: Zosteriform lichen aureus.* *Eur J Dermatol.* 2016;26:215–6.
10. Saito Y, Shimomura Y, Orime M, Kariya N, Abe R. Segmental lichen aureus in infancy. *Clin Exp Dermatol.* 2017;42:215–7.

O. Corral-Magaña,\* J. Escalas Taberner, A. Bauzá Alonso, A. Martin-Santiago

*Servicio de Dermatología, Hospital Universitario Son Espases, Palma de Mallorca, Baleares, España*

\* Corresponding author.

E-mail address: [oricmag@gmail.com](mailto:oricmag@gmail.com) (O. Corral-Magaña). 1578-2190/

© 2017 Elsevier España, S.L.U. and AEDV. All rights reserved.

**Mumps, Measles, and Rubella Vaccine for the Treatment of a Recalcitrant Subungual Wart<sup>☆</sup>**



**Vacuna triple vírica como tratamiento de verruga subungueal recalcitrante**

To the Editor:

Common warts are viral infections caused by the human papillomavirus. They can occasionally represent a therapeutic challenge, particularly at certain sites such as the subungual or periungual regions and on the soles of the feet. Although there is an extensive therapeutic arsenal for the

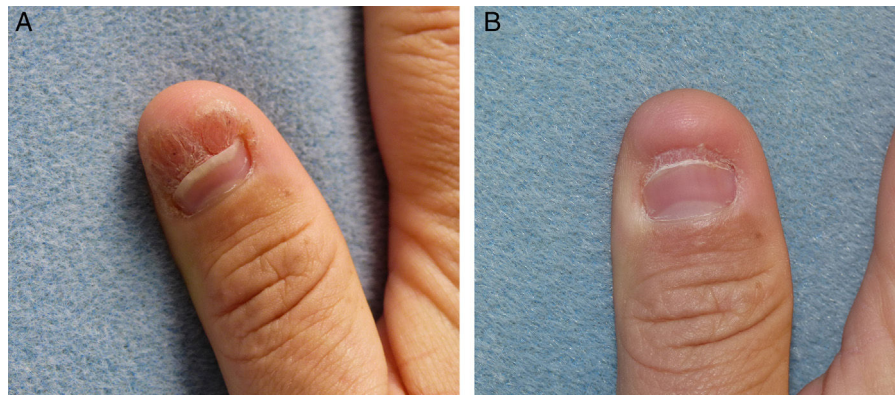
treatment of these warts, resistance to treatment is common at these sites.

A 45-year-old man, with no past medical history of interest, was seen for a subungual wart that had been present on the first digit of the right hand for 2 years, causing nail dystrophy, with pain and limitation for performing domestic

**Table 1** Previous Treatments in Our Patient and Their Duration.

Treatment	Duration
50% salicylic acid under occlusive dressing	8 wk
Topical 5% 5-fluorouracil	6 wk
Topical 5% imiquimod	6 wk
50% salicylic acid + 5% 5-fluorouracil	6 wk
Cryotherapy	4 cycles at 2-week intervals
Pulsed dye laser	4 cycles at 3-week intervals

<sup>☆</sup> Please cite this article as: Morales-Raya C, Maroñas-Jiménez L, Aragón-Miguel R, Postigo-Llorente C. Mumps, Measles, and Rubella Vaccine for the Treatment of a Recalcitrant Subungual Wart. *Actas Dermosifiliogr.* 2017;108:966–968.



**Figure 1** A, Subungual wart prior to treatment. B, After 7 treatment cycles.

and occupational tasks that required use of the finger-thumb pincer grip (Fig. 1A). Numerous treatments, summarized in Table 1, had been attempted, including in combination, but had been unsuccessful. After performing biopsy to rule out verrucous carcinoma, it was decided to start immunotherapy treatment with the trivalent mumps, measles, and rubella (MMR) vaccine by local injection. Injections of 0.3 ml (each vial contains 0.5 ml) were performed at 2-week intervals. No previous immunization was required as the patient had received MMR vaccine in childhood. After 5 sessions, inflammatory changes were observed in the area, with the appearance of edema and erythema, and after the seventh session the wart disappeared completely (Fig. 1B). No adverse effects were observed, except for moderate pain during the injection, and there has been no recurrence after more than a year of follow-up.

The treatment of common warts at certain sites, such as the subungual region, can be frustrating. A wide range of therapies with different mechanisms of action have been tried, most commonly involving destructive methods or immunotherapy.<sup>1</sup> Immunotherapy techniques include contact allergens, such as diphencyprone and dinitrochlorobenzene, and immunomodulators, which can be topical, such as imiquimod, or oral, such as cimetidine and zinc sulfate.<sup>2</sup> In addition, ever more trials of intralesional immunotherapy are being performed, with antigens such as candidin and the tuberculosis antigen, and with vaccines such as the mumps or MMR vaccines.<sup>3</sup> Although the mechanism of action remains unclear, this therapy is thought to induce a Th1-cell-mediated immune response. Cytokines released in the response include interleukin-2 and  $\gamma$ -interferon, which are released in much higher concentrations at the site of injection, focusing the local immune response in that area and favoring elimination of the human papillomavirus.<sup>4</sup> Local trauma may contribute to intensification of the response. Furthermore, the immunomodulatory effect may act not only locally, but also at a distance, as it is not uncommon to see the disappearance of warts at distant sites.<sup>5</sup> For this immune response to develop, the patient must already have been exposed to one or more of these antigens, either by previous vaccination in accordance with the vaccination calendar, or by direct contact with the virus in the past.<sup>5</sup> When patients have not been immunized, an initial dose of subcutaneous vaccine is recommended.

The complete response rate varies between 27% and 81%, with each patient requiring a mean of 3.6 cycles at 2-week intervals.<sup>3</sup> The most common adverse effects include pseudo-influenza symptoms and pain at the site of injection; no serious adverse effects have been observed.<sup>3</sup> Advantages of intralesional over traditional topical immunotherapy include its cost, the availability of antigens, and possible effects at a distance from the injection site.<sup>4</sup> The vaccine can be obtained from the hospital pharmacy or directly from a high-street pharmacy with a medical prescription. The cost of a vial of vaccine is of approximately 15 euros, which may be subsidized by the health service provider.

In conclusion, the availability, cost-effectiveness, and absence of serious adverse effects of intralesional immunotherapy with the trivalent vaccine make it a useful option for the management of warts refractory to other treatments.

### Conflicts of Interest

The authors declare that they have no conflicts of interest.

### References

- Muñoz Santos C, Pigem R. Nuevos tratamientos en la infección por virus del papiloma humano. *Actas Dermosifiliogr.* 2013;104:883-9.
- Gerlero P, Hernández-Martín Á. Treatment of warts in children: An update. *Actas Dermosifiliogr.* 2016;107:551-8.
- Aldahan AS, Mlacker S, Shah VV, Kamath P, Alsaidan M, Samarkandy S, et al. Efficacy of intralesional immunotherapy for the treatment of warts: A review of the literature. *Dermatol Ther.* 2016;29:197-207.
- Nofal A, Nofal E, Yosef A, Nofal H. Treatment of recalcitrant warts with intralesional measles, mumps, and rubella vaccine: A promising approach. *Int J Dermatol.* 2015;54:667-71.
- Na CH, Choi H, Song SH, Kim MS, Shin BS. Two-year experience of using the measles, mumps and rubella vaccine as intralesional immunotherapy for warts. *Clin Exp Dermatol.* 2014;39:583-9.

C. Morales-Raya,\* L. Maroñas-Jiménez, R. Aragón-Miguel, C. Postigo-Llorente

Servicio de Dermatología, Hospital Universitario 12 de Octubre, Madrid, Spain

\* Corresponding author.

E-mail address: [carlosmoralesraya@hotmail.com](mailto:carlosmoralesraya@hotmail.com)

(C. Morales-Raya).

1578-2190/

© 2017 Elsevier España, S.L.U. and AEDV. All rights reserved.

## Ultrasound Characterization of Psoriasis of the Nails: A Case-Control Study<sup>☆</sup>



### Caracterización ecográfica de la psoriasis ungueal: estudio de casos y controles

To the Editor:

High-frequency B-mode ultrasonography and Doppler study can reveal changes in nail anatomy and vascularization in patients with nail psoriasis (NPs). The primary objective of this study was to describe thumbnail ultrasound findings in a series of adult patients with psoriasis involving the thumbnail. It was decided to focus on the thumbnail as this is the largest finger nail and also the one most often affected in NPs. A nonprospective, multicenter, cross-sectional case-control study was performed in which hospitals in 4 Spanish provinces participated. The controls were consecutive healthy subjects with no clinical disorders of the thumbnail who attended the dermatology clinic. The 5 investigators performed a single ultrasound study of each patient with the same parameters: 18 MHz linear transducer (B mode), between 6.6 and 12.5 MHz in Doppler mode, pulse repetition frequency of 750 per second and wall filter of 3. The structure and thickness of the nail plate as well as the thickness of the nail bed (distance between the ventral lamina and the phalange) were assessed along 2 axes, and Doppler signal of the nail bed and matrix area was assessed using a semiquantitative scale (0-3).<sup>1</sup> The nail bed was defined as the area located below the nail plate distal to the eponychium (cuticle) and the matrix area as the area located below the proximal fold that delimits proximally with the insertion of the extensor tendon of the thumb and distally with the nail bed. The statistical analyses were performed with the SPSS program, version 21.0, and statistical significance was set at 0.05.

Seventy-nine participants were included, 36 cases and 43 controls. The mean age was 44 years, 75% were women, and the mean body mass index was 25 kg/m<sup>2</sup>, with no significant differences between the 2 groups. In patients with psoriasis, the mean age of onset of NPs was 32 years, the mean PASI was 5, 19% were diagnosed with peripheral psoriatic arthritis (PsA) (n = 7), and 30% were taking systemic treatment for

NPs (54% methotrexate, 27% biologic agents, and 19% other agents). Of the cases, 72% had clinical involvement of the nail bed, 67% of the nail matrix, and 39% had involvement of both. The most frequent disorder was pitted nails (83%), followed by onycholysis (65%), and subungual hyperkeratosis (46%). Ultrasound of the nail plate showed a regular trilaminar structure in 95% of controls and 25% of cases ( $P < .05$ ). In patients with NPs, plate thickening was observed (1.02 mm longitudinal axis and 1.08 mm transversal axis) and the nail bed (2.19 mm longitudinal axis and 2.21 mm transversal axis), with significant difference with controls (1.69 mm) (Table 1). The Doppler signal from the nail bed showed a mean and a mode of 1 in cases and 0 in controls ( $P < .05$ ). The Doppler study of the matrix area of the cases showed a median of 1 and a mode of 2 while the controls showed a median of 1 and a mode of 0 ( $P < .05$ ) (Fig. 1). Comparison of the ultrasound findings of the psoriatic patients with or without PsA did not show any significant differences.

In psoriatic patients, ultrasound changes in the nail plate, bed and matrix and in the insertion of the thumb extensor tendon have been observed.<sup>1-6</sup> Gisondi et al.<sup>5</sup> reported nail plate and bed thickening in patients with NPs, and our results were similar. Sandobal et al.<sup>6</sup> assessed the thickness of the nail bed of patients with NPs, PsA, rheumatoid arthritis, and controls, and established a cutoff of 2 mm (80% sensitivity and 71% specificity) as a predictive factor for NPs and PsA, and our study supported this finding. The present study assessed, for the first time separately the Doppler signal of the nail bed and matrix area, and statistically significant differences were obtained in both assessments with respect to controls. The present study has certain limitations. First is the technological limitation inherent in all ultrasound studies, whereby the more up to date the ultrasound system, the greater the sensitivity for Doppler

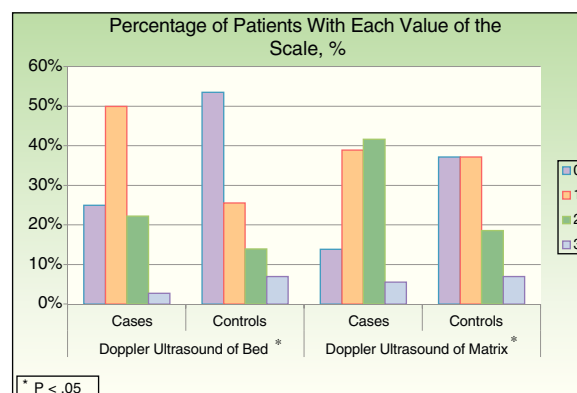


Figure 1 Doppler signal of the nail bed and matrix. Semiquantitative scale (0-3).

\* $P < .05$ .

<sup>☆</sup> Please cite this article as: Vidal D, Alfageme F, Ruiz-Villaverde R, Arias-Santiago S, Martorell A. Caracterización ecográfica de la psoriasis ungueal: estudio de casos y controles. Actas Dermosifiliogr. 2017;108:968-969.