



ORIGINAL ARTICLE

Diagnostic Tools to Use When We Suspect an Allergic Reaction to a Tattoo: A Proposal Based on Cases at Our Hospital[☆]



I. González-Villanueva,^{a,*} J.F. Silvestre Salvador^b

^a Servicio de Dermatología, Hospital General Universitario de Alicante – ISABIAL, Alicante, Spain

^b Unidad de Alergia Cutánea, Servicio de Dermatología, Hospital General Universitario de Alicante – ISABIAL, Alicante, Spain

Received 31 August 2017; accepted 30 October 2017

Available online 17 January 2018

KEYWORDS

Tattoo;
Ink;
Allergic contact dermatitis;
Tattooing/adverse effects

Abstract

Introduction: Tattooing has become a popular practice in western countries, particularly among younger populations. Tattoos, however, can cause complications, such as infections, allergic or foreign-body reactions, and even systemic inflammatory responses.

Patients and methods: We conducted a retrospective study of all patients seen for tattoo-related complications at our skin allergy unit between January 2002 and December 2016.

Results: We studied 23 patients. Nine of these experienced early complications, all related to infection. The other 14 patients developed late reactions. Ten were diagnosed with probable allergic contact dermatitis to ink, but the suspect allergen was identified in just 3 cases and confirmed in just 1 of these. There were 2 cases of cutaneous sarcoidosis, 1 case of foreign body granuloma, and 1 case of neuropathy.

Conclusions: Complications resulting from tattoos are relatively common dermatology complaints. Drawing from our experience, we propose a diagnostic algorithm designed to guide dermatologists in evaluating different reactions to tattoos and prescribing appropriate treatment.

© 2017 Elsevier España, S.L.U. and AEDV. All rights reserved.

[☆] Please cite this article as: González-Villanueva I, Silvestre Salvador J. ¿Qué procedimientos diagnósticos deberíamos realizar ante una sospecha de reacción alérgica a un tatuaje? Propuesta basada en nuestra casuística. Actas Dermosifiliogr. 2018;109:162–172.

* Corresponding author.

E-mail address: jolairis@gmail.com (I. González-Villanueva).

PALABRAS CLAVE

Tatuaje;
Tinta;
Dermatitis de
contacto alérgica;
Complicaciones del
tatuaje

¿Qué procedimientos diagnósticos deberíamos realizar ante una sospecha de reacción alérgica a un tatuaje? Propuesta basada en nuestra casuística**Resumen**

Introducción: Los tatuajes se han convertido en una práctica muy popular en los países occidentales, sobre todo entre los más jóvenes. Las complicaciones asociadas a esta técnica incluyen procesos infecciosos, alérgicos, reacciones a cuerpo extraño e incluso procesos inflamatorios sistémicos.

Pacientes y métodos: Se ha realizado un estudio retrospectivo de todos los pacientes que acudieron a la consulta de Alergia cutánea por manifestar complicaciones en un tatuaje desde enero de 2002 a diciembre de 2016.

Resultados: Se han incluido a 23 pacientes. De ellos, 9 presentaron complicaciones de forma precoz y en todos ellos la etiología fue infecciosa. De los 14 pacientes con reacciones tardías, 10 fueron diagnosticados de probable dermatitis de contacto alérgica a la tinta, sin embargo solo en 3 de los casos se pudo apuntar al alérgeno probablemente culpable y tan solo en uno de ellos se pudo demostrar. Se detectaron dos casos de sarcoidosis cutánea, uno de reacción granulomatosa a cuerpo extraño, y un caso de reacción neuropática en una paciente.

Conclusiones: Las complicaciones asociadas a los tatuajes son un motivo de consulta relativamente frecuente en las consultas de Dermatología. Proponemos un algoritmo diagnóstico basado en nuestra casuística, que ayude a orientar las distintas reacciones a tatuaje y con ello a iniciar las medidas terapéuticas oportunas.

© 2017 Elsevier España, S.L.U. y AEDV. Todos los derechos reservados.

Introduction

Tattooing has been used to decorate the skin for different purposes since thousands of years ago. It is a very common practice in many cultures, and its popularity has increased in western countries. The number of reports of associated complications has increased in parallel, and recent publications indicate that the incidence of adverse reactions to permanent tattoos is approximately 2%.¹⁻³ The reactions include infections, acute and chronic inflammatory reactions, and flare-ups of skin complaints due to the isomorphic response. Benign and malignant tumors have also been reported on tattoos, although no causal relationship between the 2 phenomena has been established.^{4,5} Current Spanish legislation adopts the resolution of the Council of Europe ResAP (2008) on permanent tattoos, which establishes regulations stating that the packaging must show the conditions of use, date of minimum durability, batch number, and the list of ingredients (the Chemical Abstract Service or Color Index number, according to international nomenclature) and guarantee that the content is sterile. However, since most inks used in Spain are imported from Asia and the United States, they are not subject to this regulation.⁶

The objective of the present study was to describe the clinical characteristics of patients seen at a skin allergy clinic with a tattoo-related complication between January 2002 and December 2016. We also propose an algorithm for managing patients with a suspected allergic reaction to ink and discuss the yield of patch tests and the usefulness of patch testing with the ink itself.

Material and Methods

We performed a descriptive, retrospective study of all patients who were seen at the Skin Allergy Clinic of Hospital General Universitario de Alicante, Alicante, Spain with a tattoo-related complication. We excluded patients whose reaction was to a temporary tattoo. We recorded epidemiological and clinical variables, as well as the results of additional tests. We divided the cohort into 2 groups: patients who experienced early reactions (within the first month after the tattoo) (Table 1) and patients who experienced late reactions (more than 1 month after the tattoo) (Table 2). In addition, patients were grouped according to the clinical pattern observed based on the classification by Serup et al.⁵ Patients with a suspected allergic reaction to ink underwent patch testing, which was performed with the standard series of the Grupo Español de Investigación en Dermatitis de Contacto y Alergia Cutánea (Spanish Contact Dermatitis and Skin Allergy Research Group) or a specific textile series (Chemotechnique Diagnostics); in some cases, a specific metal series (Martí Tor) and the ink supplied by the patient were also used (Table 3).

Results

A total of 23 patients consulted for a tattoo-related skin problem from January 2002 to December 2016. Men accounted for 43.5% (n=10) and women for 56.5% (n=13). The mean age was 36 years (range, 19-58 years). Of the 7 patients who had previous tattoos (28%), only 1 had simultaneous complications on the oldest tattoo (Fig. 1).

Table 1 Epidemiological and Clinical Characteristics of Patients Who Experienced Early Reactions: Additional Tests and Final Diagnosis.

Early Reactions (≤ 1 mo)											
Sex	Age, y	Time Since Placement of the Tattoo	Site	Clinical Pattern	Homogeneous or Patchy Involvement	Color of the Ink	Previous Tattoos	Histology	Culture	Patch Tests	Diagnosis
Man	23	2 d	Right leg	Papulopustular	Homogeneous	Black	Yes	Lichenoid interface dermatitis	Yes, negative	Yes	Inflammatory reaction due to a batch of ink contaminated by <i>Pseudomonas aeruginosa</i>
Man	30	1 mo	Right leg	Eczematous plaque	Homogeneous	Black	No	Foreign body granuloma	Yes, positive for <i>Mycobacterium chelonae</i>	No	Infection by <i>Mycobacterium chelonae</i> present in a batch of contaminated ink
Woman	29	1 wk	Back	Eczematous plaque	Homogeneous	Black	No	Foreign body granuloma	Yes, positive for <i>Pseudomonas aeruginosa</i>	No	Infection by <i>Pseudomonas aeruginosa</i> present in a batch of contaminated ink
Man	32	1 wk	Right leg	Papulonodular	Localized	Black	No	Skin abscess	Yes, positive for <i>Pseudomonas aeruginosa</i>	No	Infection by <i>Pseudomonas aeruginosa</i> present in a batch of contaminated ink
Man	32	1 wk	Right arm	Eczematous plaque	Homogeneous	Black	No	Foreign body granuloma	Yes, negative	No	Granulomatous reaction, batch of ink contaminated by <i>Pseudomonas aeruginosa</i>

Table 1 (Continued)

Early Reactions (≤ 1 mo)											
Sex	Age, y	Time Since Placement of the Tattoo	Site	Clinical Pattern	Homogeneous or Patchy Involvement	Color of the Ink	Previous Tattoos	Histology	Culture	Patch Tests	Diagnosis
Man	41	1 mo	Left arm	Eczematous plaque	Homogeneous	Black	No	Lichenoid interface dermatitis	No	No	Inflammatory reaction due to a batch of ink contaminated by <i>Pseudomonas aeruginosa</i>
Man	33	1 mo	Right arm	Eczematous plaque	Homogeneous	Black	No	Foreign body granuloma	Yes, negative	No	Granulomatous reaction caused by a batch of ink contaminated by <i>Pseudomonas aeruginosa</i>
Woman	35	1 mo	Left leg	Eczematous plaque and area with a necrotic nodule	Homogeneous	Black	No	Foreign body granuloma	Yes, positive for <i>Pseudomonas aeruginosa</i>	No	Infection by <i>Pseudomonas aeruginosa</i> present in a batch of contaminated ink
Man	40	3 wks	Scapula	Ulcerative-necrotic	Localized	Black	Yes	No	Yes, positive for <i>Staphylococcus aureus</i>	No	Pyoderma caused by <i>Staphylococcus aureus</i>

Table 2 Epidemiological and Clinical Characteristics of Patients Who Experienced Late Reactions.

Late Reactions (>1 mo)											
Sex ^a	Age, y	Time Since Placement of the Tattoo	Site	Clinical Pattern	Homogeneous or Patchy Involvement	Color of the Ink	Previous Tattoos	Histology	Culture	Patch Tests	Diagnosis
Man ¹	19	1.5 mo	Left forearm	Eczematous plaque	Homogeneous	Red	Yes	Lichenoid interface dermatitis	No	Yes	Probable ACD to red ink
Man ²	27	3 mo	Right leg	Papular-lichenoid	Homogeneous	Black	No	Lichenoid interface dermatitis	No	Yes	ACD to shellac probably present in black ink
Woman ³	19	3 mo	Dorsum of left foot	Eczematous plaque	Homogeneous	Red, green, yellow	No	Granulomatous reaction to exogenous pigment	No	Yes	Probable ACD to C111740 present in inks
Woman ⁴	36	10 y	Intermammary region	Papular-lichenoid	Homogeneous	Black	Yes	Lichenoid interface dermatitis	No	Yes	Possible ACD to tattoo ink
Woman ⁵	46	10 mo	Left leg	Ulcerative-necrotic	Homogeneous	Blue	No	Lichenoid interface dermatitis	No	Yes	Probable ACD to cobalt chloride, likely present in tattoo ink
Woman ⁶	42	2 mo	Dorsum of the hand	Eczematous plaque	Homogeneous	Red	Yes	Lichenoid interface dermatitis	No	Yes	Probable ACD to red ink
Woman ⁷	48	3 y	Left ankle	Eczematous plaque	Homogeneous	Red	No	Pseudolymphomatous reaction	No	Yes	Possible ACD to tattoo ink
Woman ⁸	28	1 y	Left ankle	Eczematous plaque	Homogeneous	Magenta	Yes	Lichenoid interface dermatitis	No	Yes	Probable ACD to tattoo ink

Table 2 (Continued)

Late Reactions (>1 mo)											
Sex ^a	Age, y	Time Since Placement of the Tattoo	Site	Clinical Pattern	Homogeneous or Patchy Involvement	Color of the Ink	Previous Tattoos	Histology	Culture	Patch Tests	Diagnosis
Woman ⁹	36	18 y	Left thigh	Papular-lichenoid	Homogeneous	Blue	No	Lichenoid interface dermatitis	No	Yes	Probable ACD to tattoo ink
Woman	32	18 y	Right shoulder	Eczematous plaque	Homogeneous	Black	No	Lichenoid interface dermatitis	No	No	Possible ACD to tattoo ink
Woman	30	10 y	Inframammary region	Papular-lichenoid	Homogeneous	Black	No	Normal skin	No	No	Neuropathic reaction caused by tattoo
Woman	58	6 mo	Lips	Ulcerative-necrotic	Homogeneous	Red	No	Granulomatous reaction, with presence of sarcoid granulomas	No	No	Cutaneous sarcoidosis
Man	27	13 y	Right leg	Papulonodular	Localized	Black	No	Granulomatous reaction, with presence of sarcoid granulomas	No	No	Sarcoidosis
Woman	39	2 mo	Back	Papular-lichenoid	Homogeneous	Black	Yes	Granulomatous reaction to exogenous pigment	No	No	Foreign body granuloma

Abbreviation: ACD, allergic contact dermatitis.

^a The superscript index number indicates the corresponding patient in Table 3.

Table 3 Results of Patch Tests.

Case	Standard Series	Metal Series	Textile Series	Own Ink
1	Nickel sulfate ++ (PastR)	No	Negative	Negative
2	Shellac ++ (PresR) (cosmetics series) Limonene ++ (UR)	No	Negative	Positive
3	Negative	No	Negative	Negative
4	Nickel sulfate ++ (PastR)	No	Negative	No test
5	Nickel sulfate ++ (PastR) Cobalt chloride ++ (PresR)	Beryllium chloride ++ (PastR), palladium chloride ++ (PastR)	Negative	No test
6	Negative	Negative	Negative	Negative
7	Nickel sulfate ++ (PastR) Palladium chloride ++ (UR)	No	No	No test
8	Negative	Negative	Negative	No test
9	Nickel sulfate ++ (PastR) Thiomersal ++ (UR) Limonene ++ (UR) Linalool ++ (UR)	Negative for titanium dioxide	Negative	No test

Abbreviations: PastR past relevance; PresR present relevance; UR unknown relevance.

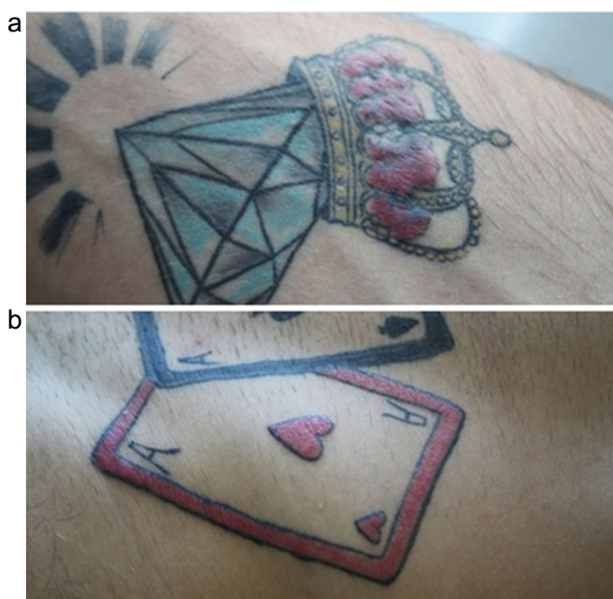


Figure 1 A, Reaction in the form of an eczematous plaque on a red tattoo placed 1.5 months earlier. B) Simultaneous reaction on a red tattoo placed 2 years earlier.

Onset of symptoms was within the first month of having the tattoo in 9 patients (39%), in whom the initial suspicion was infection. Between November 2004 and April 2005, we saw 8 patients who had been tattooed with black ink during the month before the visit by the same tattooist. Subsequent culture of samples from 7 of these patients revealed *Pseudomonas aeruginosa* in 3 cases. We therefore performed an exhaustive epidemiological study, which revealed a cutaneous inflammatory reaction to the tattoo owing to a batch of black ink that was contaminated by *P aeruginosa*. One of the patients tattooed with the contaminated ink was coinfecting with *Mycobacterium chelonae*, which was isolated in

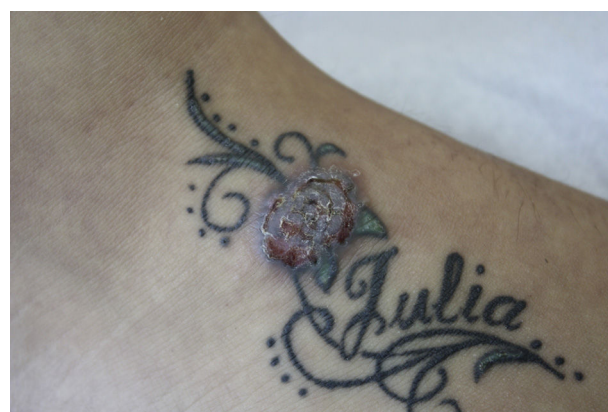

Figure 2 Eczematous reaction in the green, yellow, and red areas. The 3 inks shared the pigment CI11740: Pigment yellow 65. The color in this figure can only be fully appreciated in the electronic version of the article.

culture. The remaining patient was diagnosed with pyodermitis caused by *Staphylococcus aureus*, with isolation of the microorganism in culture and compatible symptoms. In our study, early reactions on tattoos were caused by infection. All 8 patients underwent skin biopsy, which revealed the most common histologic pattern to be foreign body granuloma.

We included 14 patients with late reactions. Red ink was the problem color in 6 cases (42.85%), black ink in 5 (35.7%), and blue ink in 2 (14.2%). Only 1 patient experienced a reaction affecting 3 colors simultaneously (yellow, green, and red). The 3 inks shared the pigment CI11740 (pigment yellow 65: 4-methoxy-2-nitrophenyl-N-2-methoxyphenyl-3-oxo-butyramide), which could be the culprit substance (Fig. 2).

Of the clinical patterns observed in reactions to a tattoo proposed by Serup et al.,⁵ the most prevalent in our

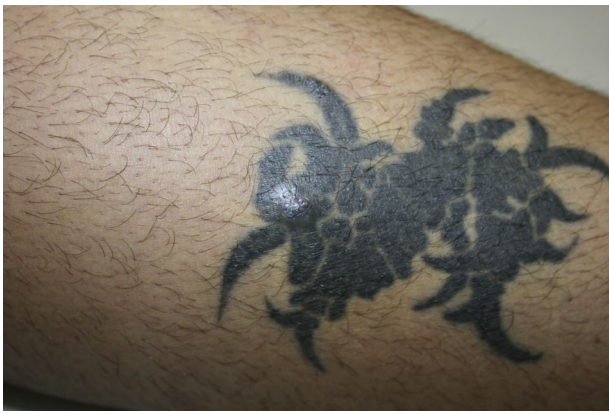

Figure 3 Papulonodular pattern limited to an area of the tattoo. Histology compatible with cutaneous sarcoidosis.

series were eczematous plaque (n=6, 42.8%) and a lichenoid-papular pattern (n=4, 28.5%), which were finally associated with a probable diagnosis of allergic contact dermatitis to the ink. An ulcerative-necrotic pattern was observed in 2 patients (14.28%), who had been diagnosed with allergic contact dermatitis to ink in one case and cutaneous sarcoidosis in the other. One patient presented a papulonodular pattern that affected a specific area of the tattoo but spared the remainder of the tattooed skin and was diagnosed as cutaneous sarcoidosis (Fig. 3). Another patient complained of pruritus and dysesthesia on a tattoo in black ink that had been placed 10 years previously; we interpret this finding as a neuropathic pattern, since the biopsy revealed no pathologic findings. Skin biopsies were performed in all cases. In the 10 patients with a probable allergic reaction to the ink color, histopathology revealed lichenoid interface dermatitis in 8 cases (80%). As for the remaining 20%, we observed a pseudolymphomatous pattern in one case and foreign body granuloma in the other. Biopsy confirmed the diagnosis of cutaneous sarcoidosis in 2 of the late-onset cases.

Patch testing was performed in 9 patients whose clinical and histopathologic data were compatible with allergic contact dermatitis to tattoo ink. The standard series was applied, and in some cases the specific textile series and the specific metal series were also applied. Nickel sulphate was the most frequently positive substance (n=4, 44.4%), and its relevance was past in all cases. One patient tested positive for cobalt chloride (++) , palladium chloride (++) , and beryllium chloride (++) . Given that the culprit ink was blue, relevance was thought to be probable for the cobalt chloride patch and unknown for the remaining positive patches. The metal series was used in 4 cases (44.4%), and the results were negative with unknown relevance. The specific textile series was applied in 8 patients (88%), and the results were negative in all cases. In 4 patients (44.4%), patch testing with the ink brought by the patient yielded a positive result in only 1 case.

Discussion

Tattooing often exposes the skin to foreign bodies that can potentially induce a response.⁷ We can classify reactions as early (occurring within the first month after the tattoo) and

late (occurring more than 1 month after the tattoo). We propose a diagnostic algorithm based on this classification and on our clinical experience (Fig. 4).

The most frequent early complications are transient inflammatory reactions caused by the injury resulting from injection of ink into the skin. These usually occur during the first weeks after the tattoo is placed and do not generally require medical or dermatological attention, since tattooists themselves manage them. However, a potential infectious origin should be borne in mind in the case of an early reaction. Infection by microorganisms can occur through contact with nonsterile material, performance of the procedure under unsanitary conditions, and the use of contaminated ink or water. A recent study showed that 10% of marketed inks are contaminated with pathogenic bacteria and that there are no regulations to guarantee the sterility of ink in Spain.⁸ Clinical manifestations indicative of infection include pain, increased local temperature, suppuration, and ulceration. In our study, 6 of the patients who were infected through contaminated ink had atypical manifestations, with eczematous plaques (Fig. 5). In many cases, the histopathology findings were compatible with foreign body granuloma; abscess or abundant inflammatory infiltrate of polynuclear cells was observed in 3 cases, despite being an expected finding. We obtained negative cultures in 3 of the patients who had been tattooed with ink from the contaminated batch. This finding can be explained by the fact that people who have a tattoo are generally young and in good health, with sufficient immunity to protect them against the microorganisms involved.^{9,10}

Therefore, in any patient who presents with an early reaction in the area of the tattoo, we believe it is essential to culture the purulent secretion and start empiric antibiotic therapy if the reaction is clinically indicative of infection. If the patient's progress is poor, a biopsy will be necessary for the histopathology and microbiology workup (culture for bacteria and mycobacteria). It would be interesting to perform culture to rule out contamination if a sample of the ink used is available. If the patient presents an early reaction, with no signs of infection, we recommend starting treatment with topical corticosteroids. If the reaction is refractory to treatment, we recommended performing a biopsy.

Late complications are those that develop months or even years after the tattoo. A biopsy is essential in all such cases to rule out infections with late manifestations or even systemic infections. Furthermore, it would help us to make a diagnosis based on histologic patterns.

According to the literature, the presence of noninfectious granulomas is uncommon; however, in our series, this pattern was observed in 2 patients, probably because the particles of pigment that are deposited in the dermis are identified as microscopic foreign bodies.¹¹⁻¹³ Such a reaction should lead us to rule out systemic granulomatous disease. Patch testing should be ordered in cases where the symptoms point to an allergic reaction.

The pseudolymphomatous pattern is characterized by a dense lymphocytic infiltrate, which was shown to be polyclonal in the immunohistochemical evaluation. The cause of this type of immune response is unknown, although chronic antigenic stimulation is thought to be responsible.^{13,14} We propose starting treatment with topical corticosteroids for such reactions. If the lesion persists and clinical

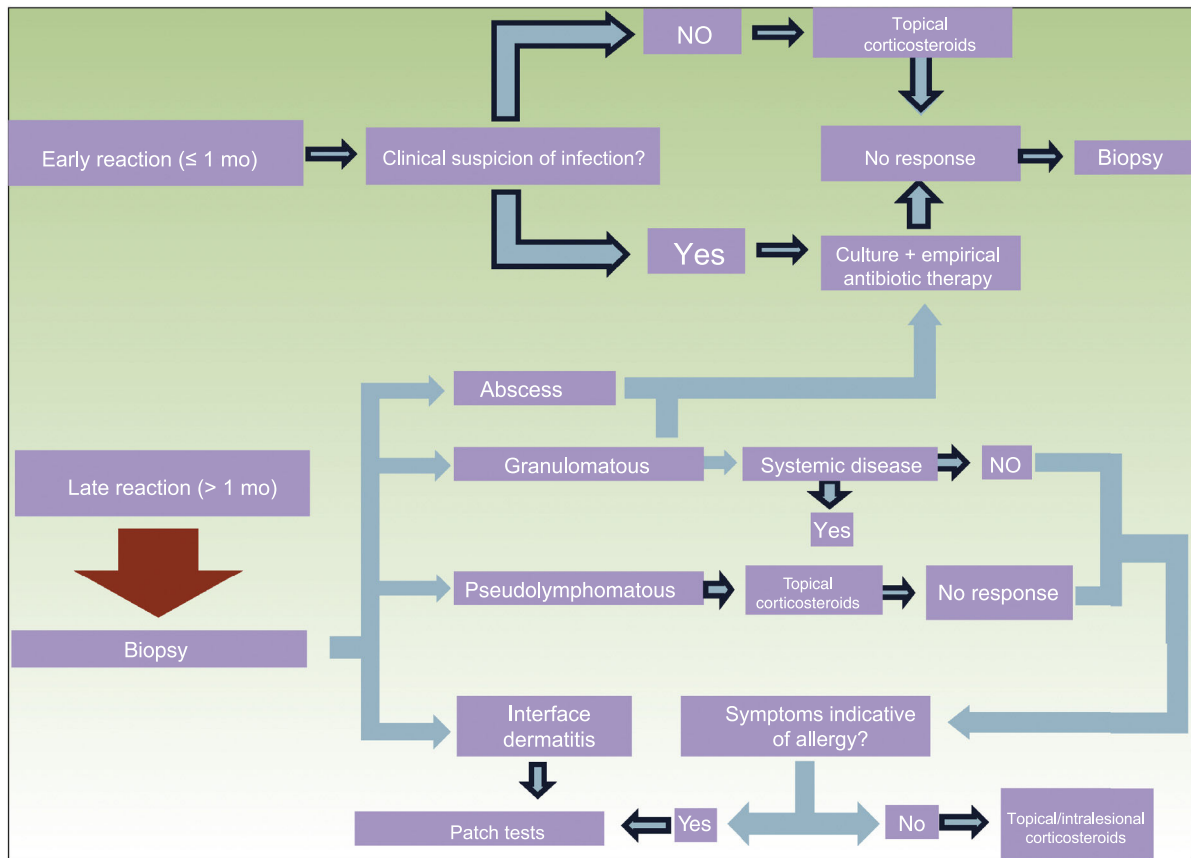


Figure 4 Diagnostic algorithm. Although topical or intralesional corticosteroids are considered the first line of treatment, other valid options include Q-switched laser, carbon dioxide and erbium ablative lasers, and surgery.

manifestations compatible with an allergic reaction appear, we should consider using patch tests.

Lichenoid interface dermatitis was the most frequent histologic pattern in the late reactions and was associated with allergic reactions. This inflammatory infiltrate of the papillary dermis and basal layer of the epidermis is composed of mononuclear cells and macrophages loaded with intracellular pigment. Eosinophils are not a constant finding.¹⁴ In our experience, this histologic pattern was the most frequent in cases of probable allergic reaction. Allergic reactions to ink are not common. Their onset is usually late, since they normally result from primary sensitization. Once initiated, the reaction is permanent and does not usually respond to topical corticosteroids. Three clinical patterns that point to allergic reaction to ink were recently reported, although they are not specific. The 3 patterns are plaque-like, hyperkeratotic, and ulcerative-necrotic.⁵ In the sample we report, we were able to show a different pattern that also points to allergic contact dermatitis, namely, a lichenoid-papular pattern involving nonconfluent pruriginous papules arranged homogeneously on specific areas of color in the tattoo but that do not affect the other colors (Fig. 6). In the present series, the eczematous plaque pattern was the most common, although the lichenoid-papular pattern was also observed in 3 patients, probably because the pigment is injected into the dermis and does not come into direct contact with the epidermis; therefore, the clinical and histologic reaction may differ from the typical manifestations

of contact dermatitis. We propose that both clinical patterns point to an allergic reaction. Furthermore, the lesions are usually monomorphic and uniform, affecting all the areas tattooed with the problem color. Patch tests are sometimes ordered for patients with a late reaction that does not affect the whole area tattooed with the problem color; therefore, by definition, the reaction is not an allergic reaction to ink and the yield of the tests is zero. The appearance of identical skin manifestations in areas of the same color on previous tattoos supports an allergic reaction. We observed this phenomenon in a patient with allergic contact dermatitis to red ink, which, according to data from the literature, is the color that most frequently causes allergic reactions. In our experience, there are no differences between reactions to red ink and reactions to black ink, probably because black tattoos are more frequent.

When a patient with a suspected allergic reaction to a tattoo is assessed, most skin allergy units apply their national standard series, a specific metal series, and a textile colorant series, as well as the problem ink. The standard metal series is used because inks can contain pigments manufactured from inorganic metal salts. However, metal salts are being replaced by organic molecules, such as azo pigments and quinacridones.¹⁵⁻¹⁷ The specific battery for textile colorants includes several pigments, although we cannot be certain that it contains those used in the tattooed patient. The usefulness of patch tests in this context is not completely clear. In most cases the result is

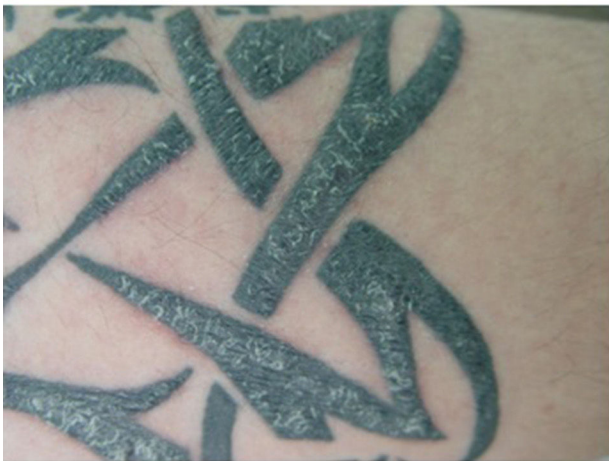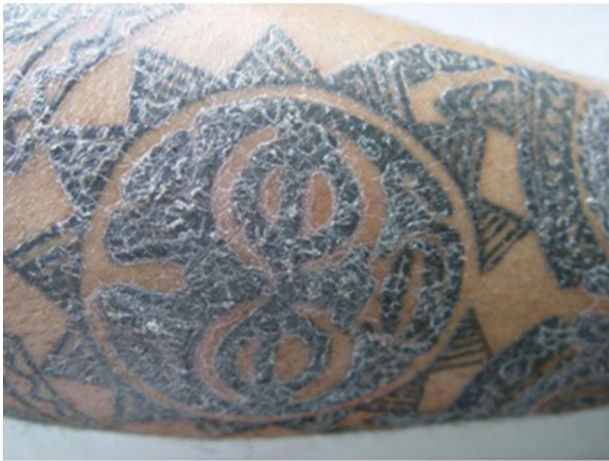


Figure 5 “Atypical” skin reaction in 2 patients tattooed with ink from a batch contaminated with *Pseudomonas aeruginosa*.

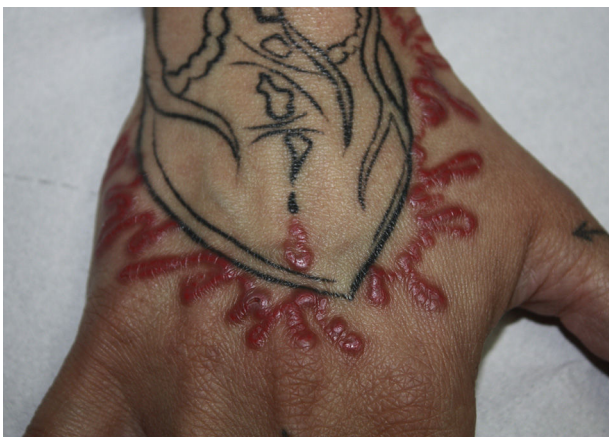

Figure 6 Papular-lichenoid pattern in a patients with a probable allergic reaction to red tattoo ink. The color in this figure can only be fully appreciated in the electronic version of the article.

negative or inconsistent, and cases with positive results and an appropriate clinical correlation are exceptional.¹⁸ This lack of sensitivity and specificity of patch tests generates several hypotheses. Some authors propose that negative results could be attributed to poor penetration of the skin by

the ink used in the tests. Others state that the real allergen is not present in its native form in inks and believe that these are formed in the dermis after a haptization process. Sunlight could play a role in the process, thus explaining photosensitivity in reactions to tattoos.^{18–21}

Despite the data reported above, we believe that patch testing should be used in all patients with a late reaction to a tattoo, compatible symptoms, and biopsy-proven lichenoid interface dermatitis. In such cases, only the ink and the standard series should be used, since neither the metal series nor the textile series has proven useful.¹⁸ Conceptually, intradermal tests would be more specific for the assessment of these patients, although they are not without risks and their use is not ethical.^{22–24} We hope that in the future, more information on the composition of the inks will enable us to perform patch testing to detect allergens with greater accuracy and thus demonstrate the compound responsible for allergic contact dermatitis.

Conflicts of Interest

The authors declare that they have no conflicts of interest.

References

1. Cruz FAM, Lage D, Frigério RM, Zaniboni MC, Arruda LHF. Reactions to the different pigments in tattoos: A report of two cases. *An Bras Dermatol*. 2010;85:708–11.
2. Laumann A, Derik A. Tattoos and body piercings in the United States: a national data set. *J Am Acad Dermatol*. 2006;55:413–21.
3. Simunovic C, Shinohara MM. Complications of decorative tattoos: Recognition and management. *Am J Clin Dermatol*. 2014;15:525–36.
4. Mataix J, Silvestre JF. Reacciones cutáneas adversas por tatuajes y piercings. *Actas Dermosifiliogr*. 2009;100:643–56.
5. Serup J, Carlsen KH, Sepehri M. Tattoo complaints and complications: diagnosis and clinical spectrum. *Curr Probl Dermatol*. 2015;48:48–60.
6. Hogsberg T, Saunte DM, Frimodt-Moller N, Serup J. Microbial status and product labeling of 58 original tattoo inks. *J Eur Acad Dermatol Venereol*. 2013;27:73–80.
7. Bassi A, Campolmi P, Cannarozzo G, Conti R, Brusolino N, Gola M, et al. Tattoo-associated skin reaction: the importance of an early diagnosis and proper treatment. *Biomed Res Int*. 2014;2014:354–608.
8. Hogsberg T, Saunte DM, Frimodt-Moller N, Serup J. Microbial status and products labeling of 58 original tattoo inks. *J Eur Acad Dermatol Venereol*. 2013;27:73–80.
9. Philips RC, Hunter-Ellul LA, Martin JE, Wilkerson MG. *Mycobacterium fortuitum* infection arising in a new tattoo. *Dermatol Online J*. 2014;20:6.
10. Kennedy BS, Bedard B, Younge M, Tuttle D, Ammerman E, Ricci J, et al. Outbreak of *Mycobacterium chelonae* infection associated with tattoo ink. *N Engl J Med*. 2012;367:1020–4.
11. Ravits HG. Allergic tattoo granuloma. *Arch Dermatol*. 1962;86:287–9.
12. Ro YS, Lee CW. Granulomatous tissue reaction following cosmetic eyebrow tattooing. *J Dermatol*. 1991;18:52–5.
13. Vagefi MR, Dragan L, Hughes SM, Klippenstein KA, Seiff SR, Woog JJ. Adverse reactions to permanent eyeliner tattoo. *Ophthalm Plast Reconstr Surg*. 2006;22:48–51.

14. Høgsberg T, Thomsen BM, Serup J. Histopathology and immune histochemistry of red tattoo reactions. *Skin Res Technol*. 2015;21:449–58.
15. Serup J, Kluger N, Bäuml W. Tattoo inks: legislation, pigments, metals and chemical analysis. *Curr Probl Dermatol*. 2015;48:152–7.
16. Forte G, Petrucci F, Cristaudo A, Bocca B. Market survey on toxic metals contained in tattoo inks. *Sci Total Environ*. 2009;407:5997–6002.
17. Gaudron S, Ferrier-Le Bouëdec MC, Franck F, Dincan M. Azo pigments and quinacridones induce delayed hypersensitivity in red tattoos. *Contact dermatitis*. 2015;72:97–105.
18. Serup J, Hutton Carlsen K. Patch test study of 90 patients with tattoo reactions: negative outcome of allergy patch test to baseline batteries and culprit inks suggests allergens are generated in the skin through haptization. *Contact Dermatitis*. 2014;71:255–63.
19. Hutton Carlsen K, Serup J. Photosensitivity and photodynamic events in black, red and blue tattoos are common: A 'Beach study'. *J Eur Acad Dermatol Venereol*. 2014;28:231–7.
20. Vasold R, Naarmann N, Ulrich H, Fischer D, König B, Landthaler M, et al. Tattoo pigments are cleaved by laser light – the chemical analysis in vitro provides evidence for hazardous compounds. *Photochem Photobiol*. 2004;80:185–90.
21. Engel E, Spannberger A, Vasold R, König Landthaler M, Bäuml W. Photochemical cleavage of a tattoo pigment by UVB radiation or natural sunlight. *J Dtsch Dermatol Ges*. 2007;5:583–9.
22. González Villanueva I, Silvestre JF. Reacciones alérgicas frente a las tintas de los tatuajes. In: Muños Borrás D, editor. *Tratado sobre los tatuajes: claves para su eliminación con láser*. Buenos Aires: Ediciones Journal; 2017. p. 69–78.
23. Tresukosol P, Ophaswongse S, Kullavanijaya P. Cutaneous reaction to cosmetic lip tattooing. *Contact Dermatitis*. 1997;36:176–7.
24. Steinbrecher I, Hemmer W, Jarisch R. Adverse reaction to the azo dye Pigment Red 170 in a tattoo. *J Dtsch Dermatol Ges*. 2004;1007–8.