

There have also been reports of granulomatous infiltrates, which can appear alongside specific atypical tumor cells, both in Hodgkin and non-Hodgkin lymphomas and in some solid tumors.<sup>3,4</sup> In our patient, we were able to exclude this possibility with a high level of certainty given the rapid resolution of the lesion (typical in localized GA), the characteristic clinical findings, and the absence of concomitant disease. The association between GA and malignant tumors is probably fortuitous.<sup>5</sup> There have also been reports of GA coexisting with lymphoid disorders, such as adult T-cell leukemia/lymphoma,<sup>3,6</sup> acute myeloid leukemia, and primary cutaneous small to medium CD4<sup>+</sup> T-cell lymphoma.<sup>4</sup> Sarcoidosis and lymphoma could also be included in this second group, which we could consider to be nonspecific manifestations of lymphomas. A diagnosis of pseudolymphomatous GA should therefore be based on the integration of clinical and pathologic findings and be supported by immunohistochemical studies to rule out lymphoma and other tumors, particularly if atypical cells are observed. Serology and *Borrelia* polymerase chain reaction detection should also be performed to rule out borreliosis in endemic areas or in patients with compatible clinical manifestations. A diagnosis of pseudolymphomatous GA must be contemplated in cases of interstitial GA or GA with necrobiotic granulomas when a dense superficial and deep lymphoid infiltrate is observed. Pseudolymphomatous GA is rare and only a few cases have been reported in the literature. Familiarity with this entity is important to prevent overtreatment and unnecessary tests.

### Conflicts of Interest

The authors declare that they have no conflicts of interest.

### References

1. Cota C, Ferrara G, Cerroni L. Granuloma annulare with prominent lymphoid infiltrates ('pseudolymphomatous' granuloma annulare). *Am J Dermatopathol*. 2012;34:259–62.
2. Piette EW, Rosenbach M. Granuloma annulare: Clinical and histologic variants, epidemiology, and genetics. *J Am Acad Dermatol*. 2016;75:457–65.
3. Kawakami T, Kawanabe T, Soma Y. Granuloma annulare-like skin lesions as an initial manifestation in a Japanese patient with adult T-cell leukemia/lymphoma. *J Am Acad Dermatol*. 2009;60:848–52.
4. Boussault P, Tucker ML, Weschler J, Riaux A, Bervas-Quenehervé C, Quist D, et al. Primary cutaneous CD4<sup>+</sup> small/medium-sized pleomorphic T-cell lymphoma associated with an annular elastolytic giant cell granuloma. *Br J Dermatol*. 2009;160:1126–8.
5. Piette EW, Rosenbach M. Granuloma annulare: Pathogenesis, disease associations and triggers, and therapeutic options. *J Am Acad Dermatol*. 2016;75:467–79.
6. Kuramoto Y, Watanabe M, Tagami H. Adult T cell leukemia accompanied by annular elastolytic giant cell granuloma. *Acta Derm Venereol*. 1990;70:164–7.

M. Llamas-Velasco,<sup>a,\*</sup> A. Urquina-Renke,<sup>b</sup> A. Pérez-Plaza,<sup>a</sup> J. Fraga<sup>b</sup>

<sup>a</sup> *Departamento de Dermatología, Hospital Universitario de la Princesa, Madrid, España*

<sup>b</sup> *Departamento de Anatomía Patológica, Hospital Universitario de la Princesa, Madrid, España*

\* Corresponding author.

E-mail address: [mar.llamasvelasco@gmail.com](mailto:mar.llamasvelasco@gmail.com)

(M. Llamas-Velasco).

29 July 2017 22 October 2017

1578-2190/

© 2018 Elsevier España, S.L.U. and AEDV. Published by Elsevier España, S.L.U. All rights reserved.

## Tuberous Sclerosis Complex Associated with Hemihypertrophy and Combined Vascular Malformations<sup>☆</sup>



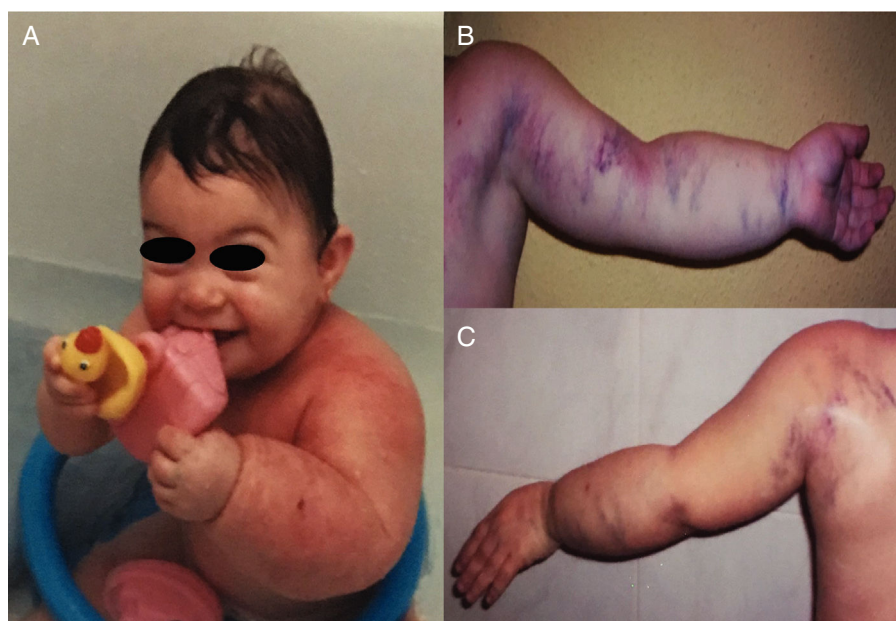### Complejo de esclerosis tuberosa asociado a hemihipertrofia y malformaciones vasculares combinadas

To the Editor:

Tuberous sclerosis complex (TSC), an autosomal dominant disorder with variable expressivity, is caused by mutations in the tumor suppressor genes *TSC1* and *TSC2*, which encode hamartin and tuberin proteins, respectively.<sup>1–3</sup> TSC manifests with the formation of hamartomas in multiple organs, mainly the skin, central nervous system, kidneys, lungs, and heart.<sup>1–3</sup> Vascular anomalies associated with overgrowth, hypertrophy, or gigantism are uncommon in TSC.<sup>2</sup> We report the case of a TSC patient with congenital hypertrophy and combined vascular malformations of the left arm.

A 17-year-old adolescent girl, who was diagnosed with TSC at 9 years of age, was followed from birth for hypertrophy and combined vascular malformations of the left arm. The diagnosis of TSC was confirmed upon identification of the c.235G>T mutation in *TSC2* in heterozygosis, in the absence of any clinical signs of the disease. The patient's mother carried the same mutation and presented clinical signs of TSC. A physical examination carried out

<sup>☆</sup> Please cite this article as: Flores-Terry MÁ, Alegre-Sánchez A, Boixeda P, López-Gutiérrez JC. Complejo de esclerosis tuberosa asociado a hemihipertrofia y malformaciones vasculares combinadas. *Actas Dermosifiliogr*. 2019;110:164–167.

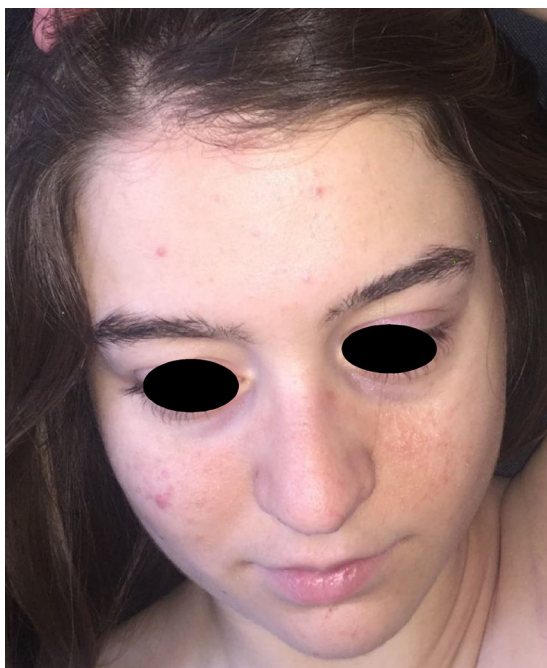

**Figure 1** A, Limb asymmetry with overgrowth of the left arm. B and C, Capillary and venous vascular malformations on the anterior and posterior aspects of the arm.

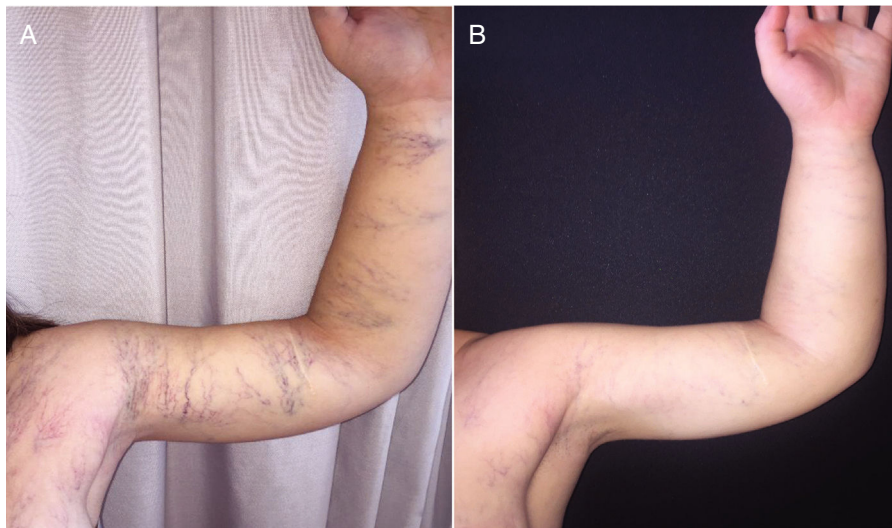
during the first months of life revealed telangiectatic and purpuric vascular lesions (Fig. 1A) accompanied by multiple visible capillaries and venous vessels (Fig. 1B and C) on the left arm, the diameter of which was enlarged. No skin lesions indicative of TSC were observed. Doppler ultrasound performed at 20 days of age revealed no alterations of the arterial or deep venous systems. At 4 months of age, a deep skin biopsy, which included muscle, showed enlargement of the blood vessels in the dermis and subcutaneous

tissue suggestive of capillary and venous malformations, in addition to ectasia of the lymphatic vessels. Immunohistochemistry revealed positive staining for D2-40 and negative staining for GLUT1 and WT1. No alterations in muscle tissue were observed, and atypia and mitotic figures were absent. Hypopigmented macules on the thighs, facial angiofibromas (Fig. 2), and periungual fibromas on the hands and feet became more evident once the patient reached 8 years of age, and were accompanied by Shagreen patches on the trunk that were compatible with TSC, which was confirmed by genetic study. A general physical examination and imaging techniques including conventional radiology, abdominal and pelvic ultrasound, brain magnetic resonance imaging, and cardiac ultrasound revealed no systemic alterations. The patient was diagnosed with predominantly lymphatic combined vascular malformation associated with TSC caused by *TSC2* mutation. At age 11 years the patient began treatment with oral rapamycin ( $0.8 \text{ mg/m}^2/12 \text{ h}$ ) for 6 months. Because no decrease in the circumference of the affected arm was observed and the patient showed no systemic signs, rapamycin treatment was discontinued. Since the age of 14 years the patient's superficial capillary malformations have been treated with pulsed dye laser (PDL) ( $10 \text{ mm}$ ,  $10 \text{ ms}$ ,  $6 \text{ J/cm}^2$ ), and the superficial venous malformations have been treated with multiplex neodymium-doped yttrium aluminum garnet (Nd:YAG) laser (PDL [ $10 \text{ mm}$ ,  $10 \text{ ms}$ ,  $6 \text{ J/cm}^2$ ] followed after a 1-s delay by Nd:YAG laser [ $10 \text{ mm}$ ,  $15 \text{ ms}$ ,  $70 \text{ J/cm}^2$ ]) (Fig. 3A and B).

The phosphatidylinositol 3-kinase (PI3K/AKT)/phosphatase and tensin homolog (PTEN)/mammalian target of rapamycin (mTOR) pathway is implicated in the pathogenesis of hamartomatous syndromes such as TSC, vascular anomalies, overgrowth, and malignant tumors.<sup>2,4-6</sup> mTOR, a kinase belonging to the phosphatidyl-3-inositol family, consists of 2 multiprotein complexes (mammalian target of rapamycin complex [mTORC]1 and mTORC2) and is involved



**Figure 2** Tuberous sclerosis complex patient with multiple facial angiofibromas.



**Figure 3** Patient at 16 years of age, before (A) and after (B) treatment of capillary and venous malformations with pulsed dye laser and multiplex neodymium-doped yttrium aluminum garnet (Nd:YAG) laser, respectively.

in the regulation of multiple processes associated with growth, cell differentiation, angiogenesis, and modulation of the inflammatory response.<sup>7</sup> The angiogenic activity of mTOR is mediated primarily via the translation and activation of hypoxia-inducible factor 1 (HIF-1), which in turn is implicated in VEGF expression in situations of cellular hypoxia and suppresses mTORC1 activity.<sup>7</sup> The fact that TSC is one of the diseases most clearly associated with dysregulation of the mTOR pathway explains the appearance of different types of vascular malformations in this disease, although these alterations are rarely reported.<sup>2</sup> Vascular anomalies described in TSC include angiomyolipomas, lymphatic malformations, and, less commonly, arterial anomalies (occlusion, stenosis, aneurysms), which are likely related to alterations of the vasa vasorum caused by hamartomas.<sup>2</sup> Lymphedema in TSC<sup>8</sup> may be the result of lymphatic malformations. It has been proposed that congenital and acquired lymphedema are more frequent in TSC.<sup>2</sup>

The involvement of an entire body segment, as in the present case, may be due to the loss of heterozygosity during early fetal development,<sup>2</sup> combined with the germinal mutation. Postzygotic mosaic mutations that affect cell signaling pathways regulating cell growth, apoptosis, or migration can give rise to regional alterations, in some cases accompanied by overgrowth, which can compromise the skin, subcutaneous tissue, muscle, bone, and/or nerves. In terms of severity, overgrowth can be variable, stable, or progressive.<sup>9</sup> When monitoring these patients, it should be borne in mind that alterations in these pathways can also increase the likelihood of developing various malignant tumors.<sup>2,4</sup>

In TSC patients, mTOR inhibitors such as rapamycin (sirolimus) have shown beneficial effects on neurological signs, but no clear effects on overgrowth and/or vascular malformations.<sup>2</sup> Good results have been reported in other patients with vascular malformations.<sup>10</sup> Further studies with better dose control and longer periods of administration are likely needed to determine its true efficacy. Blockade

of the mTOR pathway could play a fundamental role in the development of vascular lesions in TSC patients.

### Conflicts of Interest

The authors declare that they have no conflicts of interest.

### References

1. Jacks SK, Witman PM. Tuberous sclerosis complex: an update for dermatologists. *Pediatr Dermatol.* 2015;32:563–70.
2. Jenkins D, McCuaig C, Drolet BA, Siegel D, Adams S, Lawson JA, et al. Tuberous sclerosis complex associated with vascular anomalies or overgrowth. *Pediatr Dermatol.* 2016;33:536–42.
3. Ebrahimi-Fakhari D, Meyer S, Vogt T, Pfoehler C, Müller CSL. Dermatological manifestations of tuberous sclerosis complex (TSC). *J Dtsch Dermatol Ges.* 2017;15:695–700.
4. Klover PJ, Thangapazham RL, Kato J, Wang JA, Anderson SA, Hoffmann V, et al. Tsc2 disruption in mesenchymal progenitors results in tumors with vascular anomalies overexpressing Lgals3. *Elife.* 2017;6:e23202.
5. Tan W-H, Baris HN, Burrows PE, Robson CD, Alomari AI, Mulliken JB, et al. The spectrum of vascular anomalies in patients with PTEN mutations: implications for diagnosis and management. *J Med Genet.* 2007;44:594–602.
6. Perry B, Banyard J, McLaughlin ER, Watnick R, Sohn A, Brindley DN, et al. AKT1 overexpression in endothelial cells leads to the development of cutaneous vascular malformations in vivo. *Arch Dermatol.* 2007;143:504–6.
7. Salido-Vallejo R, Garnacho-Saucedo G, Vélez A. Elucidation of the mTOR pathway and therapeutic applications in dermatology. *Actas Dermosifiliogr.* 2016;107:379–90.
8. Geffrey AL, Shinnick JE, Staley BA, Boronat S, Thiele EA. Lymphedema in tuberous sclerosis complex. *Am J Med Genet.* 2014;164A:1438–42.
9. Nathan N, Keppler-Noreuil KM, Biesecker LG, Moss J, Darling TN. Mosaic disorders of the PI3K/PTEN/AKT/TSC/mTORC1 signaling pathway. *Dermatol Clin.* 2017;35:51–60.



10. Lackner H, Karastaneva A, Schwinger W, Benesch M, Sovinz P, Seidel M, et al. Sirolimus for the treatment of children with various complicated vascular anomalies. *Eur J Pediatr*. 2015;174:1579–84.

M.Á. Flores-Terry,<sup>a,\*</sup> A. Alegre-Sánchez,<sup>b</sup> P. Boixeda,<sup>b</sup> J.C. López-Gutiérrez<sup>c</sup>

<sup>a</sup> Servicio de Dermatología Médico-Quirúrgica y Venereología, Hospital General Universitario de Ciudad Real, Ciudad Real, España

<sup>b</sup> Servicio de Dermatología Médico-Quirúrgica y Venereología, Hospital Ramón y Cajal, Madrid, España  
<sup>c</sup> Servicio de Cirugía Pediátrica, Hospital Infantil La Paz, Madrid, España

\* Corresponding author.

E-mail address: [miguelterry85@hotmail.com](mailto:miguelterry85@hotmail.com) (M.Á. Flores-Terry).

1578-2190/

© 2018 Elsevier España, S.L.U. and AEDV. Published by Elsevier España, S.L.U. All rights reserved.

## Cutaneous Langerhans Cell Histiocytosis Presenting in Adulthood<sup>☆</sup>



### Histiocitosis de células de Langerhans cutánea de presentación en el adulto

To the Editor:

Langerhans cell histiocytosis (LCH) is a disease of clonal proliferation of immature Langerhans cells.<sup>1,2</sup> LCH can affect any organ,<sup>3</sup> occurs mainly in children, and is rare in adults. It is even rarer for it to be confined to the skin. We present 3 cases of adult-onset cutaneous LCH treated by surgical excision. No new lesions or systemic or other effects developed during follow-up.

**Case 1:** A 36-year-old man with no relevant medical history presented with an asymptomatic lesion that had appeared 2 months earlier. It was located on the external edge of the right eyebrow, and there were no associated symptoms. Physical examination showed it to be a papule 6 mm in diameter that was slightly erythematous, firm to the touch, and well defined (Fig. 1A). No other skin or mucosal lesions, palpable lymph nodes, or enlarged organs were detected. Histopathology of the excised tissue revealed a normal epidermis and a dense, nodular-type infiltrate (Fig. 2A) composed of dispersed cells with oval or kidney-shaped nuclei resembling coffee beans (Fig. 2B). The cells had a clear eosinophilic cytoplasm, corresponding to histiocytes. The infiltrate also contained necrotic areas, lymphocytes, and eosinophils. The mitotic index was very low. Immunohistochemical staining was positive for S100, CD1a (Fig. 2C and 2D) and CD207 (langerin) and negative for CD68. With these findings we made the diagnosis of LCH and ordered the following additional tests and imaging studies: complete blood count, coagulation screen, biochemistry, hormone profile, urine analysis, chest radiograph, abdominal ultrasound, and bone scans. All findings were normal. The final diagnosis was adult-onset LCH confined to the skin.

The patient has remained asymptomatic for 3 years. No new skin lesions, systemic symptoms, or related disorders have developed.

**Case 2:** A 33-year-old woman reported that an asymptomatic lesion had appeared on her left forearm 6 months earlier. It was an erythematous, infiltrated papule 5 mm in diameter (Fig. 1B). No enlarged lymph nodes or organs were found on physical examination. The lesion was removed, and the histopathologic findings, similar to those described in the first case, were consistent with a diagnosis of LCH. The results of additional tests were negative, and no new lesions or other clinical or analytic abnormalities have appeared in 2 years of follow-up.

**Case 3:** A 49-year-old woman presented with 2 erythematous, papular lesions 5 and 7 mm in diameter located on her right cheek and back. She also had a 9-mm plaque on the left side of her neck (Fig. 1C). No abnormalities were found on physical examination. Histopathology of an excised lesion was consistent with LCH, and so the remaining two were also removed. The histologic findings were the same. Additional studies gave no positive results. No new lesions or new conditions have developed in 3 years of follow-up.

LCH is a rare disease that is diagnosed mainly in children under the age of 15 years. Over that age, the estimated incidence is 5 to 9 cases per million population.<sup>1,4</sup> The spectrum of clinical presentations ranges widely,<sup>3–6</sup> varying according to the organ affected. In some cases lesions are solitary and resolve on their own, whereas in others the disease is disseminated and life-threatening.<sup>3,4,6,10</sup> The recent classification system of the Histiocyte Society refers specifically to a Langerhans (L) group of diseases.<sup>4</sup> Diagnosis is based on clinical, radiologic, and histopathologic findings, the last of which identifies a histiocytic infiltrate with the characteristic immunophenotypic features of LCH. The disease can affect any organ but is mainly found in bones, skin, hypophysis, liver, spleen, lymph glands, and lungs; less often, the central nervous (other than at the hypophysis) and hematopoietic systems are involved.<sup>3,4</sup>

The pathogenesis of LCH remains unclear.<sup>3,4,6,7</sup> The *BRAF* V600E mutation, which overstimulates the MAPK pathway, is present in half of patients with LCH. Smaller proportions of patients carry the *MAP2K1* MEK1 or *MAP3K1* ARF mutations. Mutations in the *PICK1* and *PICK3R2* genes, affecting the PIK3CA pathway, have also been described.<sup>4</sup> These findings support the theory that LCH is a neoplastic process.<sup>3,4</sup> However, the inflammatory component and the

<sup>☆</sup> Please cite this article as: Flores-Terry MA, Sanz-Trenado JL, García-Arpa M, Cortina-de la Calle MP. Cutaneous Langerhans Cell Histiocytosis Presenting in Adulthood. *Actas Dermosifiliogr*. 2019;110:167–169.