



ACTAS Derma-Sifiliográficas

Full English text available at
www.actasdermo.org



REVIEW

Geographic Tongue: What a Dermatologist Should Know[☆]



I.C. Ogueta,^{a,*} M.P. Ramírez,^b C.O. Jiménez,^b M.M. Cifuentes^a

^a Departamento de Dermatología, Facultad de Medicina, Pontificia Universidad Católica de Chile, Santiago de Chile, Chile

^b Escuela de Medicina, Facultad de Medicina, Pontificia Universidad Católica de Chile, Santiago de Chile, Chile

Received 7 June 2018; accepted 28 October 2018

Available online 18 April 2019

KEYWORDS

Benign migratory glossitis;
Inflammation;
Psoriasis;
Atopia

Abstract Geographic tongue, also known as benign migratory glossitis, is a benign chronic inflammatory condition of the tongue. It is characterized by erythematous lesions with filiform papillae atrophy, surrounded by white limited areas in the dorsal and lateral aspects of the tongue, producing a map-like aspect. These lesions change in size and shape with time, and are characterized by periods of exacerbation and remission without scarring. The cause is unknown, but multiple associations have been described, which will be discussed below.

© 2019 Elsevier España, S.L.U. and AEDV. Published by Elsevier España, S.L.U. All rights reserved.

PALABRAS CLAVE

Glositis migratoria benigna;
Inflamación;
Psoriasis;
Atopia

Lengua geográfica: ¿qué es lo que un dermatólogo debería saber?

Resumen La lengua geográfica, también conocida como glositis migratoria benigna, es una condición inflamatoria crónica benigna de la lengua. Se caracteriza por presentar lesiones eritematosas asociadas a una atrofia de papilas, las que están rodeadas por áreas blanquecinas bien delimitadas y localizadas predominantemente en la cara lateral y dorsal de la lengua, lo que da una imagen que recuerda un mapa geográfico. Estas lesiones pueden variar tanto de tamaño como de forma durante su evolución; además, presentan periodos de exacerbación y remisión sin dejar lesiones cicatriciales residuales. La causa de esta entidad sigue siendo desconocida, sin embargo, múltiples asociaciones se han descrito, las que son comentadas a continuación.

© 2019 Elsevier España, S.L.U. y AEDV. Publicado por Elsevier España, S.L.U. Todos los derechos reservados.

[☆] Please cite this article as: Ogueta IC, Ramírez MP, Jiménez CO, Cifuentes MM. Lengua geográfica: ¿qué es lo que un dermatólogo debería saber?. Actas Dermosifiliogr. 2019;110:341–346.

* Corresponding author.

E-mail address: iaogueta@uc.cl (I.C. Ogueta).

Introduction

Geographic tongue, also known as benign migratory glossitis, is a benign chronic inflammatory condition of the tongue. It is characterized by erythematous lesions with filiform papillae atrophy, surrounded by white limited areas in the dorsal and lateral aspects of the tongue, producing a map-like aspect. These lesions change in size and shape with time, and are characterized by periods of exacerbation and remission without scarring.¹

Prevalence in general population ranges from 1% to 2.5%.² Studies show a greater incidence in children between ages 4 and 5,³ and adults under 30 years.^{1,4,5} It tends to appear more in women than men, in a ratio of 1.5:1.⁴⁻⁶ Benign migratory glossitis is a condition to which many associations have been established, leading to the formulation of different theories about its possible etiology.

Etiology

Although the cause of geographic tongue is still unknown, most patients report family history of the condition, suggesting then a possible genetic predisposition. Prevalence of this condition among parents and siblings of these patients is significantly higher than general population. A study of Redman et al.⁷ in students of the University of Minnesota who suffered from geographic tongue analyzed family history, showing that prevalence of first-degree relatives with geographic tongue was significantly higher than in the control group (14.1% vs 4%). In relation to the studies about this condition's heritage, a polygenetic inheritance model has been proposed.^{7,8}

On the other hand, different factors and related diseases have been described to be related to this condition, such as allergies, hormonal alterations, pregnancy, juvenile diabetes, Reiter syndrome, psoriasis,⁹ Down syndrome, nutritional deficiencies, lichen planus, and also some drugs such as oral contraceptives, lithium and antihypertensives.^{1,10,11} An inverse relation has been observed with smoking.^{5,11} Some of the main conditions that have been related with geographic tongue are named in Table 1.

Psoriasis

Psoriasis is a chronic inflammatory skin disease, which can also compromise joints. Its cause is multifactorial, redound-

Table 1 Conditions that have been frequently associated with geographic tongue.

- Psoriasis	- Reiter syndrome
- Allergies	- Lichen planus
- Atopic dermatitis	- Drugs: Oral contraceptives, lithium, antihypertensives
- Nutritional deficiencies	- Genetic syndromes: Robinow syndrome, Down syndrome
- Infections	- Hormonal conditions: pregnancy among others
- Celiac disease	

ing in a pro-inflammatory environment that produces a defect in the normal cycle of epidermis, with alterations in the proliferation and differentiation of keratinocytes, associated with inflammatory changes.¹⁰

Presence of oral lesions in psoriasis is uncommon and controversial.¹² Oral manifestations such as geographic tongue and fissured tongue are highly non-specific. Some reports suggest that approximately 10% of patients would have geographic tongue, turning it the most common oral manifestation in these patients.¹³ These studies are based on the observation of elemental lesions, the histological similarity of both conditions and the presence of a common genetic marker HLA-Cw6.¹³⁻¹⁶ Gonzaga et al showed a strong association between the presence of HLA-Cw6 in psoriasis with geographic tongue, identifying this antigen in a 59.1% of patients with psoriasis and in a 43.8% of patients with benign migratory glossitis, while only a 12.6% was observed in the control group. As a consequence, the presence of geographic tongue has been planted as an authentic oral manifestation of psoriasis.¹⁶ However, other investigations have suggested that the association cannot be established properly,¹⁷ given there is a non-negligible percentage of healthy patients with migratory glossitis.¹⁸ An study performed by Picciani et al. has proposed that only some patients with suggestive tongue lesions would have true oral psoriasis, while the rest corresponds only to a primary geographic tongue.¹⁹

Geographic tongue has been described as an early manifestation of psoriasis, with late evolution into the fissured variant, which could be permanent and/or concomitant with geographic tongue up to a 34.5% of affected patients.^{5,20,21} Given the strong family history among parents and twins, both lesions could correspond to a polygenetic inheritance pattern.²² On the other hand, the fissured form has been described in pustular psoriasis,^{23,24} establishing a probable relationship with the severity of the disease.^{21,23,24} Recent studies have shown that mutations in the gene IL36RN are associated with geographic tongue, being the latter the main cause of generalized pustular psoriasis.²⁵

Allergies

Studies have linked the presence of allergies with geographic tongue. It has been reported that patients with personal or family history of asthma, eczema, allergic rhinitis and higher levels of immunoglobulin E are more prone to have geographic tongue when compared to people without the mentioned diseases.^{6,26} Miloglu et al determined that 24.1% of patients with geographic tongue had concomitantly an atopic or allergic disease.⁵ Likewise, the study of Marks et al.⁶ shows personal or family history of these diseases in 86% of the studied patients, while in the control group was only up to 37%.⁶

There is a relationship between geographic tongue and seborrheic dermatitis, with some subtypes of bronchitis in children.²⁷ Furthermore, a study in patients with cow's milk allergy by Mclendon and Jaeger²⁸ showed that a significant proportion of these patients present benign migratory glossitis.

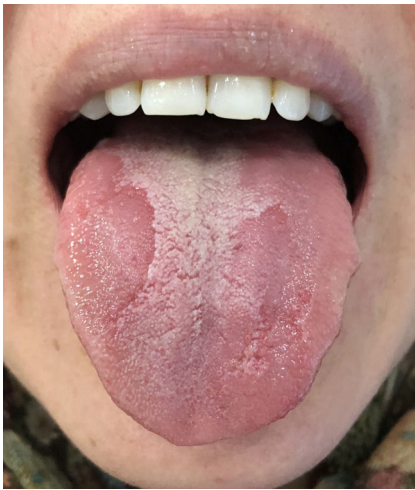

Figure 1 Erythematous plaques in absence of filiform papillae.

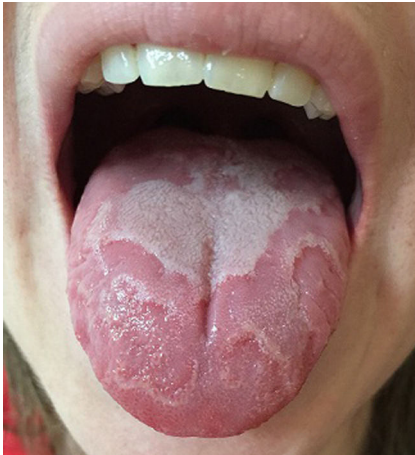

Figure 2 Erythematous plaques with a well-defined whitish margin on the dorsal of the tongue.

Atopic dermatitis

Atopic dermatitis is a relapsing chronic inflammatory skin disease associated with other atopic diseases such as allergic rhinitis and asthma.²⁹ In developed countries its prevalence has increased in the last 30 years, affecting 15-30% of children and 2-10% of adults.³⁰ It is characterized by periods of exacerbation and remission, presenting erythematous, highly pruritic, scaly and scabby plaques, evolving into lichenified plates secondary to scratching.³¹

Clinical manifestations vary with age and its etiopathogenesis responds to multiple mechanisms, hence 2 mainly hypothesis have been proposed: On the one hand, the primary defect would be an immunological alteration that causes an IgE-mediated sensitization, with a dysfunction of the epithelial barrier secondary to local inflammation; and on the other, there would be an intrinsic defect in the epithelial cells that leads to a dysfunction of the skin barrier.³² However, recent studies have proposed environmental allergens as a key triggering factor, proposing a new concept of pathogenesis ("from the outside in").

Regarding its association with geographic tongue, studies have reported that patients with a personal or family history of atopy are more likely to have benign migratory glossitis.^{6,31} This association may respond to the existence of psychosomatic factors, which contribute to both pathologies.³³ Furthermore, good response has been seen with the use of topical Tacrolimus in patients with symptomatic migratory glossitis, which is widely used in the treatment of atopic patients.³⁴

Vitamin D

There is no consistent evidence to establish a direct relationship between vitamin D deficiency and migratory glossitis. However, in 2016 a meta-analysis was performed establishing a possible role of vitamin D in improving the symptoms of atopic dermatitis.³⁵ Thus, it is possible to assume that vitamin D supplementation could help diminish severe symptoms of atopic dermatitis and, consequently, symptomatic glossitis.

Celiac disease

Celiac disease is an autoimmune disease that produces chronic inflammation of the small intestine's mucosa due to gluten intolerance.³⁶ There are genetic markers such as HLA DQ2 or HLA DQ8,³⁷ that are present in more than 95% of patients with this disease, compared to 40% in the general population. Clinically, it presents with malabsorption and malnutrition, diarrhea, anorexia, constipation, vomiting and abdominal distension.³⁸

Celiac disease may compromise oral cavity. The most frequent and best-documented oral manifestations are recurrent aphthous stomatitis and dental enamel defects,^{39,40} however, geographic tongue may constitute a possible oral manifestation of celiac disease.⁴¹⁻⁴³ Cigic et al conducted a study in patients with geographic tongue and no history of celiac disease. This study showed a 15% incidence of celiac disease in these patients, with diagnosis confirmed by duodenal biopsy. All patients had a genetic marker present (HLA DQ2 or HLA DQ8).³⁸

Although more studies are still required, the clinical examination of the oral cavity could serve as a diagnostic tool in patients with celiac disease, especially in atypical forms, which would help prevent associated complications.³⁸

Nutritional deficiencies

Since there is a relationship between iron and B complex vitamins deficiency with generalized glossitis with papillary atrophy, a possible association between geographic tongue and nutritional deficiencies has been proposed. This type of glossitis can be confused with geographic tongue, especially when the apex and lateral borders are compromised.^{44,45}

A study was conducted by the University of Minnesota in 42 patients with geographic tongue, in which no patient showed signs of nutritional deficiencies. Moreover, there was no trend towards improvement among the ten patients who

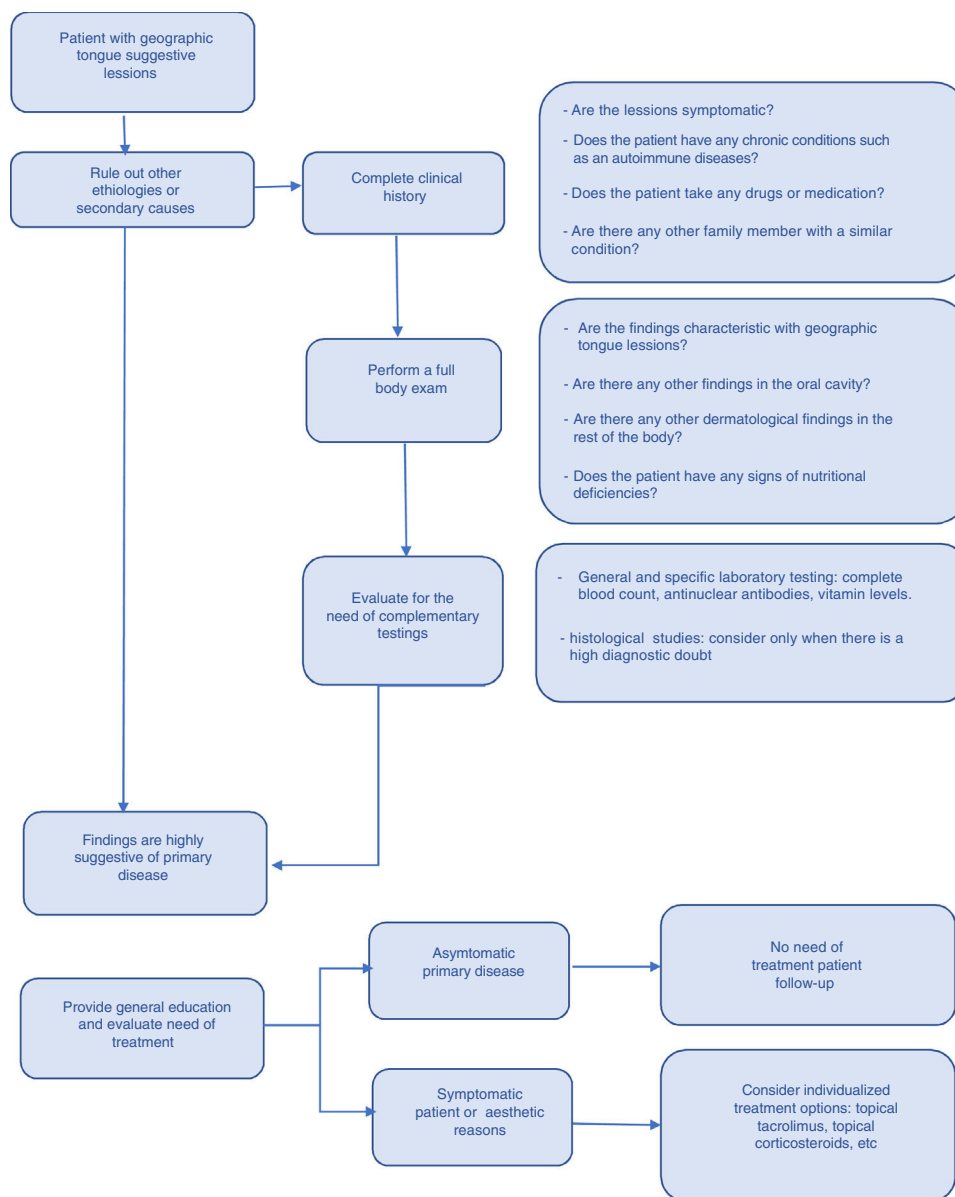


Figure 3 A proposed general approach to patients with suspected geographic tongue.

received a high dose of multivitamins and minerals when compared with the control group.⁴⁵

In a study performed in elderly patients suffering from lingual abnormalities, including geographic tongue, it was found that treatment with multivitamins for 6 months did not significantly influence these conditions.⁴⁶

Infections

Due to the inflammatory nature of the lesions, some bacterial and fungal infections were thought to be related with geographic tongue. However, no associated microorganism was consistently found.³⁴

Syndromes and geographical language³³

Some of the syndromes described are Reiter syndrome,⁴⁷ Robinow syndrome,⁴⁸ fetal hydantoin syndrome and Down

syndrome. Regarding the latter, a study conducted on mucocutaneous alterations in these patients established a possible association with lingual alterations, given that 28% of these patients had fissured tongue and 4% had a geographical tongue.⁴⁹

Diagnosis

The diagnosis of benign migratory glossitis is essentially clinical. Laboratory tests are usually normal and, in general terms, lesion biopsy is not required given the benign nature of the disease.¹

Clinically, erythematous plaques can be observed in absence of filiform papillae, with a well-defined whitish margin (Fig. 1) and a mixture of neutrophils and keratin.¹⁰ These lesions are found mainly in the dorsal and lateral regions of the tongue, have a migratory pattern, and can change size, shape and location within minutes to hours

(Fig. 2). They present periods of exacerbation and remission, without complications or sequelae.⁵⁰ There may be compromise of other areas of the oral mucosa such as soft palate, buccal mucosa, floor of the mouth, gums and uvula, however these are rare to be present.³³

In most cases it presents as an asymptomatic disease, with few reports of stomatodynia and/or foreign body sensation.

Differential diagnoses to be considered include: oral candidiasis, oral lichen planus, lupus erythematosus, trauma and adverse drug reaction. In children, atrophic candidiasis, local trauma and severe neutropenia should be ruled out.¹

Treatment

Due to its benign nature and mainly asymptomatic course, patients with geographic tongue do not usually receive treatment.¹ In cases of symptoms, such as pain and/or burning sensation, the use of mouthwashes with local anesthetic, topical corticosteroids and/or sucralfate can be considered.¹⁰ There are case reports with symptomatic glossitis that have presented an optimal response to the use of topical tacrolimus,³⁴ even in pediatric patients, and when given over a short period of time.⁵¹ However, in severe and persistent cases, the use of oral ciclosporin has been described as the main effective treatment.⁵² It is recommended to avoid irritating agents that exacerbate injuries, such as spiced and acid foods, and maintaining a good oral hygiene, with toothpastes free of dyes and preservatives.⁵³

A general approach to patients with geographic tongue is proposed in Fig. 3.

Conclusions

The geographical tongue or “migratory glossitis” is a benign and chronic inflammatory condition of the tongue, with no known cause. The diagnosis is made essentially with clinical resources, with characteristic findings on physical examination. It usually does not require treatment, given its benign condition and asymptomatic course.

Although there are no studies that aim at geographic tongue associations with certain pathologies and/or clinical conditions, it is possible to highlight some important aspects of these. First place, a considerable number of studies support the relationship between geographical tongue and psoriasis, showing a histological similarity and a common genetic marker. In this context, it is important to perform a thorough physical examination of patients with psoriasis in search of oral lesions, which if present, can constitute a marker of severity. In the same way, in patients with migratory glossitis, it is advisable to investigate in search of cutaneous lesions suggestive of psoriasis.

Regarding the existing relationship between allergies or atopy and geographical tongue, it could be useful to consider therapies that are beneficial in atopic patients for the treatment of symptomatic glossitis, such as the use of topical tacrolimus. Along these lines, a possible association between atopic patients and hypovitaminosis D has been proposed, so it has been suggested that supplementation with vitamin D could reduce its symptoms. However,

there are no studies that demonstrate this relationship with migratory glossitis. New lines of research are required to establish possible causality and relationship with severity of the lingual manifestations, as well to offer other treatment alternatives to patients with symptomatic and persistent migratory glossitis.

Conflicts of Interest

The authors declare that they have no conflicts of interest.

References

1. Assimakopoulos D, Patrikakos G, Fotika C, Elisaf M. Benign migratory glossitis or geographic tongue: An enigmatic oral lesion. *Am J Med.* 2002;113:5–751.
2. Kovac-Kovacic M, Skaleric U. The prevalence of oral mucosal lesions in a population in Ljubljana, Slovenia. *J Oral Pathol Med.* 2000;29:331–5.
3. Rioboo-Crespo MR, Planells-del Pozo P, Rioboo-García R. Epidemiology of the most common oral mucosal diseases in children. *Med Oral Patol Oral Cir Bucal.* 2005;10:376–87.
4. Jainkittivong A, Langlais RP. Geographic tongue: Clinical characteristics of 188 cases. *J Contemp Dent Pract.* 2005;6:123–35.
5. Miloğlu O, Göregen M, Akgül HM, Acemoğlu H. The prevalence and risk factors associated with benign migratory glossitis lesions in 7619 Turkish dental outpatients. *Oral Surg Oral Med Oral Pathol Oral Radiol Endod.* 2009;107:e29–33.
6. Marks R, Simons MJ. Geographic tongue —a manifestation of atopy. *Br J Dermatol.* 1979;101:159–62.
7. Redman RS, Shapiro BL, Gorlin RJ. Hereditary component in the etiology of benign migratory glossitis. *Am J Hum Genet.* 1972;24:124–33.
8. Eidelman E, Chosack A, Cohen T. Scrotal tongue and geographic tongue: Polygenic and associated traits. *Oral Surg Oral Med Oral Pathol.* 1976;42:591–6.
9. Hernández-Pérez F, Jaimes-Avelañez A, Urquizo-Ruvalcaba ML, Díaz-Barcelot M, Irigoyen-Camacho ME, Vega-Memije ME, et al. Prevalence of oral lesions in patients with psoriasis. *Med Oral Patol Oral Cir Bucal.* 2008;13:E703–8.
10. Picciani BL, Domingos TA, Teixeira-Souza T, Santos V de C, Gonzaga HF, Cardoso-Oliveira J, et al. Geographic tongue and psoriasis: Clinical, histopathological, immunohistochemical and genetic correlation —a literature review. *An Bras Dermatol.* 2016;91:410–21.
11. Dafar A, Çevik-Aras H, Robledo-Sierra J, Mattsson U, Jontell M. Factors associated with geographic tongue and fissured tongue. *Acta Odontol Scand.* 2016;74:210–6.
12. Costa SC, Hirota SK, Takahashi MD, Andrade H, Migliari DA. Oral lesions in 166 patients with cutaneous psoriasis: A controlled study. *Med Oral Patol Oral Cir Bucal.* 2009;14:5–371.
13. Picciani BL, Silva-Junior GO, Michalski-Santos B, Avelleira JC, Azulay DR, Pires FR, et al. Prevalence of oral manifestations in 203 patients with psoriasis. *J Eur Acad Dermatol Venereol.* 2011;25:1481–3.
14. Ulmanský M, Michelle R, Azaz B. Oral psoriasis: Report of six new cases. *J Oral Pathol Med.* 1995;24:42–5.
15. Femiano F. Geographic tongue (migrant glossitis) and psoriasis. *Minerva Stomatol.* 2001;50:213–7.
16. Gonzaga HF, Torres EA, Alchorne MM, Gerbase-Delima M. Both psoriasis and benign migratory glossitis are associated with HLA-Cw6. *Br J Dermatol.* 1996;135:368–70.
17. Hietanen J, Salo OP, Kanerva L, Juvakoski T. Study of the oral mucosa in 200 consecutive patients with psoriasis. *Scand J Dent Res.* 1984;92:50–4.

18. Migliari DA, Penha SS, Marques MM, Matthews RW. Considerations on the diagnosis of oral psoriasis: A case report. *Med Oral*. 2004;9:300–3.
19. Picciani B, Santos VC, Teixeira-Souza T, Izahias LM, Curty A, Avelleira JC, et al. Investigation of the clinical features of geographic tongue: Unveiling its relationship with oral psoriasis. *Int J Dermatol*. 2017;56:421–7.
20. Picciani BL, Souza TT, Santos V de C, Domingos TA, Carneiro S, Avelleira JC, et al. Geographic tongue and fissured tongue in 348 patients with psoriasis: Correlation with disease severity. *Scientific World Journal*. 2015;5643:26.
21. Zargari O. The prevalence and significance of fissured tongue and geographical tongue in psoriatic patients. *Clin Exp Dermatol*. 2006;31:192–5.
22. Gonzaga HF, Marcos EV, Santana FC, Jorge MA, Tomimori J. HLA alleles in Brazilian patients with fissured tongue. *J Eur Acad Dermatol Venerol*. 2013;27:e166–70.
23. Daneshpazhooh M, Moslehi H, Akhyani M, Etesami M. Tongue lesions in psoriasis: A controlled study. *BMC Dermatol*. 2004;4:16.
24. Baker H, Ryan TJ. Generalized pustular psoriasis. A clinical and epidemiological study of 104 cases. *Br J Dermatol*. 1968;80:771–93.
25. Liang J, Huang P, Li H, Zhang J, Cheng N, Wang Y, et al. Mutations in IL36RN are associated with geographic tongue. *Hum Genet*. 2017;136:241–52.
26. Rezaei F, Safarzadeh M, Mozafari H, Tavakoli P. Prevalence of geographic tongue and related predisposing factors in 7-18 year-old students in Kermanshah, Iran, 2014. *Glob J Health Sci*. 2015;7:91–5.
27. Rahamimoff P, Muhsam HV. Some observations on 1246 cases of geographic tongue: The association between geographic tongue, seborrheic dermatitis, and spasmodic bronchitis; transition of geographic tongue to fissured tongue. *AMA J Dis Child*. 1957;93:519–25.
28. McLendon P, Jaeger D. Milk intolerance, the cause of a nutritional entity: A clinical study. *South Med J*. 1943;36:571–5.
29. Akdis CA, Akdis M, Bieber T, Bindslev-Jensen C, Boguniewicz M, Eigenmann P, et al. Diagnosis and treatment of atopic dermatitis in children and adults: European Academy of Allergology and Clinical Immunology/American Academy of Allergy Asthma and Immunology/PRACTALL Consensus Report. *J Allergy Clin Immunol*. 2006;118:152–69.
30. Williams H, Floh C. How epidemiology has challenged 3 prevailing concepts about atopic dermatitis. *J Allergy Clin Immunol*. 2006;118:209–13.
31. Bascones-Martínez MA, Valero-Marugán A, Encinas-Bascones A, Carrillo de Albornoz A, Bascones-Martínez A. Lengua geográfica y dermatitis atópica: una asociación frecuente. *Av Odon-toestomatol*. 2006;22:111–8.
32. Leung DY, Bieber T. Atopic dermatitis. *Lancet*. 2003;361:151–60.
33. Hooda A, Rathee M, Gulia J, Yadav S. Benign migratory glossitis: A review. *The Internet Journal of Family Practice*. 2009;9:1528–8358.
34. Ishibashi M, Tojo G, Watanabe M, Tamabuchi T, Masu T, Aiba S. Geographic tongue treated with topical tacrolimus. *J Dermatol Case Rep*. 2010;4:57–9.
35. Kim G, Bae JH. Vitamin and atopic dermatitis: A systematic review and meta-analysis. *Nutrition*. 2016;32:913–20.
36. Heredia C, Castro F, Palma J. Enfermedad celíaca del adulto. *Rev Méd Chile*. 2007;135:1186–94.
37. Husby S, Koletzko S, Korponay-Szabó IR, Mearin ML, Phillips A, Shamir R, et al. European Society for Pediatric Gastroenterology Hepatology, and Nutrition guidelines for the diagnosis of coeliac disease. *J Pediatr Gastroenterol Nutr*. 2012;54:136–60.
38. Cigic L, Galic T, Kero D, Simunic M, Medvedec Mikic I, Kalibovic Govorko D, et al. The prevalence of celiac disease in patients with geographic tongue. *J Oral Pathol Med*. 2016;45:791–6.
39. Sedghizadeh PP, Shuler CF, Allen CM, Beck FM, Kalmar JR. Celiac disease and recurrent aphthous stomatitis: A report and review of the literature. *Oral Surg Oral Med Oral Pathol Oral Radiol Endod*. 2002;94:474–8.
40. Rashid M, Zarkadas M, Anca A, Limeback H. Oral manifestations of celiac disease: A clinical guide for dentists. *J Mich Dent Assoc*. 2011;93:42–6.
41. Pastore L, Lo Muzio L, Serpico R. Atrophic glossitis leading to the diagnosis of celiac disease. *N Engl J Med*. 2007;356:2547.
42. Krzywicka B, Herman K, Kowalczyk-Zajac M, Pytrus T. Celiac disease and its impact on the oral health status —review of the literature. *Adv Clin Exp Med*. 2014;23:675–81.
43. Pastore L, Carroccio A, Compilato D, Panzarella V, Serpico R, Lo Muzio L. Oral manifestations of celiac disease. *J Clin Gastroenterol*. 2008;42:224–32.
44. Byrd JA, Bruce AJ, Rogers RS. Glossitis and other tongue disorders. *Dermatol Clin*. 2003;21:123–34.
45. Redman RS. Nutritional deficiencies and geographic tongue. *J Chronic Dis*. 1964;17:627–30.
46. MacLeod RD. Abnormal tongue appearances and vitamin status of the elderly —a double blind trial. *Age Ageing*. 1972;1:99–102.
47. Wright V, Reed WB. The link between reiter's syndrome and psoriatic arthritis. *Ann Rheum Dis*. 1964;23:12–21.
48. Cerqueira DF, de Souza IP. Orofacial manifestations of Robinow's syndrome: A case report in a pediatric patient. *Oral Surg Oral Med Oral Pathol Oral Radiol Endod*. 2008;105:353–7.
49. Daneshpazhooh M, Nazemi TM, Bigdeloo L, Yoosefi M. Mucocutaneous findings in 100 children with Down syndrome. *Pediatr Dermatol*. 2007;24:317–20.
50. Jacob CN, John TMRJ. Geographic tongue. *Cleve Clin J Med*. 2016;83:565–6.
51. Purani JM, Purani HJ. Treatment of geographic tongue with topical tacrolimus. *BMJ Case Rep*. 2014;2014, bcr-2013-201268.
52. Keshavarz E, Roknsharifi S, Shirali Mohammadpour R, Roknsharifi M. Clinical features and severity of psoriasis: A comparison of facial and nonfacial involvement in Iran. *Arch Iran Med*. 2013;16:25–8.
53. Alikhani M, Khalighinejad N, Ghalaiani P, Khaleghi MA, Askari E, Gorsky M. Immunologic and psychologic parameters associated with geographic tongue. *Oral Surg Oral Med Oral Pathol Oral Radiol*. 2014;118:68–71.