

## References

- Ferrandiz-Pulido C, Garcia-Patos V. A review of causes of Stevens-Johnson syndrome and toxic epidermal necrolysis in children. *Arch Dis Child*. 2013;98:998–1003.
- Mockenhaupt M, Viboud C, Dunant A, Naldi L, Halevi S, Bouwes JN, et al. Stevens-Johnson syndrome and toxic epidermal necrolysis: assessment of medication risks with emphasis on recently marketed drugs. The EuroSCAR-study. *J Invest Dermatol*. 2008;128:35–44.
- Hsu DY, Brieve J, Silverberg NB, Paller AS, Silverberg JI. Pediatric Stevens-Johnson syndrome and toxic epidermal necrolysis in the United States. *J Am Acad Dermatol*. 2017;76, 811–817.e4.
- Creamer D, Walsh SA, Dzielwski P, Exton LS, Lee HY, Dart JKG, et al. UK guidelines for the management of Stevens-Johnson syndrome/toxic epidermal necrolysis in adults 2016 (print summary - Full guidelines available at <http://dx.doi.org/10.1016/j.bjps.2016.01.034>). *J Plast Reconstr Aesthetic Surg*. 2016;69:736–41.
- Zimmermann S, Sekula P, Venhoff M, Motschall E, Knaus J, Schumacher M, et al. Systemic immunomodulating therapies for Stevens-Johnson syndrome and toxic epidermal necrolysis: a systematic review and meta-analysis. *JAMA Dermatol*. 2017;153:514–22.
- González-Herrada C, Rodríguez-Martín S, Cachafeiro L, Lerma V, González O, Lorente JA, et al. Cyclosporine use in epidermal necrolysis is associated with an important mortality reduction: evidence from three different approaches. *J Invest Dermatol*. 2017;137:2092–100.
- Lee HY, Fook-Chong S, Koh HY, Thirumorthy T, Pang SM. Cyclosporine treatment for Stevens-Johnson syndrome/toxic epidermal necrolysis: retrospective analysis of a cohort treated in a specialized referral center. *J Am Acad Dermatol*. 2017;76:106–13.
- Mohanty S, Das A, Ghosh A, Sil A, Gharami RC, Bandyopadhyay D, et al. Effectiveness, safety and tolerability of cyclosporine versus supportive treatment in Stevens-Johnson Syndrome/Toxic Epidermal Necrolysis: a record-based study. *Indian J Dermatol Venereol Leprol*. 2017;83:312–6.
- Poizeau F, Gaudin O, Le Cleach L, Duong TA, Hua C, Hotz C, et al. Cyclosporin for epidermal necrolysis: absence of beneficial effect in a retrospective cohort of 174 patients - exposed/unexposed and propensity-score matched analyses. *J Invest Dermatol*. 2018;138:1293–300.
- Levi N, Bastuji-Garin S, Mockenhaupt M, Roujeau JC, Flahault A, Kelly J, et al. Medications as risk factors of Stevens-Johnson syndrome and toxic epidermal necrolysis in children: a pooled analysis. *Pediatrics*. 2009;123:e297–304.
- Halevy S, Ghislain PD, Mockenhaupt M, Fagot JP, Bouwes Bavincck JN, Sidoroff A, et al. Allopurinol is the most common cause of Stevens-Johnson syndrome and toxic epidermal necrolysis in Europe and Israel. *J Am Acad Dermatol*. 2008;58:25–32.

D. Morgado-Carrasco, M.A. González Enseñat, C. Prat, A. Vicente-Villa\*

*Servicio de Dermatología, Hospital Sant Joan de Déu, Barcelona, Spain*

\* Corresponding author.

*E-mail address:* [avicente@sjdhospitalbarcelona.org](mailto:avicente@sjdhospitalbarcelona.org) (A. Vicente-Villa).

<https://doi.org/10.1016/j.adengl.2020.08.002>  
1578-2190/ © 2020 AEDV. Published by Elsevier España, S.L.U. This is an open access article under the CC BY-NC-ND license (<http://creativecommons.org/licenses/by-nc-nd/4.0/>).

## Cryptococcal Immune Reconstitution Inflammatory Syndrome: An Unusual Presentation on the Tongue\*



### Síndrome inflamatorio de reconstitución inmune criptocócico: presentación inusual en la lengua

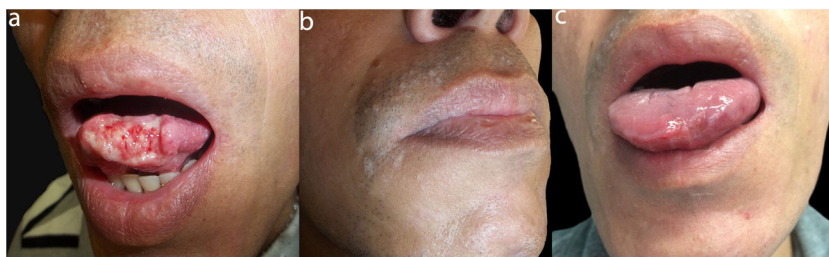*To the Editor:*

A 37-year-old man came to the clinic with a tongue ulcer that had first appeared 15 days earlier. The ulcer was painful, grew slowly, and caused difficulty eating and speaking. The patient, who was from Bogotá in Colombia, had a history of HIV infection, with a baseline viral load of 261 647 copies/mL and a CD4<sup>+</sup> count of 28/mm<sup>3</sup> (2.1%). He had started antiretroviral therapy with tenofovir, emtricitabine, and efavirenz 1 month before coming to the clinic. Physical examination revealed an ulcer on the tip of his tongue (2.2 × 1 cm). The ulcer had irregular indurated bor-

ders and a base with fibrinoid tissue. The ulcer was painful on palpation and was associated with a right submaxillary adenopathy. The perioral region contained several pearly papules that were firm in consistency and molluscoid in appearance (Fig. 1A and B). We performed a biopsy, which revealed structures compatible with *Cryptococcus* species. Therefore, the patient was admitted to hospital. Computed tomography scan of the chest revealed several randomly distributed nodules and a dominant cavitory lesion in the apex of the right lung. We performed fiberoptic bronchoscopy and transbronchial biopsy, which revealed a nonnecrotizing granuloma comprising giant cells that phagocytosed round fungal structures, which were shown to be positive with Grocott stain. Culture was positive for *Cryptococcus neoformans*. In addition to the serum cryptococcal antigen latex agglutination test, which was positive, the results of other laboratory analysis (e.g., serial blood cultures and latex agglutination of cerebrospinal fluid, bacilloscopy, and culture of bronchial secretions) were negative. The patient was diagnosed with cryptococcal immune reconstitution inflammatory syndrome (C-IRIS), and induction treatment was started with amphotericin B deoxycholate and fluconazole for 2 weeks, followed by 8 weeks of consolidation therapy with fluconazole. The clinical picture had resolved by the end of treatment (Fig. 1C).

C-IRIS is considered clinical deterioration of the disease caused by the encapsulated yeast *Cryptococcus* in immuno-

\* Please cite this article as: Ballén J, Quiroga C, Palma F. Síndrome inflamatorio de reconstitución inmune criptocócico: presentación inusual en la lengua. *Actas Dermosifiliogr*. 2020;111:617–619.



**Figure 1** A, Tongue ulcer. B, Molluscoid pearly papules on the upper lip. C, Re-epithelialized lesion after treatment.

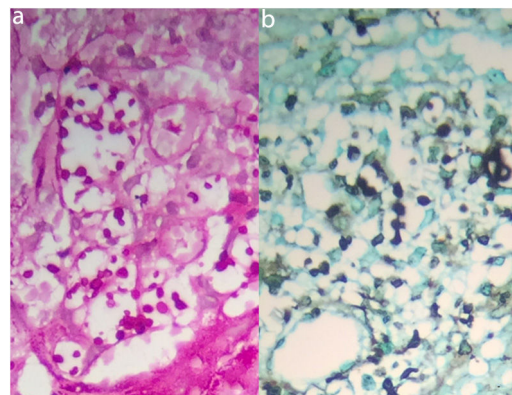
compromised patients whose specific immune response improves.<sup>1</sup> Pathogenesis is complex and not fully understood, although it seems that after severe immune deficiency, together with the inability to remove foreign antigens, the process is followed by immune restoration leading to a cytokine storm, a rapid increase in CD4 count, and reduced viral load 4 to 6 weeks after initiating antiretroviral therapy, thus leading to clinical expression of the symptoms.<sup>2,3</sup>

Cryptococcosis is the second most frequent opportunistic infection associated with IRIS and the first in terms of mortality (20.8%). The infection can remain latent for several years after the initial exposure and may remain subclinical for some time.<sup>1</sup> Primary infection in the lungs may disseminate via the bloodstream to several organs, thus generating meningoencephalic, gastrointestinal, musculoskeletal, and mucocutaneous involvement.<sup>4</sup>

Cutaneous lesions are observed in 6% of cases of AIDS-associated disseminated cryptococcosis. The initial lesion is usually a painless papule that is soft in the center and ulcerated at the tip, which sometimes takes on an acneiform or molluscoid appearance (Fig. 1B). The ulcerated papules can become vegetating lesions or plaques covered by serosanguineous crusts, and in patients with severe immune deficiency, they can become complicated with vasculitis, thus generating palpable purpura. Compromise of other areas, particularly the oral cavity, is rare, with only a few cases of localized lesions on the tongue reported, most of which are associated with HIV infection.<sup>5-8</sup> The lesion can present as nodules, granulomas, and indurated deep or superficial ulcers, which are similar to carcinoma.<sup>8,9</sup> Pleomorphism in mucocutaneous lesions hampers the diagnosis of this infection; therefore, in the case of a tongue ulcer, we should initially suspect other causes of infection such as herpesvirus, cytomegalovirus, and histoplasmosis, as well as neoplastic processes such as squamous cell carcinoma and lymphoma.

Diagnosis is based on observation of encapsulated yeasts in direct microscopy, isolation of *C neoformans* or *Cryptococcus gattii* in culture, and demonstration of capsular antigen in the supernatant of fluids, including serum and cerebrospinal fluid, by latex agglutination or enzyme-linked immunosorbent assay. Stains such as Periodic acid-Schiff, Grocott-Gomori's Methenamine Silver, Giemsa, Alcian blue, and mucicarmine, which were used in the histological sections in the present case (Fig. 2), are specific for cryptococcosis.<sup>4,9,10</sup>

In the case we report, the patient received treatment with amphotericin B, which, together with its liposomal



**Figure 2** A, Staining with -Periodic acid-Schiff (original magnification,  $\times 400$ ) reveals an ulcerated epithelium with hyperplasia. Note the mixed inflammatory infiltrate in a fibrous and mucoid stroma containing histiocytic granulomas with clear and abundant cytoplasm. These are full of yeasts of different shapes and sizes, some of which are encapsulated in appearance. B, Staining with Grocott-Gomori's Methenamine Silver (original magnification,  $\times 400$ ). Positivity in the capsule of the yeasts.

derivative and 2 older agents (5-fluorocytosine and fluconazole), forms part of the therapeutic arsenal. These medications can be used alone or in combination, although combination therapy has proven to be more successful.<sup>10</sup>

In conclusion we present a case of cryptococcosis with unusual manifestations on the tongue of a patient with AIDS in the context of IRIS. Cases of the type described here represent a diagnostic challenge for the multidisciplinary teams that manage this type of patient.

## Conflicts of Interest

The authors declare that they have no conflicts of interest.

## References

- Haddow LJ, Colebunders R, Meintjes G, Lawn SD, Elliott JH, Yukari C. Cryptococcal immune reconstitution inflammatory syndrome in HIV-1-infected individuals: literature review and proposed clinical case definitions. *Lancet Infect Dis*. 2011;10:791-802.
- Antinori S. New insights into HIV/AIDS-associated cryptococcosis. *ISRN AIDS*. 2013;25:471363.
- Gasiorowski J, Knysz B, Szetela B, Gładysz A. Cutaneous cryptococcosis as a rare manifestation of the immune reconstitution

- syndrome in an HIV-1-infected patient. *Postepy Hig Med Dosw.* 2008;62:1–3.
4. Negróni R. Cryptococcosis. *Clin Dermatol.* 2012;30:599–609.
  5. Garzzoni A, Severo C, Barra M, Severo L. Atypical micromorphology and uncommon location of cryptococcosis: a histopathologic study using special histochemical techniques (one case report). *Mycopathologia.* 2009;167:197–202.
  6. Tzerbos F, Kabani S, Booth D. Cryptococcosis as an exclusive oral presentation. *J Oral Maxillofac Surg.* 1992;50:759–60.
  7. Reinstadler DR, Dadwal S, Maghami E. Cryptococcal tongue lesion in a stem cell transplant patient: first reported case. *Case Rep Otolaryngol.* 2012;2012:517415.
  8. Mohamad I, Abdullah B, Salim R, Rajet KA, Naik VR. Cryptococcosis: a rare fungal infection of the tongue. *Southeast Asian J Trop Med Public Health.* 2010;41:1188–91.
  9. Iatta R, Napoli C, Borghi E, Montagna MT. Rare mycoses of the oral cavity: a literature epidemiologic review. *Oral Surg Oral Med Oral Pathol Oral Radiol Endod.* 2009;108:647–55.
  10. Perfect JR, Bicanic T. Cryptococcosis diagnosis and treatment: what do we know now. *Fungal Genet Biol.* 2014;78:49–54.

J. Ballén<sup>a,\*</sup>, C. Quiroga<sup>b</sup>, F. Palma<sup>c</sup>

<sup>a</sup> *Dermatología, Fundación Universitaria Sanitas, Bogotá D.C., Colombia*

<sup>b</sup> *Servicio de Infectología, Colsanitas, Bogotá D.C., Colombia*

<sup>c</sup> *Dermatopatología, Universidad Nacional de Colombia, Bogotá D.C., Colombia*

\* Corresponding author.

E-mail address: [jobaf@hotmail.com](mailto:jobaf@hotmail.com) (J. Ballén).

<https://doi.org/10.1016/j.adengl.2020.08.008>  
1578-2190/ © 2020 AEDV. Published by Elsevier España, S.L.U. This is an open access article under the CC BY-NC-ND license (<http://creativecommons.org/licenses/by-nc-nd/4.0/>).

## Melanoma in Noonan Syndrome With Multiple Lentigines (LEOPARD syndrome): A new case<sup>☆</sup>



### Melanoma en el síndrome de Noonan con lentigos múltiples (síndrome de LEOPARD): presentación de un nuevo caso

To the Editor:

Noonan syndrome with multiple lentigines (NSML), also known as LEOPARD syndrome, is a rare genetic skin disease whose acronym comes from its main clinical manifestations: lentigines (multiple), electrocardiographic conduction abnormalities, ocular hypertelorism, pulmonary stenosis, abnormalities of the genitalia, retarded growth, and deafness (sensorineural). NSML is usually associated with a mutation in the *PTPN11* gene leading to alterations in the RAS-mitogen activated protein kinase (MAPK) transduction pathway. This signal transduction pathway plays a key role in the tumorigenesis of various cancers. There have also been reports of mutations in other genes, such as *RAF1* and *BRAF*,<sup>1</sup> thus enabling us to classify the syndrome as belonging to the so-called RASopathy group.<sup>2</sup> Abnormal function of the abovementioned signal transduction pathways can increase the risk of cancer, with reports of an increased risk of diseases such as leukemia and neuroblastoma.<sup>3</sup> However, the association with melanoma has received little attention in the literature, with only 4 cases published to date.<sup>4–7</sup>

A 44-year-old man with NSML confirmed by a genetic study of the mutation p.Tyr279Cys (c.8364 > G) in heterozy-

gosity in the *PTPN11* gene consulted in the dermatology department for follow-up of his skin lesions. The typical clinical manifestations of the syndrome included multiple lentigines, electrocardiographic abnormalities (incomplete right bundle branch block and anterior fascicular block), surgically treated infundibular pulmonary stenosis, and auditory abnormalities.

The physical examination revealed marked generalized multiple lentigines on the trunk and extremities, with most lesions measuring < 1 cm and other, larger lesions that were smaller in number. One of the most noticeable lesions was at the dorsal level. It had appeared recently and differed from the other lesions, with an irregular morphology. It measured approximately 2 × 1.2 cm and had a more intense pigmentation. Polarized light dermoscopy revealed an atypical pigment network and gray-blue areas (Figs. 1 and 2).

Given its clinical and dermoscopic characteristics and progress, the lesion was completely removed. Histopathology revealed superficial spreading melanoma with a Breslow depth of 0.15 mm, and no ulceration, mitosis, vascular invasion, or evident neurotropism (Fig. 3).

The patient was staged as IA according to the American Joint Committee on Cancer (2017).

A recent description of the clinical, histopathologic, and dermoscopic characteristics of NSML<sup>8</sup> included both simple lentigines (lesions < 1 cm in diameter) and café noir spots (lesions > 1 cm in diameter), which, depending on their pigmentation and histologic and dermoscopic characteristics, have been subclassified as dark and medium-colored or pale.

Despite the low number of cases published, it is thought that patients with NSML could have an increased risk of developing melanoma. This increased risk is explained because 90% of patients with NSML have a mutation in the *PTPN11* gene.<sup>1</sup> This gene codes for a protein tyrosine phosphatase (SHP-2), which regulates the activity of the RAS signaling pathway. The protein acts as a cytoplasmic transducer of various growth factors, cytokines, hormones, and integrins that produce the NSML phenotype.

<sup>☆</sup> Please cite this article as: García-Gil MF, Álvarez-Salafranca M, Valero-Torres A, Ara-Martín M. Melanoma en el síndrome de Noonan con lentigos múltiples (síndrome de LEOPARD): presentación de un nuevo caso. *Actas Dermosifiliogr.* 2020;111:619–621.