

adverse reactions, given the modification of the protocol based it.<sup>10</sup>

The limitation of this study is the fact that it is a retrospective and single-center study. One of its strengths is the sample size, which is larger than that of other studies.

## References

1. Pérez-Ferriols A, Aranegui B, Pujol-Montcusí JA, Martín-Gorgojo A, Campos-Domínguez M, Feltes RA, et al. Phototherapy in atopic dermatitis: a systematic review of the literature. *Actas Dermosifiliogr.* 2015;106:387–401.
2. Patrizi A, Raone B, Ravaioli GM. Safety and efficacy of phototherapy in the management of eczema. *Adv Exp Med Biol.* 2017;996:319–31.
3. Sidbury R, Davis DM, Cohen DE, Cordoro KM, Berger TG, Bergman JN, et al. Guidelines of care for the management of atopic dermatitis: section 3. Management and treatment with phototherapy and systemic agents. *J Am Acad Dermatol.* 2014;71:327–49.
4. Batchelor RJ, Rose RF, Yung A, Rathmell B, Turner D, Goulden V. Audit of erythema in patients with psoriasis undergoing phototherapy with narrowband (TL-01) ultraviolet B: impact of the introduction of a comprehensive erythema-reporting protocol. *Br J Dermatol.* 2007;156:1045–6.
5. Reich A, Heisig M, Phan NQ, Taneda K, Takamori K, Takeuchi S, et al. Visual analogue scale: evaluation of the instrument for the assessment of pruritus. *Acta Derm Venereol.* 2012;92:497–501.
6. Clowry J, Molloy K, Nestor L, Edwards K, Salim A, Connolly M, et al. Narrow-band ultraviolet B phototherapy outcomes in atopic dermatitis—a single-centre retrospective review. *Photodermatol Photoimmunol Photomed.* 2018;34:217–9.
7. Chicharro P, Rodríguez-Jiménez P, Capusan TM, Herrero-Moyano M, de Argila D. Induction of light tolerance using narrow-band UV-B in solar urticaria. *Actas Dermosifiliogr.* 2018;109:888–92.
8. Ortiz-Salvador JM, Pérez-Ferriols A. Phototherapy in Atopic Dermatitis. In: Ahmad SI, editor. *Ultraviolet light in human health, diseases and environment.* Suíza: Springer; 2017. p. 279–86.
9. Evers AWM, Kleinpenning MM, Smits T, Boezeman J, van de Kerkhof PCM, Kraaijaak FW, et al. Itch and scratching as predictors of time to clearance of psoriasis with narrow-band ultraviolet B therapy. *Br J Dermatol.* 2009;161:542–6.
10. Rodríguez-Granados MT, Estany-Gestal A, Pousa-Martínez M, Labandeira J, Gato Otero R, Fernández-Redondo V. Is it useful to calculate minimal erythema dose before narrowband UV-B phototherapy? *Actas Dermosifiliogr.* 2017;108:852–8.

P. Pérez Feal,<sup>a,\*</sup> A. Estany Gestal,<sup>b</sup>

S. Rodríguez-Tubío Dapena,<sup>a</sup> M.T. Rodríguez Granados<sup>a</sup>

<sup>a</sup> *Servicio de Dermatología, Complejo Hospitalario Universitario de Santiago de Compostela, Santiago de Compostela, La Coruña, Spain*

<sup>b</sup> *Unidad de Epidemiología, Fundación Instituto de Investigación de Santiago de Compostela (FIDIS), Santiago de Compostela, La Coruña, Spain*

\* Corresponding author.

E-mail address: [patriciaperezfeal@gmail.com](mailto:patriciaperezfeal@gmail.com)

(P. Pérez Feal).

<https://doi.org/10.1016/j.adengl.2019.10.011>

1578-2190/ © 2020 AEDV. Published by Elsevier España, S.L.U. This is an open access article under the CC BY-NC-ND license (<http://creativecommons.org/licenses/by-nc-nd/4.0/>).

## Ex vivo fluorescence confocal microscopy on a 3-color scale: A new imaging technique<sup>☆</sup>



### Microscopía confocal de fluorescencia ex vivo en escala de tres colores (mcf-3cs): una nueva técnica de imagen

Dear Editor:

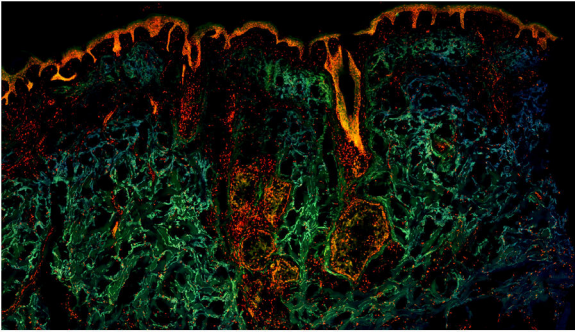
Confocal microscopy (CM) is an imaging technique that permits real-time visualization of skin structures with a resolution approaching that of conventional histology.<sup>1</sup> This technique has been applied in several skin diseases, in particular, tumors such as basal cell carcinoma (BCC) or squamous cell carcinoma. With this technique, the skin can be imaged directly (*in vivo*) or surgically removed

pieces can be examined (*ex vivo*). In the latter case, the use of fluorophores has improved the quality of the images obtained with a technique known as fluorescence CM (FCM).

Several different dyes have been used in FCM, such as methylene blue or toluidine blue; however, acridine orange (AO) is the most widely used.<sup>2</sup> AO binds specifically to DNA or RNA of living cells, acting as a fluorophore that is excited at a specific wavelength and then emits fluorescence. Nuclear cells can therefore be marked, and they are observed as brilliant white structures in FCM mosaics.<sup>3</sup> Structures that do not have a nucleus, such as collagen bundles that form part of the dermis, would emit weak fluorescence or not at all. AO can therefore increase image contrast 100-fold.<sup>4</sup> It is also important to point out that AO does not lead to sample degeneration and subsequent staining with traditional stains such as hematoxylin-eosin is still possible.<sup>5</sup>

To date, in images of FCM published in the scientific literature, fluorescence emitted by AO has been translated by microscopy to a final greyscale or dichromatic image.<sup>6</sup> Despite the excellent contrast between structures and the strong histopathologic correlation shown by these images, the final greyscale mosaics are difficult to interpret

<sup>☆</sup> Please cite this article as: Sendín-Martín M, Domínguez-Cruz JJ, Levitsky K-L, Conejo-Mir Sánchez J. Microscopía confocal de fluorescencia ex vivo en escala de tres colores (mcf-3cs): una nueva técnica de imagen. *Actas Dermosifiliogr.* 2020;155:702–704.



**Figure 1** Fragment of healthy skin observed with a color fluorescence confocal microscope.

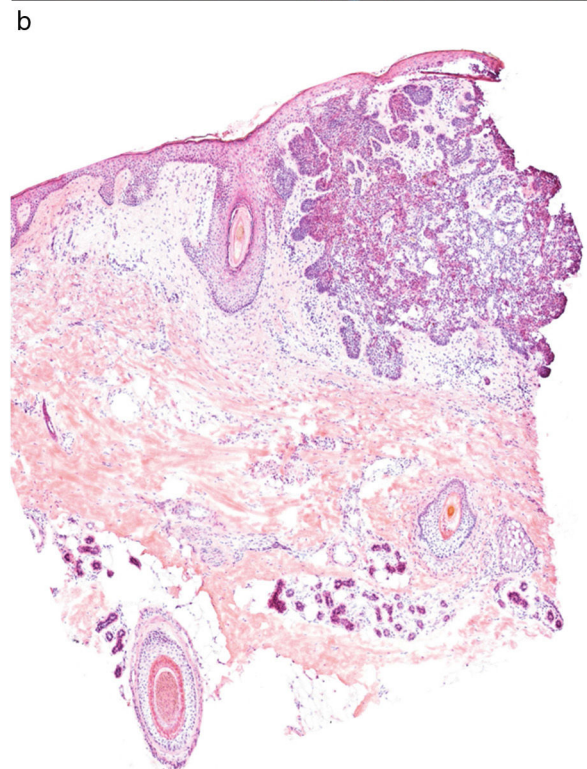
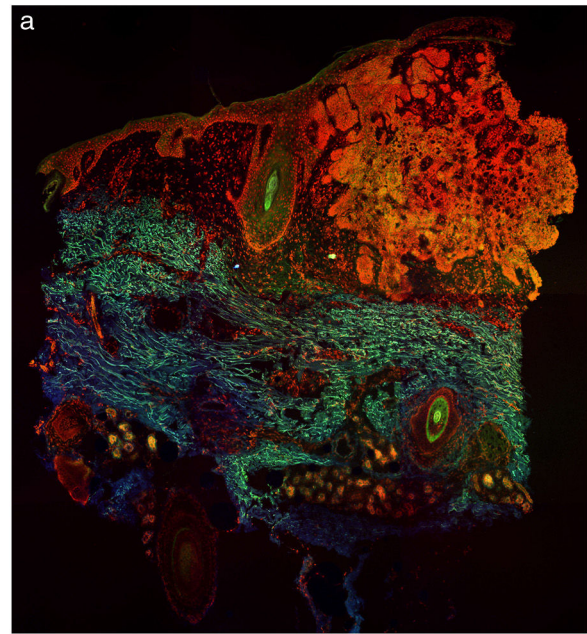
for dermatologists and pathologists who are not expert in CM.

Recently, our group has described a new technique for obtaining FCM images using a 3 color scale (FCM-3CS), through the joint use of AO and ethidium bromide (EB).<sup>7</sup>

In this technique, the resected pieces are immersed in liquid nitrogen, thereby ensuring an almost instantaneous freezing. They are then sectioned in a cryostat in rapid cuts measuring 20–30  $\mu\text{m}$  thick. After sectioning, the sample is stained by pouring on a mixture of AO 0.1 mM and EB 0.25 nM, and leaving the solution to act for a minute. After this brief processing, the sample is placed under a commercially available confocal microscope, Nikon A1R\* (Nikon Corporation®, Japan). Once under the microscope, the sample is excited simultaneously with 2 different wavelengths, 405 nm and 488 nm. The microscope collects fluorescence emitted by the sample after excitation to obtain images with a 3-color scale. The process requires between 10 and 15 minutes to obtain the final color mosaics.

These color images are the result of the joint action of the 2 fluorophores applied to the sample. EB is a fluorophore that binds specifically to DNA in cells that have lost membrane integrity.<sup>8</sup> EB passes through the damaged nuclear membranes after freezing, binding with high affinity to DNA and thus staining these cell nuclei. In this way, when the sample is excited with laser light at 405 nm, EB emits red fluorescence, marking the nuclei with high precision. The dermis and anucleate structures emit green fluorescence from AO after excitation at 488 nm. The weak blue fluorescence originates from intrinsic fluorescence of the tissues. All this fluorescence is detected by the microscope, and as a result, the final images are obtained on a 3-color scale.

Fig. 1 shows how a fragment of healthy skins looks with this technique. Nucleated structures emit red fluorescence, which contrasts significantly with green fluorescence, yielding images that are very intuitive and easy to interpret, with a very high resolution. This resolution enables the skin tumor margins to be delimited with high precision, for example in the case of BCC shown in Fig. 2A. Note the complete correlation with classic hematoxylin-eosin staining (Fig. 2b). After processing, in relation to images H-E, we do not observe significant changes in image quality.



**Figure 2** A, Basal cell carcinoma studied with a color fluorescence confocal microscope. B, Note the correlation with traditional hematoxylin-eosin images.

The main application of *ex vivo* CM currently is in oncological surgical processes, such as Mohs surgery. It can be expected that in coming years, the cost of devices needed for CM will come down, making it a cost-effective technique that could be incorporated progressively into everyday clinical practice.

In conclusion, images with color FCM images are significantly simpler to interpret than greyscale images for

dermatologists and pathologists who are not expert in CM. Furthermore, thanks to processing by sample freezing, the sample is completely flat. Therefore, complete sample images can be obtained, without losing mosaics due to sample folding. These are all important advantages compared with traditional images obtained with CM. Nevertheless, more studies are needed to validate this new technique.

## Funding

This study did not receive any funding.

## Conflicts of interest

The authors declare that they have no conflicts of interest.

## References

1. Longo C, Ragazzi M, Rajadhyaksha M, Nehal K, Bennassar A, Pellacani G, et al. *In vivo* and *ex vivo* confocal microscopy for dermatologic and Mohs surgeons. *Dermatol Clin*. 2016;34:497–504.
2. Ragazzi M, Longo C, Piana S. *Ex vivo* (fluorescence) confocal microscopy in surgical pathology: state of the art. *Adv Anat Pathol*. 2016;23:159–69.
3. Bennassar A, Vilata A, Puig S, Malvey J. *Ex vivo* fluorescence confocal microscopy for fast evaluation of tumour margins during Mohs surgery. *Br J Dermatol*. 2014;170:360–5.
4. Gareau DS, Li Y, Huang B, Eastman Z, Nehal KS, Rajadhyaksha M. Confocal mosaicing microscopy in Mohs skin excisions: feasibility of rapid surgical pathology. *J Biomed Opt*. 2008;13:054001.
5. Keena S, Que T. Research techniques made simple: noninvasive imaging technologies for the delineation of basal cell carcinomas. *J Invest Dermatol*. 2016;136:e33–8.
6. Villarreal-Martinez A, Bennassar A, Gonzalez S, Malvey J, Puig S. Application of *in vivo* reflectance confocal microscopy (RCM) and *ex vivo* fluorescence confocal microscopy (FCM) in most common subtypes of Basal Cell Carcinoma and correlation with histopathology. *Br J Dermatol*. 2018:0–3.
7. Sendín-Martín M, Bennassar A, Levitsky KL, Domínguez-Cruz JJ. *Ex vivo* confocal microscopy of basal cell carcinoma on a 3-color scale. *J Am Acad Dermatol*. 2018, <http://dx.doi.org/10.1016/j.jaad.2018.12.022>.
8. McGahon AJ, Martin SJ, Bissonnette RP, Mahboubi A, Shi Y, Mogil RJ, et al. The end of the (cell) line: methods for the study of apoptosis *in vitro*. *Methods Cell Biol*. 1995;46:153–85.

M. Sendín-Martín,<sup>a,\*</sup> J.J. Domínguez-Cruz,<sup>a</sup> K.-L. Levitsky,<sup>b</sup> J. Conejo-Mir Sánchez<sup>a</sup>

<sup>a</sup> *Unidad de Gestión Clínica de Dermatología, Hospital Universitario Virgen del Rocío, Sevilla, Spain*

<sup>b</sup> *Instituto de Biomedicina de Sevilla (IBiS), Sevilla, Spain*

\* Corresponding author.

E-mail address: [mercedessendin@gmail.com](mailto:mercedessendin@gmail.com)

(M. Sendín-Martín).

<https://doi.org/10.1016/j.adengl.2020.09.006>

1578-2190/ © 2020 AEDV. Published by Elsevier España, S.L.U. This is an open access article under the CC BY-NC-ND license (<http://creativecommons.org/licenses/by-nc-nd/4.0/>).

## Effectiveness of Certolizumab Pegol in the Treatment of Psoriasis in a Cohort of Patients With Psoriatic Arthritis<sup>☆</sup>



### Efectividad de certolizumab pegol en psoriasis en una cohorte de pacientes con artritis psoriásica

Dear Editor:

Certolizumab pegol (CZP) is an anti-TNF agent that has been recently approved for the treatment of moderate to severe plaque psoriasis in adults.<sup>1</sup> Rheumatologists, in contrast, have been using the drug in psoriatic arthritis since 2012.<sup>2</sup> To assess the effectiveness of CZP in plaque psoriasis, a retrospective observational, multicenter study was conducted in patients treated for psoriatic arthritis who had active plaque

psoriasis at the time of treatment initiation. The severity of psoriatic arthritis was assessed using the Disease Activity Score (DAS) 28 while plaque psoriasis was assessed with the 2011 modification of the Investigator Global Assessment (IGA mod 2011) scale (5-point physical global evaluation: 0, clear; 1, almost clear; 2, mild disease; 3, moderate disease; and 4, severe disease).<sup>3</sup>

The study included 22 adult patients, 16 women (73%) and 6 men (2%), from 4 hospitals in the same province of Spain. The mean duration of plaque psoriasis and psoriatic arthritis was 16 and 12 years, respectively. All patients were diagnosed with psoriatic arthritis according to the CASPAR criteria<sup>4</sup> and plaque psoriasis. Nineteen patients had (86%) peripheral psoriatic arthritis, 15 (68%) polyarticular psoriatic arthritis, 13 (59%) dactylitis, 12 (55%) axial psoriatic arthritis, and 12 (55%) unguis psoriasis. Eighteen patients (81%) had received prior biologic therapy, and the regimen for CZP was the usual one for psoriatic arthritis in all cases: 400 mg administered subcutaneously at weeks 0, 2, and 4, followed by 200 mg every 2 weeks.

On starting treatment, mean DAS28 was 5.79 and all patients had active plaque psoriasis (IGA mod 2011 ≥ 1): almost clear in 4 (18%), mild in 11 (50%), and moderate-severe in 7 patients (32%) (Table 1).

After 6 months treatment with CZP, mean DAS28 was 3.4 and the severity of plaque psoriasis improved significantly:

<sup>☆</sup> Please cite this article as: Reina D, Vidal D. Efectividad de certolizumab pegol en psoriasis en una cohorte de pacientes con artritis psoriásica. *Actas Dermosifiliogr*. 2020;155:704–705.