

8. Queisi MM, Zein M, Lamba N, Meese H, Foster CS. Update on ocular cicatricial pemphigoid and emerging treatments. *Surv Ophthalmol.* 2016;61:314–7.
9. Friedman J, Marcovich AL, Kleinmann G, Schattner A. Low-dose pulsed intravenous cyclophosphamide for severe ocular cicatricial pemphigoid in elderly patients. *Cornea.* 2014;33:1066–70.
10. Chan LS, Ahmed AR, Anhalt GJ, Bernauer W, Cooper KD, Elder MJ, et al. The first international consensus on mucous membrane pemphigoid: definition, diagnostic criteria, pathogenic factors, medical treatment, and prognostic indicators. *Arch Dermatol.* 2002;138:370–3.

O. Corral-Magaña*, D. Morgado-Carrasco, X. Fustà-Novell, P. Iranzo

Servicio de Dermatología, Hospital Clínic de Barcelona, Universitat de Barcelona, Barcelona, Spain

* Corresponding author.

E-mail address: ocorral@cst.cat (O. Corral-Magaña).

<https://doi.org/10.1016/j.adengl.2020.09.011>

1578-2190/ © 2020 Published by Elsevier España, S.L.U. on behalf of AEDV. This is an open access article under the CC BY-NC-ND license (<http://creativecommons.org/licenses/by-nc-nd/4.0/>).

Persistent Pruritic Papules AND Plaques and Flagellate Erythema as Presenting Manifestations of an Adult onset Still's Disease[☆]



Pápulas y placas pruriginosas persistentes y eritema flagelado como manifestaciones de una enfermedad de Still del adulto

Dear Editor:

A 21-year-old lady presented to our hospital with an 8-month history of persistent polyarthralgias, sore throat, intermittent fevers, and intense pruritic skin lesions over her face, upper back and chest, buttocks and extremities. Her past and family history was unremarkable and there was no history of any drug intake prior to onset of these symptoms. Cutaneous examination revealed erythematous and hyperpigmented, slightly scaly excoriated papules over forehead, upper back and chest and similar lesions in a linear manner over her buttocks and upper and lower extremities (Fig. 1). Laboratory investigations revealed leukocytosis (16,800/uL, 90% neutrophils) and elevated erythrocyte sedimentation rate [ESR] (40 mm/hr), ferritin (12,000 ng/mL) and C-reactive protein (8 mg/dL). Antistreptolysin titers, antinuclear antibody, rheumatoid factor, antineutrophil cytoplasmic antibodies, serum creatine phosphokinase, and aldolase were negative or within normal limits. Blood and urine cultures and other investigations for hepatitis B, C and A viruses, and chikungunya were all negative. Chest radiograph, echocardiogram, ultrasonog-

raphy of abdomen and pelvis, and electromyogram did not reveal any abnormality.

Histological examination revealed microabscesses in the stratum corneum with necrotic keratinocytes and perivascular and periadnexal inflammatory infiltrate (Fig. 2). Considering her clinical and histological findings, diagnosis of adult onset Still's disease (AOSD) was made and she was treated with oral steroid (1 mg/kg/day). There was significant resolution of her cutaneous lesions and other symptoms also ameliorated at the 4 weeks of follow-up.

Discussion

Still's disease is an idiopathic systemic inflammatory disorder with seronegative arthritis. Patients with 16 years of age or older having Still's disease are labeled as AOSD, whereas younger than 16 years are termed as Juvenile Still's disease.¹ Yamaguchi et al.² have led the major diagnostic criteria to diagnose AOSD, which include high spiking fevers $\geq 39^{\circ}\text{C}$ for at least 1 week, leukocytosis with neutrophilia, arthralgia for more than 2 weeks, and typical skin

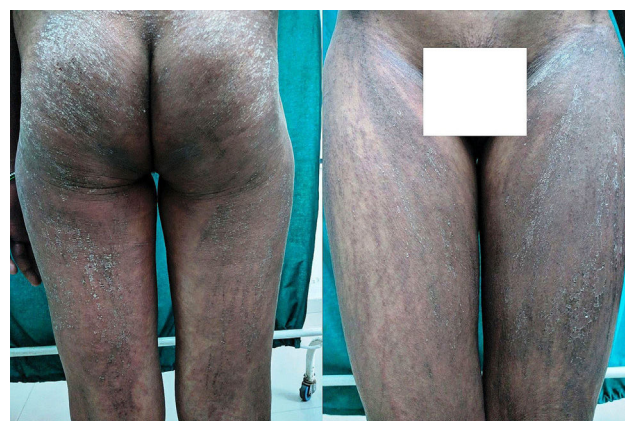

Figure 1 Flagellate erythema and linear papules with scales showing Koebner's phenomenon over buttocks (left panel) and thighs (right panel).

[☆] Please cite this article as: Pawar M, Zawar V, Kumavat S. Pápulas y placas pruriginosas persistentes y eritema flagelado como manifestaciones de una enfermedad de Still del adulto. *Actas Dermosifiliogr.* 2020;111:795–797.

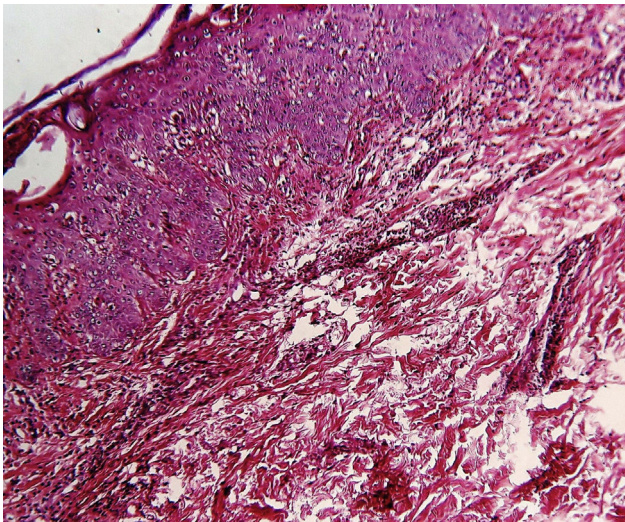


Figure 2 Histology of the skin showing microabscesses in the stratum corneum with necrotic keratinocytes and perivascular and periadnexal inflammatory infiltrate (Original magnification $\times 100$, Haematoxylin and Eosin stain).

eruption; whereas the minor criteria include sore throat, lymphadenopathy, splenomegaly, hepatic dysfunction, negative rheumatoid factor and antinuclear antibody. AOSD is diagnosed when five or more criteria (including 2 major criteria) are present in the patient, provided there is no evidence of infections, malignant conditions, and other rheumatologic diseases. However Sun NZ et al. have found the delayed association of malignancies (breast cancer and lymphoma) with AOSD, especially in patients having atypical cutaneous lesions.³

The classic rash of AOSD consists of an evanescent, non-pruritic salmon pink, morbilliform eruption on the trunk and/or extremities which appears simultaneously with fever spikes. The non-classic variant of the skin rash in AOSD which is characterized by pruritic papules and plaques with fine scales along with flagellate erythema located on the trunk, extremities, head and/or neck. Owing to its itchy nature, the linearity of this rash over especially over extremities may represent a Koebner phenomenon. Flagellate erythema have been observed in patients undergoing chemotherapy with bleomycin, peplomycin, docetaxel and trastuzumab and also in patients suffering from dermatomyositis, systemic lupus erythematosus, chikungunya fever and Parvovirus B19 infection and after the consumption of shiitake mushroom.⁴

The histopathologic findings of AOSD are nonspecific, which include mild superficial perivascular lymphocytic infiltrate with variable neutrophils, whereas the histopathology of atypical rash of AOSD include dyskeratosis or parakeratosis and necrotic keratinocytes in the upper layers of the epidermis extending into the stratum corneum and a sparse superficial dermal infiltrate containing neutrophils without vasculitis. In some cases dermal mucin deposits are present.⁵ Erythema multiforme is the proto-

type diagnosis within the histologic differential of necrotic keratinocytes, which also includes Stevens-Johnson syndrome, toxic epidermal necrolysis, lichen planus, lupus, and graft-versus-host disease. However in EM the necrotic keratinocytes are scattered throughout the epidermis, whereas in Still's disease they are situated in the upper epidermis.⁵

Other atypical skin lesions less commonly seen in AOSD include urticaria and urticaria-like eruptions, generalized non-pruritic persistent erythema, vesiculopustular eruptions, a widespread peau d'orange appearance of the skin and edema of the eyelids mimicking dermatomyositis.^{6,7} Recently few atypical forms of AOSD reported include neutrophilic urticarial dermatosis,⁸ brown macules on oral mucosa⁹ and generalised purpura.¹⁰

The majorities of patients of AOSD with atypical cutaneous lesions have high levels of ferritin and they often suffer from persistent and severe disease.³ Most patients respond to medium or high doses of glucocorticoids while those with severe and persistent disease need a more potent immunosuppressant drugs including methotrexate, azathioprine, cyclosporine A, hydroxychloroquin and IL-1 receptor antagonist.¹

Treating physician should be aware of the atypical cutaneous features of AOSD as it is a poor prognostic marker needing prompt diagnosis and aggressive treatment measures.

Funding

This work has not received any type of funding.

Conflict of interest

The authors declare that they have no conflict of interest.

Acknowledgment

Authors want to thank Dr. Asmita More, MD (Medicine), Dept. of Medicine, Dr. Vasantrao Pawar Medical College & Hospital & Research Center, Nashik, India for providing valuable inputs in this case.

References

1. Fautrel B. Adult-onset Still disease. *Best Pract Res Clin Rheumatol.* 2008;22:773.
2. Yamaguchi M, Ohta A, Tsunematsu T, Kasukawa R, Mizushima Y, Kashiwagi H, et al. Preliminary criteria for classification of adult Still's disease. *J Rheumatol.* 1992;19:424-30.
3. Sun NZ, Brezinski EA, Berliner J, Haemel A, Connolly MK, Gensler L, et al. Updates in adult-onset Still disease: atypical cutaneous manifestations and associations with delayed malignancy. *J Am Acad Dermatol.* 2015;73:294-303.
4. Cohen P. Trastuzumab-associated flagellate erythema: report in a woman with metastatic breast cancer and review of antineo-

- plastic therapy-induced flagellate dermatoses. *Dermatol Ther.* 2015;5:253–64.
5. Lee JY, Yang CC, Hsu MM. Histopathology of persistent papules and plaques in adult-onset Still's disease. *J Am Acad Dermatol.* 2005;52:1003–8.
 6. Affleck AG, Littlewood SM. Adult-onset Still's disease with atypical cutaneous features. *J Eur Acad Dermatol Venereol.* 2005;19:360–3.
 7. Narváez García FJ, Pascual M, López de Recalde M, Juárez P, Morales-Ivorra I, Notario J, et al. Adult-onset Still's disease with atypical cutaneous manifestations. *Medicine (Baltimore).* 2017;96:e6318.
 8. Nassereddine H, Fite C, Kottler D, Descamps V, Couvelard A, Marot L, et al. An atypical persistent eruption of adult-onset Still's disease with neutrophilic urticarial dermatosis-like dermal features: a case report and review of the literature. *J Cutan Pathol.* 2018;45:793–9.
 9. Brance ML, Neffen EL. Oral mucosa lesions as atypical manifestation of adult-onset Still's disease. *An Bras Dermatol.* 2018;93:271–3.
 10. Omigawa C, Hashimoto T, Hanafusa T, Namiki T, Igawa K, Yokozeki H. Generalized purpura as an atypical skin manifestation of adult-onset Still's disease in a patient with Behçet's disease. *Acta Derm Venereol.* 2018;98:452–3.

M. Pawar*, V. Zawar, S. Kumavat

Departamento de Dermatología, Dr. V. P. Facultad de Medicina, Hospital y Centro de Investigación, Nashik, India

* Corresponding author.

E-mail address: manojpawar624@yahoo.com (M. Pawar).

<https://doi.org/10.1016/j.adengl.2020.09.013>

1578-2190/ © 2020 Published by Elsevier España, S.L.U. on behalf of AEDV. This is an open access article under the CC BY-NC-ND license (<http://creativecommons.org/licenses/by-nc-nd/4.0/>).

Cutaneous Polyarteritis Nodosa in a Patient with Ulcerative Colitis[☆]



Poliarteritis nudosa cutánea en un paciente con colitis ulcerosa

Dear Editor:

Several cutaneous manifestations are occasionally observed in patients with inflammatory bowel disease (IBD); however, isolated cutaneous vasculitis is rare among those skin lesions. Both cutaneous small-vessel vasculitis and cutaneous polyarteritis nodosa (cPAN) are uncommon skin manifestations of IBD.¹ We present herein a case of cPAN in a patient with ulcerative colitis (UC).

A 33-year-old woman visited the dermatology clinic complaining of erythemas with tenderness on the bilateral lower extremities with numbness, which had appeared three months previously. She had been suffering from UC (pancolitis type) for 2.5 years, and had been treated with mesalazine (5-aminosalicylic acid). Intestinal conditions were well-controlled. Physical examination showed livedo racemosa with tender nodules involving the anterior and posterior aspects of both legs, abdomen, and forearms (Fig. 1). Laboratory data showed normal liver and renal function, and urinalysis was normal. Serum levels of C-reactive protein, complements, IgG, and rheumatoid factor were all within normal ranges, and antinuclear

antibody, antineutrophil cytoplasmic autoantibodies (MPO-ANCA, PR3-ANCA), anticardiolipin, and anti-β₂-glycoprotein 1 IgG antibody were all negative. Cryoglobulin was not detected. A biopsy specimen showed necrotizing vasculitis in the lower dermis without affecting neighboring tissues (Fig. 2a). Higher magnification revealed a crescent fibrinoid deposition in the vessel lumen infiltrated by neutrophils and lymphocytes (Fig. 2b). Perivascular inflammation was localized at the dermal-subcutis junction. Elastica van Gieson stain revealed partially disrupted internal elastic lamina (Fig. 2c). The patient was treated with low-dose prednisolone (up to 30 mg/day (0.6 mg/kg)), sarpogrelate hydrochloride (300 mg/day), and tocopherol nicotinate (300 mg/day); however, the numbness was resistant to therapy. Mini-pulse therapy (methylprednisolone 500 mg/day for 3 consecutive days) was effective for her numbness, which, however, relapsed after the discontinuation of medication because of pregnancy. Antiplatelet agents and vitamin E were re-started after delivery; however, she refused oral steroid therapy. Her numbness still remains.

The presented case developed small-sized arteritis (150 μm in diameter) at the dermo-subcutaneous junction. Elastica van Gieson stain revealed the arteritis, and vasculitis did not involve venous vessels. ANCA was negative, and detailed examination of the nose, respiratory tract, kidney and lung denied granulomatosis with polyangiitis and microscopic polyangiitis. Several triggers such as viral infection and drugs, or systemic diseases are occasionally associated with cPAN. Leukocytoclastic vasculitis associated with IBD is suggested to be caused by circulating immune complex.^{2,3} Only several cases of cPAN associated with IBD have been reported to date; however, as compared with Crohn's disease, cases of UC are rarely reported. The rea-

[☆] Please cite this article as: Hiraiwa T, Yamamoto T. Poliarteritis nudosa cutánea en un paciente con colitis ulcerosa. *Actas Dermosifiliogr.* 2020;111:797–799.