

## IMAGES IN DERMATOLOGY

### Oral Lesions as the Only Manifestation of Secondary Syphilis<sup>☆</sup>



### Lesiones orales como única manifestación de sífilis secundaria

L. González-Ruiz,<sup>\*</sup> M.P. Sánchez-Camínero, M. Franco-Muñoz, C. Ramos-Rodríguez

*Servicio de Dermatología y Venereología, Hospital General Universitario de Ciudad Real, Ciudad Real, Spain*

A 26-year-old man with a history of risky sexual behavior with men was seen at the emergency department forodynophagia and dysphagia that appeared 2 months earlier and progressively worsened. He had no other lesions of the skin or mucosa or associated systemic manifestations. A physical examination revealed whitish verrucous plaques on the tonsils, soft palate, uvula, and the dorsum of the tongue (Fig. 1), associated with bilateral mobile cervical lymphadenopathy. Luetic serology was positive (rapid plasma reagin, 1:16; fluorescent treponemal antibody, positive). Blood tests for human immunodeficiency virus and hepatitis C virus were negative. A tonsil biopsy showed acanthosis with lymphoplasmacytic infiltration of the chorion and neutrophil exocytosis. Anti-*Treponema* immunohistochemistry revealed abundant spirochetes between the keratinocytes of the mucosa. Spirochetes located close to the superficial vessels were observed in tissue stained with Warthin Starry stain. Based on these data, the patient was diagnosed with syphilis and was treated with intramuscular penicillin G benzathine (2.4 million IU). Clinical improvement was observed after 2 weeks of treatment.

Syphilis is a sexually transmitted disease caused by *Treponema pallidum*. The secondary form can produce very

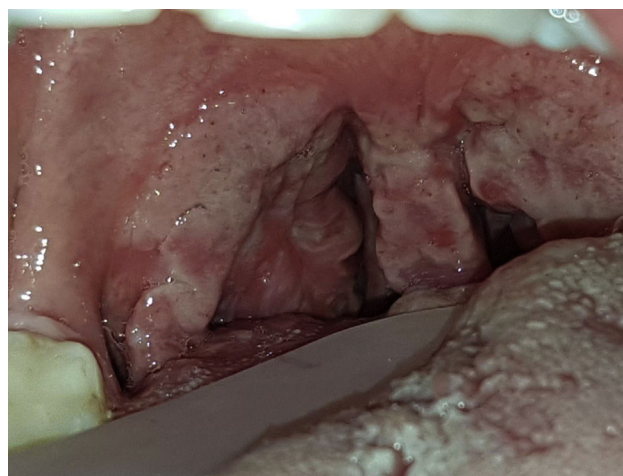


Figure 1

varied mucocutaneous signs and is the stage during which oral lesions have been most frequently described. Cases in which isolated oral lesions constitute the only clinical manifestation of the disease are rare. Given the increasing incidence of this disease in recent years, such cases pose a serious diagnostic challenge.

### Conflicts of Interest

The authors declare that they have no conflicts of interest.

<sup>☆</sup> Please cite this article as: González-Ruiz L, Sánchez-Camínero MP, Franco-Muñoz M, Ramos-Rodríguez C. Lesiones orales como única manifestación de sífilis secundaria. Actas Dermosifiliogr. 2020;111:876–876.

<sup>\*</sup> Corresponding author.

E-mail address: [gruizlucia@gmail.com](mailto:gruizlucia@gmail.com) (L. González-Ruiz).