

Pseudoepitheliomatous Hyperplasia: An Uncommon Reaction in Tattoos[☆]



Hiperplasia pseudoepiteliomatosa: una reacción infrecuente de los tatuajes

To the Editor:

The growth in popularity of tattooing in recent decades has coincided with an increase in the number of articles describing adverse effects associated with tattooing.

Complications associated with tattoos include cutaneous and systemic infectious processes, inflammatory reactions with varied histological patterns, the appearance of benign or malignant skin tumors in tattooed areas of skin, and various dermatoses in tattooed areas resulting from isomorphic phenomena.¹

A 39-year-old man consulted for an itchy rash in the red-ink areas of a tattoo completed 1 month earlier. Physical examination revealed well-defined, firm, raised, erythematous hyperkeratotic lesions coinciding with the areas of red ink (Fig. 1). Dermoscopy showed rounded or oval-shaped

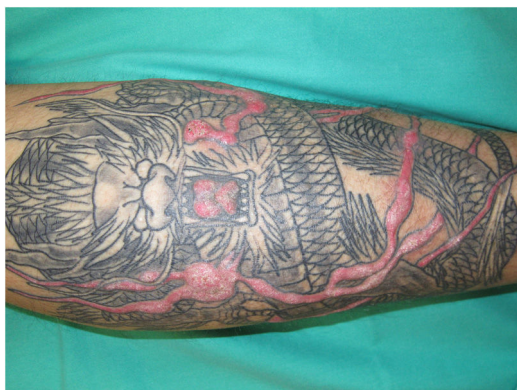

Figure 1 Tattoo on the left leg. Well-defined raised, thickened lesions are evident in the red-colored areas of skin, with no surrounding inflammatory reaction.

areas of variable size with an erythematous center and a pinkish periphery, separated from one other by yellowish hyperkeratotic scales (Fig. 2). Histology showed marked acanthosis and epidermal papillomatosis without atypical cells, hyperkeratosis and areas of parakeratosis, and intracellular and extracellular deposits of red pigment in the dermis accompanied by a predominantly lymphohistiocytic infiltrate (Fig. 3). Culture of a biopsy sample for fungi, bacteria, and mycobacteria was negative. The results of patch and prick tests were negative.

The patient was diagnosed with pseudoepitheliomatous hyperplasia in skin areas tattooed with red ink.

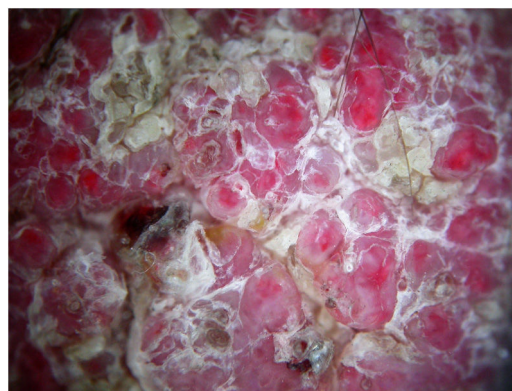

Figure 2 Dermoscopy image. Rounded and oval structures of variable size with an erythematous center and pinkish periphery, separated from one other by yellowish scales.

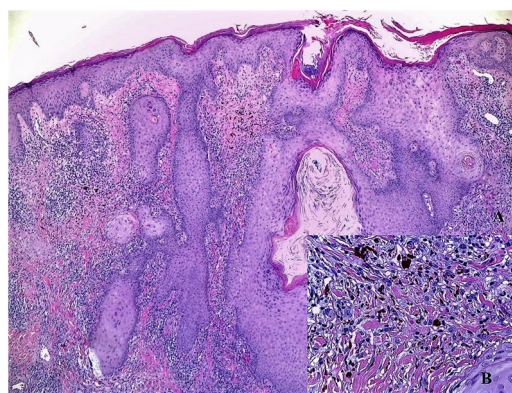


Figure 3 Histopathological image. A, Epidermal hyperplasia, hyperkeratosis of the corneal layer, and pigment deposition in the superficial dermis accompanied by inflammatory infiltrate (hematoxylin-eosin, original magnification $\times 4$). B, Detail of pigment deposits inside histiocytes and extracellular cells, accompanied by lymphohistiocytic infiltrate (hematoxylin-eosin, original magnification $\times 40$).

He began treatment with high-potency topical corticosteroids under occlusion, without improvement. Two subsequent subcutaneous corticosteroid infiltrations slightly improved the pruritus, but had no effect on the lesions. CO₂ laser treatment was scheduled, but the patient failed to attend the appointment.

Among complications of tattoos, pseudoepitheliomatous hyperplasia is a rare reaction. It consists of irregular hyperplasia of the epidermis with no atypia and little mitotic activity, accompanied by dermal inflammatory infiltrate with a reactive histological pattern in response to the damage caused.²

Because only isolated cases have been described and a few short series of patients published,²⁻⁹ there are limited data on this entity and its response to treatment. Among the cases described, more than half occurred in areas tattooed with red ink. Most, including the present case, occurred within 3 months of receiving the tattoo. This temporal association can aid diagnosis.

It is important to differentiate this lesion from true neoplasms such as squamous cell carcinoma, verrucous carcinoma, keratoacanthoma, and viral warts.⁹⁻¹¹

[☆] Please cite this article as: Conejero R, Conejero C, Alcalde V, García-Latasa de Aranibar JA. Hiperplasia pseudoepiteliomatosa: una reacción infrecuente de los tatuajes. *Actas Dermosifiliogr.* 2020;111:896-897.

Treatments described include high-potency topical corticosteroids, which were effective in one case,² and surgical excision (3 patients),^{8,9} which was not considered in the present case owing to the extent of the lesions. Successful treatment with CO₂ laser has been recently reported.⁷ In several cases, patients have been lost to follow-up.

We present a case of pseudoepitheliomatous hyperplasia as a reaction to red tattoo ink. The literature on this characteristic reaction is scarce. This is the first such case described in Spain, and the first for which accompanying dermoscopic images are provided.

Conflicts of Interest

The authors declare that they have no conflicts of interest.

References

- Mataix J, Silvestre JF. Reacciones cutáneas adversas por tatuajes y piercings. *Actas Dermosifiliogr*. 2009;100:643–56.
- Kluger N, Durand L, Minier-Thoumin C, Plantier F, Cotton H, Berteloot E, et al. Pseudoepitheliomatous epidermal hyperplasia in tattoos: Report of three cases. *Am J Clin Dermatol*. 2008;9:337–40.
- Broussard-Steinberg C, Zemtsov A, Strausburg M, Zemtsov G, Warren S. Lichenoid reaction pattern with pseudoepitheliomatous hyperplasia - a rare tattoo reaction: A case report and review of the literature. *Case Rep Dermatol*. 2018;5:268–73.
- Tamaro A, Raffa S, Petrigliano N, Zollo V, Gelormini E, Moliterni E, et al. Marked pseudoepitheliomatous hyperplasia secondary to a red-pigmented tattoo: A case report. *J Eur Acad Dermatol Venereol*. 2018;32:e272–3.
- Kiss F, May K, Piguet V. Image Gallery: Pseudoepitheliomatous hyperplasia, a rare tattoo reaction. *Br J Dermatol*. 2016;175:e112.
- Conti R, Bassi A, Brusino N, Campolmi P, Cannarozzo G, Maio V, Moretti S. Pseudoepitheliomatous hyperplasia in a tattoo. *G Ital Dermatol Venereol*. 2017;152:71–2.
- Breza TS Jr, O'Brien AK, Glavin FL. Pseudoepitheliomatous hyperplasia: An unusual tattoo reaction. *JAMA Dermatol*. 2013;149:630–1.
- Cui W, McGregor DH, Stark SP, Uluarac O, Mathur SC. Pseudoepitheliomatous hyperplasia - an unusual reaction following tattoo: Report of a case and review of the literature. *Int J Dermatol*. 2007;46:743–5.
- Balfour E, Olhoffer I, Leffell D, Handerson T. Massive pseudoepitheliomatous hyperplasia: An unusual reaction to a tattoo. *Am J Dermatopathol*. 2003;25:338–40.
- Kluger N. Issues with keratoacanthoma, pseudoepitheliomatous hyperplasia and squamous cell carcinoma within tattoos: A clinical point of view. *J Cutan Pathol*. 2009;37:812–3.
- Kazlouskaya V, Junkins-Hopkins JM. Pseudoepitheliomatous Hyperplasia in a red pigment tattoo: A separate entity or hyper-trophic lichen planus-like reaction? *J Clin Aesthet Dermatol*. 2015;8:48–52.

R. Conejero,^{a,*} C. Conejero,^b V. Alcalde,^a
J. García-Latasa de Aranibar^a

^a *Departamento de Dermatología, Hospital Royo Villanova, Zaragoza, Spain*

^b *Unidad de Dermatología, Centro Médico Millenium, Zaragoza, Spain*

* Corresponding author.

E-mail address: raquel.conejero@hotmail.com
(R. Conejero).

<https://doi.org/10.1016/j.adengl.2020.10.021>

1578-2190/ © 2020 AEDV. Published by Elsevier España, S.L.U. This is an open access article under the CC BY-NC-ND license (<http://creativecommons.org/licenses/by-nc-nd/4.0/>).

Treatment of Localized Cutaneous Leishmaniasis With Intralesional Meglumine Antimoniate and Photodynamic Therapy[☆]



Tratamiento de la leishmaniasis localizada mediante el antimonio de meglumina intralesional y la terapia fotodinámica

To the Editor:

Leishmaniasis, a sandfly vector-borne protozoan infection, encompasses a wide spectrum of clinical presentations. The most common form of Leishmaniasis is cutaneous leishmaniasis.¹ It affects primarily adults between the third

and 5th decades of life and the lesions are commonly located on exposed body parts. The diverse clinical spectrum of CL depends upon various factors, such as the specific causative strain, geographic location, parasitic load and host immune response.

Case Report

A 31-year-old Portuguese male presented with a 4-month history of a solitary, asymptomatic, 4 × 2 cm large, indurated crusty plaque on his forehead (Fig. 1). His medical history was unremarkable, except for early latent syphilis treated 1 year ago with good serological response. His family history was unremarkable. He denied any prescribed or over-the-counter medication. His immunization status was up-to-date and his social and travel history were significant for a recent travel to Mexico about 5 months ago.

The skin biopsy revealed a dermal diffuse inflammatory infiltrate composed by lymphocytes and histiocytes. Leishmania amastigotes were identified in the cytoplasm of dermal macrophages.

The physical examination was otherwise normal. Otorhinolaryngologic endoscopy, bone marrow aspirate and abdominal ultrasound were performed to exclude mucous

[☆] Please cite this article as: Costin A, Bonito F, Alves J, Barreiros H. Tratamiento de la leishmaniasis localizada mediante el antimonio de meglumina intralesional y la terapia fotodinámica. *Actas Dermosifiliogr*. 2020;111:897–899.