

PRACTICAL DERMOSCOPY

Erythematous Scaly Plaque[☆]



Placa eritemato descamativa

Case Description

A 73-year-old woman with a history of systemic lupus erythematosus (SLE), predominantly affecting the joints, and palmoplantar pustulosis visited our department with a plaque of alopecia on the scalp that had appeared a year earlier, coinciding with an episode of SLE (Fig. 1).

[[?]]What is your Diagnosis?

Diagnosis

Tinea capitis.

Comment

We report the case of a 73-year-old woman with a history of alopecia plaques that had appeared a year earlier.

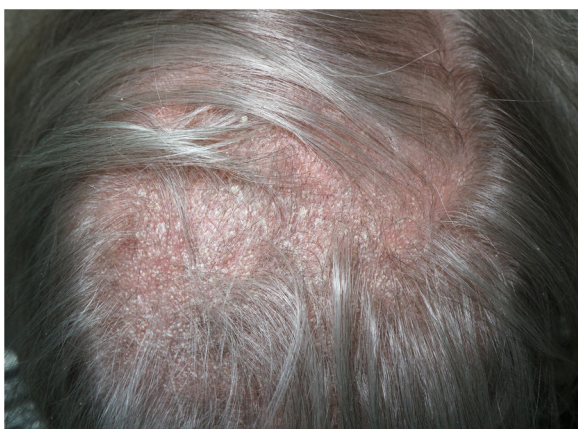

Figure 1 Alopecia plaque with diffuse scaling and underlying erythema.

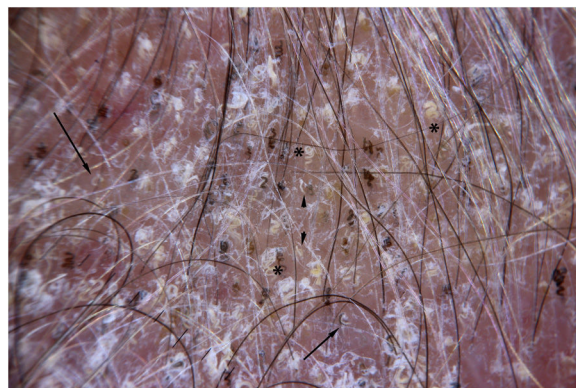


Figure 2 Dermoscopy showing comma hairs (arrow) and curly hairs (*) associated with broken hairs (arrow tip).

The plaques of alopecia have poorly demarcated edges and intense, thick desquamation. A polarized-light dermoscopy study revealed abundant comma hairs (arrow) and curly hairs (*) associated with broken hairs (arrow tip) and intense desquamation (Fig. 2).

The presence of these dermatoscopic structures led to the clinical suspicion of tinea capitis, which was subsequently confirmed from a culture of scales from the lesion, from which *Microsporum canis* was isolated. Treatment was instated with itraconazole at a dosage of 100 mg per day for a month, with resolution of the lesions.

Comma hairs and broken hairs were initially reported as markers for tinea capitis due to *Microsporum canis*.¹ Subsequent publications described corkscrew hairs in infections by *Microsporum* and in infections by *Trichophyton*.^{2,3}

The main differential diagnoses include other scaly erythematous skin disorders, such as seborrheic dermatitis, psoriasis, lupus erythematosus discoides, and lichen planopilaris. Lupus discoides is characterized by the presence of red spots and follicular plugs, which subsequently evolve into the loss of follicular ostia. Lichen planopilaris is characterized by erythema and perifollicular hyperkeratosis that evolves into erythematous areas without follicular ostia.⁴ Psoriasis of the scalp is characterized by its vascular pattern on dermatoscopic examination, with forked or looped vessels.⁵

Tinea capitis is characterized by broken hairs, comma hairs and corkscrew hairs associated with desquamation of the scalp. This pattern is useful for the differential diagnosis

[☆] Please cite this article as: Vilas Boas P, Hernández-Aragües I, Baniandrés-Rodríguez O. Placa eritemato descamativa. Actas Dermo-sifiliogr. 2021;112:169–170.

with other scaly erythematous disorders of the scalp, such as lupus discoides or psoriasis.

Conflicts of Interest

The authors declare that they have no conflicts of interest.

References

1. Slowinska M, Rudnicka L, Schwartz RA, Kowalska-Oledzka E, Rakowska A, Sicinska J, et al. Comma hairs: a dermatoscopic marker for tinea capitis: a rapid diagnostic method. *J Am Acad Dermatol.* 2008;59 5 Suppl:577–79.
2. Hughes R, Chiaverini C, Bahadoran P, Lacour J-P. Corkscrew hair: a new dermoscopic sign for diagnosis of tinea capitis in black children. *Arch Dermatol.* 2011;147:355–6.
3. Arenas R, Torres E, Amaya M, Rivera ER, Espinal A, Polanco M, et al. [Emergence of *Microsporum audouinii* and *Trichophyton tonsurans* as causative organisms of tinea capitis in the Dominican Republic]. *Actas Dermosifiliogr.* 2010;101:330–5.
4. Duque-Estrada B, Estrada BD, Tamler C, Sodr e CT, Barcaui CB, Pereira FBC. Dermoscopy patterns of cicatricial alopecia resulting from discoid lupus erythematosus and lichen planopilaris. *An Bras Dermatol.* 2010;85:179–83.
5. Kim G-W, Jung H-J, Ko H-C, Kim MB, Lee WJ, Lee SJ, et al. Dermoscopy can be useful in differentiating scalp psoriasis from seborrheic dermatitis. *Br J Dermatol.* 2011;164:652–6.

P. Vilas Boas,* I. Hernandez-Arag es,
O. Baniandr es-Rodr guez

Servicios de Dermatolog a, Hospital General Universitario Gregorio Mara n, Madrid, Spain

*Corresponding author.

E-mail address: Pedro.22.pvb@gmail.com (P. Vilas Boas).