



ACTAS Dermo-Sifiliográficas

Full English text available at
www.actasdermo.org



BRIEF COMMUNICATION

Staphylococcus lugdunensis Skin Infection: Report of 16 Cases[☆]



A.J. García-Malinis,^{a,*} A. Milagro,^b L. Torres Sopena,^c Y. Gilaberte^d

^a Unidad de Dermatología, Hospital San Jorge, Huesca, Spain

^b Servicio de Microbiología, Hospital Universitario Miguel Servet, Zaragoza, Spain

^c Servicio de Microbiología, Hospital San Jorge, Huesca, Spain

^d Servicio de Dermatología, Hospital Universitario Miguel Servet, Zaragoza, Spain

KEYWORDS

Staphylococcus lugdunensis;
Coagulase-negative staphylococci;
Skin infection

Abstract

Introduction and objective: *Staphylococcus lugdunensis* belongs to the group of coagulase-negative staphylococci. The aim of this report was to review the clinical and microbiologic features of cases of *S. lugdunensis* skin infections.

Material and methods: Observational study of all cases of skin infections in which *S. lugdunensis* was isolated by the microbiology department of Hospital General San Jorge in Huesca, Spain, between 2009 and 2016.

Results: We studied the cases of 16 patients. The most frequent site of infection was the inguinal-perineal region (n = 6, 37.5%), and pustules were the most common presentation (n = 5, 31.3%). Response to treatment was good in 87.6% of the patients (n = 14). However, infection recurred in 3 patients, 2 of whom were on anti-TNF therapy.

Conclusions: *S. lugdunensis* should be considered a possible cause of infection when it is isolated in both skin and subcutaneous tissues, especially in patients on biologic therapies.

© 2020 AEDV. Published by Elsevier España, S.L.U. This is an open access article under the CC BY-NC-ND license (<http://creativecommons.org/licenses/by-nc-nd/4.0/>).

PALABRAS CLAVE

Staphylococcus lugdunensis;
Estafilococo
coagulasa negative;
Infección cutánea

Infección cutánea por *Staphylococcus lugdunensis*: presentación de 16 casos

Resumen

Introducción y objetivo: *Staphylococcus lugdunensis* pertenece al grupo de los estafilococos coagulasa negativos. El objetivo del estudio es revisar las características clínicas y microbiológicas de los pacientes diagnosticados de una infección cutánea por *S. lugdunensis*.

Material y métodos: Estudio observacional retrospectivo de todos los casos de infecciones cutáneas en las que se aisló *S. lugdunensis* diagnosticados entre 2009 y 2016 en el Servicio de Microbiología del Hospital San Jorge de Huesca.

[☆] Please cite this article as: García-Malinis AJ, Milagro A, Torres Sopena L, Gilaberte Y. Infección cutánea por *Staphylococcus lugdunensis*: presentación de 16 casos. Actas Dermosifiliogr. 2021;112:261–265.

* Corresponding author.

E-mail address: ajgarciam@aragon.es (A.J. García-Malinis).

Resultados: Se incluyeron 16 pacientes. La localización más frecuente fue la zona inguinoperineal (n = 6, 37,5%) y la forma de presentación más habitual fueron las pústulas (n = 5, 31,3%). El 87,6% de los pacientes (n = 14) mostraron buena respuesta al tratamiento; sin embargo, 3 pacientes recurrieron. De ellos, 2 estaban en tratamiento con un anti-TNF.

Conclusión: *S. lugdunensis* debería considerarse el posible agente causal de la infección cuando se aísla tanto en piel como en tejido celular subcutáneo, especialmente en pacientes que están recibiendo tratamiento biológico.

© 2020 AEDV. Publicado por Elsevier España, S.L.U. Este es un artículo Open Access bajo la licencia CC BY-NC-ND (<http://creativecommons.org/licenses/by-nc-nd/4.0/>).

Introduction

Staphylococcus lugdunensis belongs to the group of coagulase-negative staphylococci (CoNS). First described in 1988 by Freney in Lyon, France,¹ this emerging pathogen is more virulent than other CoNS and can cause infections with high mortality.²

S. lugdunensis is a commensal CoNS in areas with apocrine glands,³ and causes infections of the skin and subcutaneous cell tissue, generally resulting in abscess formation.⁴ Patients with predisposing conditions such as diabetes or tumors are at greater risk of acquiring *S. lugdunensis* infection, although deep and superficial infections have also been described in healthy individuals,⁵ in which the skin is the main point of entry.

In this study we sought to review the clinical and microbiological characteristics of patients in our center who were diagnosed with skin infections from which *S. lugdunensis* was isolated, as well as the treatments applied and the course of the infection.

Material and Methods

We performed a retrospective observational study of all cases of skin infections for which microbiological culture revealed the presence of *S. lugdunensis* at the Microbiology Service of Hospital San Jorge de Huesca between 2009 and 2016.

The following variables were recorded: age; sex; associated systemic diseases and their treatment; location and type of skin lesion; treatment and evolution; and other microorganisms concomitantly isolated from the same lesion.

Microbiological diagnosis was based on culture of the samples in standard media. Microorganism identification and antibiotic sensitivity tests were performed using MicroScan® (Beckman Coulter), applying the criteria of the Clinical and Laboratory Standards Institute (CLSI). Identification was confirmed using the ornithine decarboxylase (ODC) test and the pyrrolidonyl-arylamidase (PYR) test (Rosco Diagnostica A/S, Denmark).

Results

Table 1 summarizes the characteristics of the sample population, which consisted of 16 patients (9 women, 7 men)

with a mean age of 52.19 years (range, 19–83 y). Six patients (37.5%) had underlying systemic diseases.

The most commonly affected location was the inguinal/perineal area (n=6, 37.5%), followed by the lower extremities (n=3, 18.8%). The most common clinical presentations were pustules (n=5, 31.3%), intertrigo-type lesions (n=5, 31.3%), and abscessed cysts (n=3, 18.8%) (**Fig. 1A**). The presence of an abscess was reported in only 1 patient.

S. lugdunensis was the only pathogen isolated in cultures from 11 (68.8%) of the 16 patients. The microorganism most frequently isolated concomitantly with *S. lugdunensis* was *Escherichia coli* (n=2, 12.5%). A curious feature of the *S. lugdunensis* samples isolated on blood agar was a characteristic smell of cured pork.

An antibiogram performed for all samples revealed antibiotic sensitivity of all *S. lugdunensis* isolates, except for one that showed resistance to clindamycin, erythromycin, fosfomicin, and tetracycline. Fungal culture was performed in 6 patients, 5 of whom had suspected intertrigo.

Oral treatment, the most common of which was oral penicillin, was received by 75% of patients (n=12). Topical treatment was received by 56.3% (n=9) of patients, of whom 5 received associated oral antibiotic treatment. Mupirocin (n=3, 18.8%) and erythromycin (n=2, 12.5%) were the most frequently prescribed topical antibiotics among patients who received topical treatment. Of the 5 patients with intertrigo-like lesions, only one presented coinfection (with *Candida albicans* and *Trichophyton rubrum*), which responded adequately to oral terbinafine. In cases involving abscesses or abscessed cysts, the lesions were drained.

A good treatment response was observed in 87.6% of patients (n=14). Two patients, both of whom had *E. coli* coinfections, did not respond to treatment. Three patients who showed a good initial response experienced recurrence (2 episodes each). Of these 3 patients, 2 were being treated with anti-tumor necrosis factor (TNF) agents.

Discussion

Despite forming part of the skin microbiota, *S. lugdunensis* is of great pathogenic importance and, like *Staphylococcus aureus*, can cause invasive, highly virulent community and nosocomial infections.⁶

In our series, skin infections caused by *S. lugdunensis* were mostly mild and predominantly affected the inguinal/perineal area. The most frequent clinical presen-

Table 1 Clinical Characteristics, Coinfection Status, Treatment, and Infection Course

Case	Age, y	Sex	Lesion Location	Lesion Type	Associated Diseases	Biological Treatment	Concomitant Infections	Oral Treatment	Topical Treatment	Treatment Response
1	83	Female	Lower limbs	Pustules	Digestive mastocytosis	No	<i>Corynebacterium striatum/amycolatum</i>	Cloxacillin	No	Good response
2	45	Male	Abdomen	Surgical wound	No	No	No	Amoxicillin	Mupirocin	Good response
3	38	Female	Lower limbs	Intertrigo	No	No	<i>Candida albicans</i> and <i>Trichophyton rubrum</i>	Terbinafine	No	Good response
4	79	Male	Inguinal/perineal and gluteal regions	Pressure ulcer	No	No	<i>E coli</i>	Amoxicillin	Mupirocin	No response
5	68	Female	Inguinal/perineal and gluteal regions	Abscess	Psoriasis	Yes	No	Doxycycline	Fusidic acid and betamethasone	Good initial response, subsequent recurrence
6	40	Female	Lumbar region	Abscessed cyst	No	No	No	Cloxacillin	No	Good response
7	45	Female	Inguinal/perineal and gluteal regions	Pustules	Hidradenitis	No	No	Clindamycin	No	Good initial response, subsequent recurrence
8	19	Male	Inguinal/perineal and gluteal regions	Pustules	Hidradenitis	No	No	Clindamycin and rifampicin	No	Good response
9	40	Female	Abdomen	Pustules	Rheumatoid arthritis	Yes	No	Amoxicillin-clavulanic acid	No	Good initial response, subsequent recurrence
10	53	Male	Lumbar region	Abscessed cyst	No	No	No	Cloxacillin	No	Good response
11	41	Male	Inguinal/perineal and gluteal regions	Intertrigo	Hepatitis A virus	No	<i>Streptococcus agalactiae</i> (group B)	No	Erythromycin	Good response
12	61	Male	Lower limbs	Pustules	No	No	No	Cloxacillin	Mupirocin	Good response
13	67	Female	Inguinal/perineal and gluteal regions	Intertrigo	No	No	No	No	Erythromycin	Good response
14	65	Female	Submammary region	Intertrigo	No	No	No	No	Fusidic acid	Good response
15	35	Female	Chest	Abscessed cyst	No	No	No	Amoxicillin-clavulanic acid	Fusidic acid and betamethasone	Good response
16	56	Male	Axillae	Intertrigo	No	No	<i>E coli</i>	No	Hydrocortisone and miconazole	No response

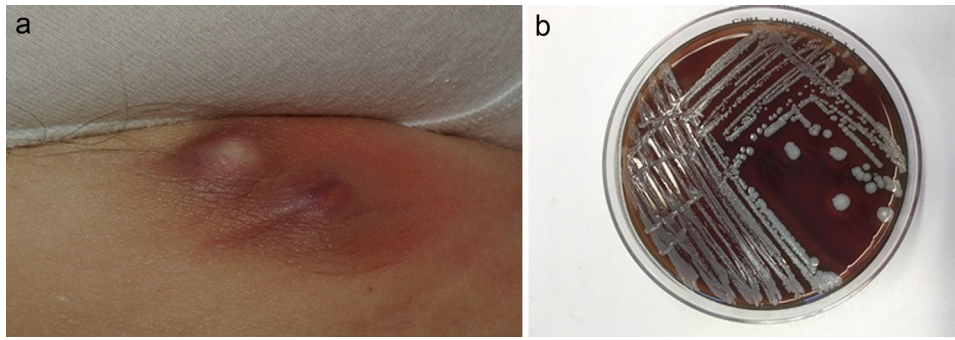


Figure 1 A, Abscess caused by *S lugdunensis* in the inguinal region of a patient receiving adalimumab treatment. B, *S lugdunensis* colony growing on blood agar.

tations were intertrigo-like and pustular lesions. Recurrence was observed only in patients treated with anti-TNF agents.

The majority of *S lugdunensis* infections reported in the literature present as infections of the skin or subcutaneous tissue that result in abscess formation.^{7,8} Among 29 cases recently described by Zaaroura et al,⁹ the most frequent presentation was pustulosis/folliculitis (16 patients). In line with those findings, pustules and intertrigo were the most common presentations (5 cases of each) in our series.

The most frequently affected locations in our study population coincided with those reported in previous studies. These include the inguinal/perineal area,^{7,10} abdomen, lower extremities,¹¹ and mammary region,⁵ all of which are areas in which *S lugdunensis* is a commensal microorganism.

Skin infections due to *S lugdunensis* usually respond to antibiotic treatment.¹¹ Unlike other CoNS, *S lugdunensis* is generally sensitive to penicillins owing to its low levels of beta-lactamase production, and less than 5% of isolates are resistant to oxacillin.⁵ In cases of simple skin abscesses, therapeutic guidelines recommend incision and drainage of the lesion; first-line antibiotic treatment is not indicated. In complicated cases, drainage and oral treatment with narrow-spectrum antibiotics such as cefadroxil, cephalexin, or cloxacillin is recommended. In cases of folliculitis, the drugs of choice are mupirocin and fusidic acid, combined with hygiene measures. In patients with extensive folliculitis, addition of an oral antibiotic (cefadroxil, cephalexin, or cloxacillin) is recommended.¹² The most common treatment reported in the literature is topical antibiotic therapy, combined with oral antibiotics in more complicated cases.¹³

Because *S lugdunensis* colonizes the skin, it is important to determine when this microorganism becomes a pathogen. One of the cases in our series was a patient with *T rubrum* and *C albicans* coinfection who responded favorably to terbinafine. This is a clear example of *S lugdunensis* merely acting as a colonizing agent. Co-infection with *E coli* was detected in the 2 patients in which no treatment response was observed, suggesting that *E coli*, and not *S lugdunensis*, was the pathogen responsible for the infection. The pathogenic capacity of *S lugdunensis* in osteoarticular infections has been corroborated prospectively.¹⁴ However, caution is advised when interpreting single positive samples from skin or subcutaneous tissue or from known niches of this CoNS.¹⁵

S lugdunensis infection that responded well to antibiotic treatment has been described in a patient with psoriasis

and psoriatic arthritis who was being treated with adalimumab and methotrexate.¹⁶ In our series, 2 of the patients who experienced lesion recurrence were being treated with an anti-TNF agent, specifically adalimumab. One of the patients switched to adalimumab after showing a poor response to antibiotic treatment. Skin infection is one of the most frequently reported side effects of anti-TNF drugs.¹⁷ This is because TNF- α is a pro-inflammatory cytokine that plays an important role in innate immunity, and therefore its inhibition can increase the risk of infections, especially those of bacterial origin.¹⁸

S lugdunensis can be easily identified in the laboratory, provided that its possible presence is taken into consideration. Incubation on blood agar for 18 to 24 hours gives rise to colonies with weak β -hemolysis, which increases after 48 hours (Fig. 1B). Two tests are required to identify this bacterium: the ODC and PYR tests. Both are positive in the case of *S lugdunensis*, unlike other CoNS. Matrix-assisted laser desorption ionization-time of flight mass spectrometry (MALDI-TOF MS) provides a rapid and cost-effective means of identifying *S lugdunensis*.¹⁹ It has a sensitivity and specificity close to 100% for the identification of CoNS, especially *S lugdunensis*.²⁰ The present series was performed before the recent acquisition of a MALDI-TOF system by our hospital.

The destructive nature of *S lugdunensis*, its great virulence, and its ability to cause suppurative infections more than justify active surveillance for this microorganism. In the past *S lugdunensis* was occasionally identified as a causal agent of human pathology, but is now detected with increasing frequency. This may be due to better understanding of its microbiological characteristics, a higher index of clinical suspicion, and the use of MALDI-TOF, which has enabled characterization of numerous CoNS species that were previously identified simply as coagulase-negative staphylococci or *Staphylococcus* species.⁵

S lugdunensis can be considered a pathogenic microorganism of skin in certain circumstances, depending on the clinical picture and affected location, and in patients with systemic or local risk factors, such as those in our series who were treated with anti-TNF agents.

Funding

This study did not receive specific funding from any public sector, private sector, or nonprofit entities.

Conflicts of Interest

The authors declare that they have no conflicts of interest.

References

1. Freney J, Brun Y, Bes M, Meugnier H, Grimont F, Grimont PAD, et al. *Staphylococcus lugdunensis* sp. nov. and *Staphylococcus schleiferi* sp. nov., two Species from Human Clinical Specimens. *Int J Syst Evol Microbiol*. 1988;38:168–72.
2. Yeh C-F, Chang S-C, Cheng C-W, Lin J-F, Liu T-P, Lu J-J. Clinical features, outcomes, and molecular characteristics of community- and health care-associated *Staphylococcus lugdunensis* infections. *J Clin Microbiol*. 2016;54:2051–7.
3. Böcher S, Tønning B, Skov RL, Prag J. *Staphylococcus lugdunensis*, a common cause of skin and soft tissue infections in the community. *J Clin Microbiol*. 2009;47:946–50.
4. van der Mee-Marquet N, Achard A, Mereghetti L, Danton A, Minier M, Quentin R. *Staphylococcus lugdunensis* infections: high frequency of inguinal area carriage. *J Clin Microbiol*. 2003;41:1404–9.
5. Papapetropoulos N, Papapetropoulou M, Vantarakis A. Abscesses and wound infections due to *Staphylococcus lugdunensis*: report of 16 cases. *Infection*. 2013;41:525–8.
6. Cercenado E. [*Staphylococcus lugdunensis*: a unique coagulase-negative staphylococcus]. *Enferm Infecc Microbiol Clin*. 2009;27:139–42.
7. Bellamy R, Barkham T. *Staphylococcus lugdunensis* infection sites: predominance of abscesses in the pelvic girdle region. *Clin Infect Dis*. 2002;35:E32–34.
8. Heldt Manica LA, Cohen PR. Cutaneous *Staphylococcus lugdunensis* infection: an emerging bacterial pathogen. *Dermatol Online J*. 2018;24.
9. Zaaroura H, Geffen Y, Bergman R, Avitan-Hersh E. Clinical and microbiological properties of *Staphylococcus lugdunensis* skin infections. *J Dermatol*. 2018;45:994–9.
10. Vandenesch F, Eykyn SJ, Etienne J, Lemozy J. Skin and post-surgical wound infections due to *Staphylococcus lugdunensis*. *Clin Microbiol Infect*. 1995;1(2):73–4.
11. Arias M, Tena D, Apellániz M, Asensio MP, Caballero P, Hernández C, et al. Skin and soft tissue infections caused by *Staphylococcus lugdunensis*: report of 20 cases. *Scand J Infect Dis*. 2010;42:879–84.
12. Fernández Urrusuno R (coord.). Grupo de Trabajo de la Guía. Guía de terapéutica antimicrobiana del Área Aljarafe, 3.a ed, Sevilla: Distrito Sanitario Aljarafe-Sevilla Norte y Hospital San Juan de Dios del Aljarafe; 2018, pp. 207-220. [Accessed 05 Mar 2019]. Available in: <http://www.juntadeandalucia.es/servicioandaluzdesalud/guiaterapeuticaaljarafe/guiaTerapeuticaAljarafe/>.
13. Lozano-Masdemont B, Gómez-Recuero-Muñoz L, Pulido-Pérez A. *Staphylococcus lugdunensis*: an emerging pathogen in skin and soft tissue infections. *Actas Dermosifiliogr*. 2015;106:769–70.
14. Argemi X, Prévost G, Riegel P, Keller D, Meyer N, Baldeyrou M, et al. VISLISI trial, a prospective clinical study allowing identification of a new metalloprotease and putative virulence factor from *Staphylococcus lugdunensis*. *Clin Microbiol Infect*. 2017;23:334.e1–8.
15. Argemi X, Hansmann Y, Riegel P, Prévost G. Is *Staphylococcus lugdunensis* significant in clinical samples? *J Clin Microbiol*. 2017;55:3167–74.
16. Heldt Manica LA, Cohen PR. *Staphylococcus lugdunensis* infections of the skin and soft tissue: a case series and review. *Dermatol Ther*. 2017;7:555–62.
17. Flendrie M, Vissers WHPM, Creemers MCW, de Jong EMGJ, van de Kerkhof PCM, van Riel PLCM. Dermatological conditions during TNF-alpha-blocking therapy in patients with rheumatoid arthritis: a prospective study. *Arthritis Res Ther*. 2005;7:R666–676.
18. Bernatsky S, Habel Y, Rahme E. Observational studies of infections in rheumatoid arthritis: a metaanalysis of tumor necrosis factor antagonists. *J Rheumatol*. 2010;37:928–31.
19. Patel R. Matrix-assisted laser desorption ionization-time of flight mass spectrometry in clinical microbiology. *Clin Infect Dis*. 2013;57:564–72.
20. Argemi X, Riegel P, Lavigne T, Lefebvre N, Grandpré N, Hansmann Y, et al. Implementation of matrix-assisted laser desorption ionization-time of flight mass spectrometry in routine clinical laboratories improves identification of coagulase-negative staphylococci and reveals the pathogenic role of *Staphylococcus lugdunensis*. *J Clin Microbiol*. 2015;53:2030–6.